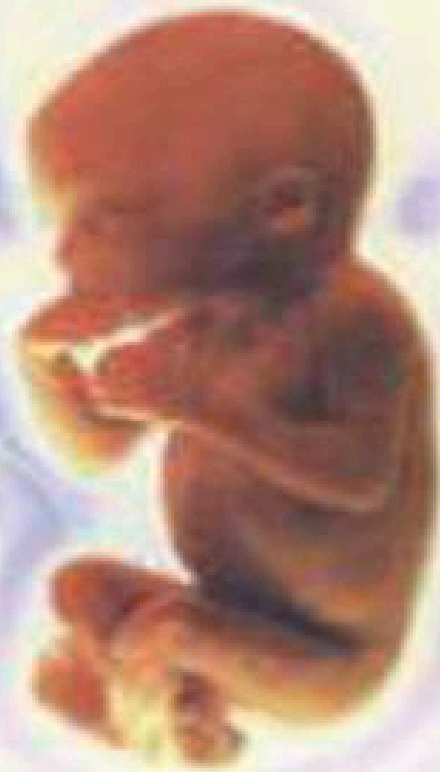

أطلس علم الأجنة

ATLAS OF EMBRYOLOGY



Prof. Dr. Mona Farid Abd El-Rahman

ACADEMIC BOOKSHOP

EGYPTIAN UNIVERSITIES CO.



ISO
9002

أطلس علم الأجنة

ATLAS OF EMBRYOLOGY

*Prof. Dr.
Mona Farid Abd El-Rahman*



The Publisher
THE ACADEMIC BOOKSHOP
Egyptian Joint-Stock Co.

2004

حقوق النشر

الطبعة الأولى ٢٠٠٤م - ١٤٢٤هـ

حقوق الطبع والنشر © جميع الحقوق محفوظة للناشر :

المكتبة الأكاديمية

شركة مساهمة مصرية
رأس المال المسدود والمدفوع ٩,٩٧٣,٨٠٠ جنيه مصري

١٢١ شارع التحرير - الدقى - الجيزة

القاهرة - جمهورية مصر العربية

تليفون : ٧٤٨٥٢٨٢ - ٣٣٦٨٢٨٨ (٢٠٢)

فاكس : ٧٤٩١٨٩٠ (٢٠٢)

لا يجوز استنساخ أى جزء من هذا الكتاب بأى طريقة
كانت إلا بعد الحصول على تصريح كتابى من الناشر .

مقدمة أطلس الأجنة

هذا الأطلس يشتمل على أهم الصور الموضحة لعلم الأجنة فى الحيوانات المختلفة والإنسان مما يجعله مناسباً لكليات العلوم والزراعة والطب والطب البيطرى وكليات التربية وغيرها، والكثير من هذه الصور عليه مصطلحات باللغة العربية مما يسهل على الدارسين من العرب فهم محتوى الرسم. ومعظم هذه الرسوم كبيرة الحجم واضحة التركيب، ومرتببة فى تسلسل حسب وضع الحيوان التصنيفى، وتطوره الجنينى مما يسهل فهم هذا العلم، خصوصاً وأن التركيب الجنينى يتغير مع الوقت، وفى مراحل الأولى يتغير فى كل ساعة، وقد حاولت أن أختار الصور المهمة والمراحل الأساسية فى الحيوانات المختلفة كى أحافظ على عدد الصفحات فى الحدود المعقولة، راجية أن يحوز هذا المجهود على رضا الدارسين، والله الموفق.

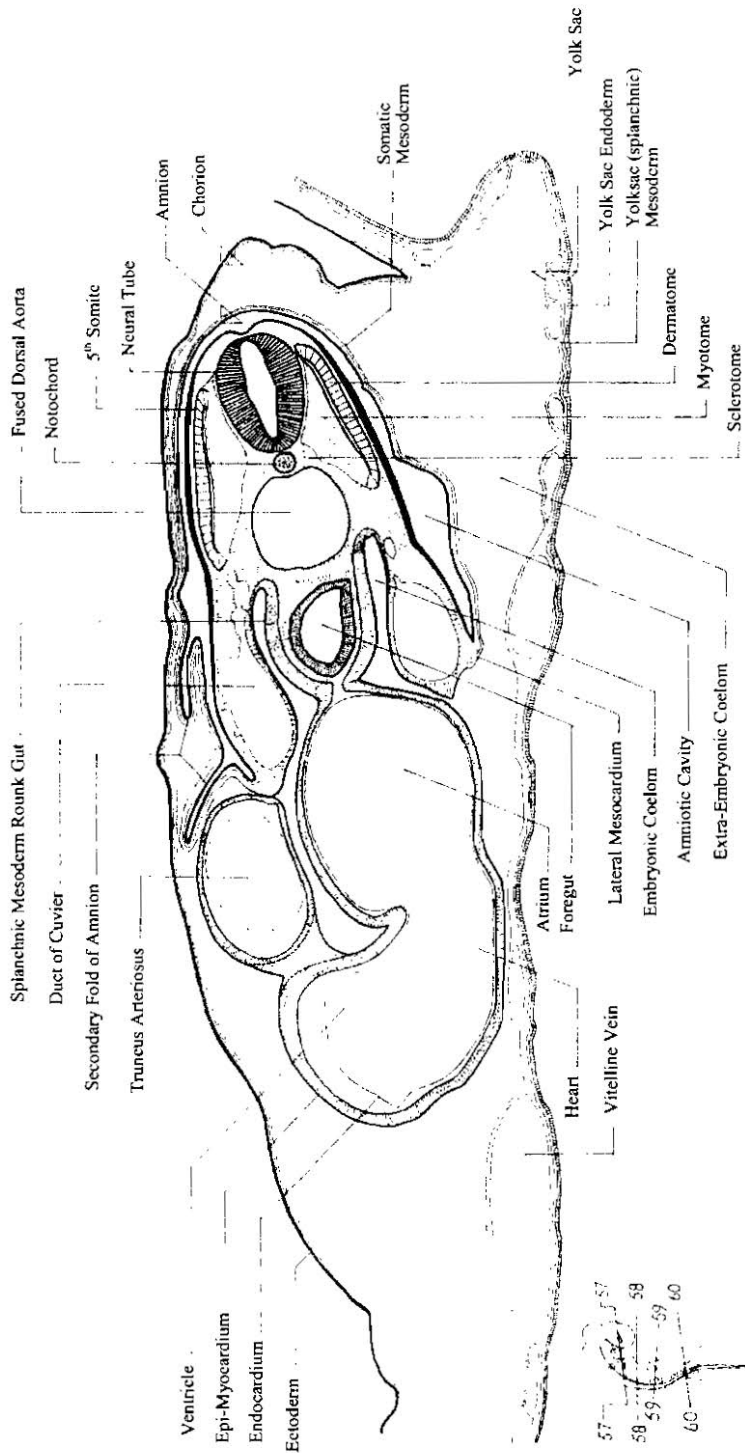
د. منى فريد عبد الرحمن

أستاذة علم الأجنة التجريبي

كلية العلوم - جامعة عين شمس

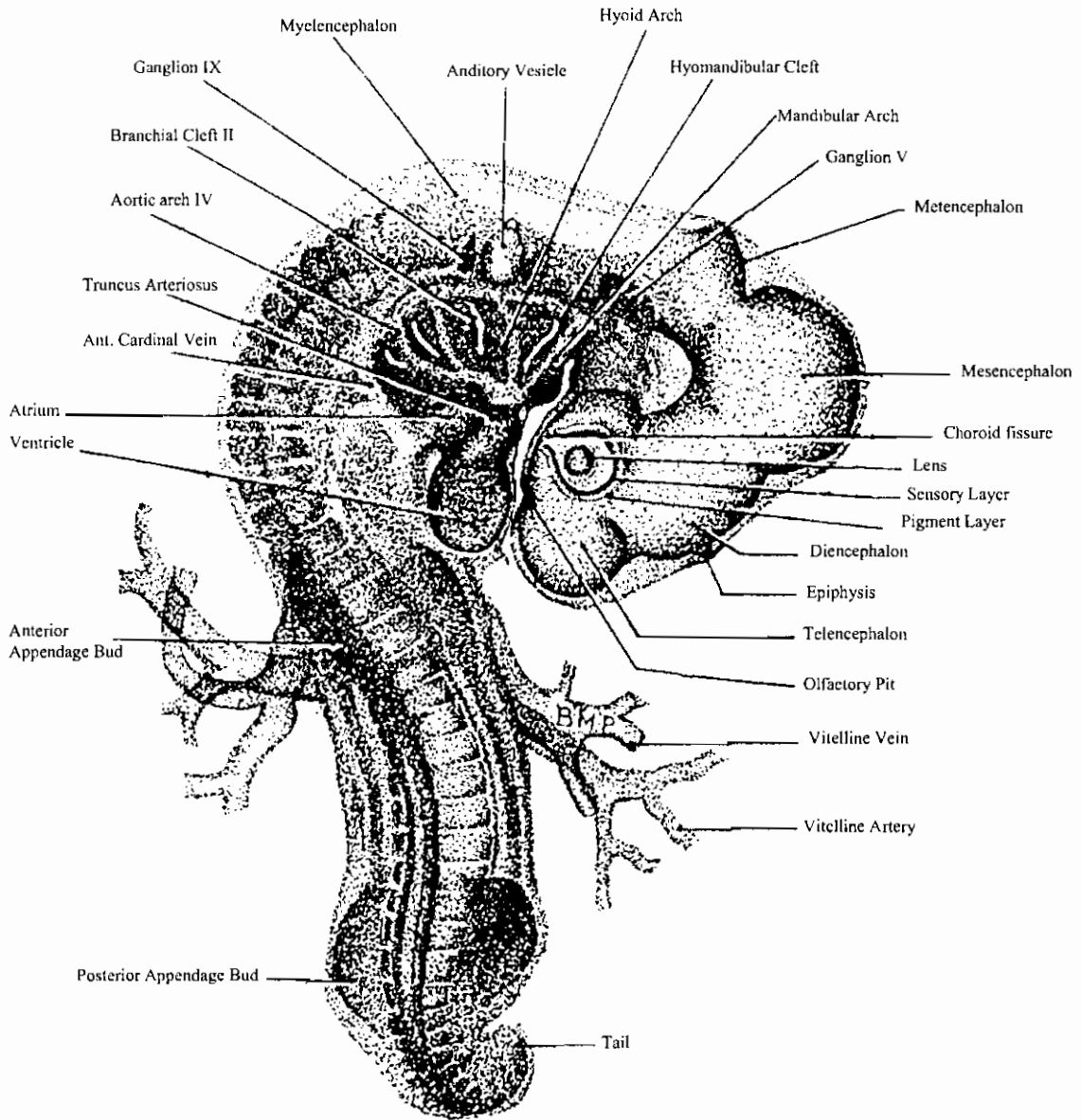
Contents

	Page
Different embryos of vertebrates	1
Migration of primordial germ cells	2
Female reproductive organs	3
Male reproductive organs	6
Gametogenesis	8
Fertilization	11
Cleavage in drosophila	16
Development of Ascidia	17
Development of Amphioxus	20
Development of fishes	29
Development of the frog	34
Development of chick embryo	81
Development of the mouse embryo	124
Early development of human embryos	128
The placenta	138
Organ formation	146
References	202



ق.ع. في منطقة القلب لجنين ككتوت في مرحلة ثلاثين قطعة ميزودرمية
 58-T. s. of the heart region of 30-somite stage chick embryo

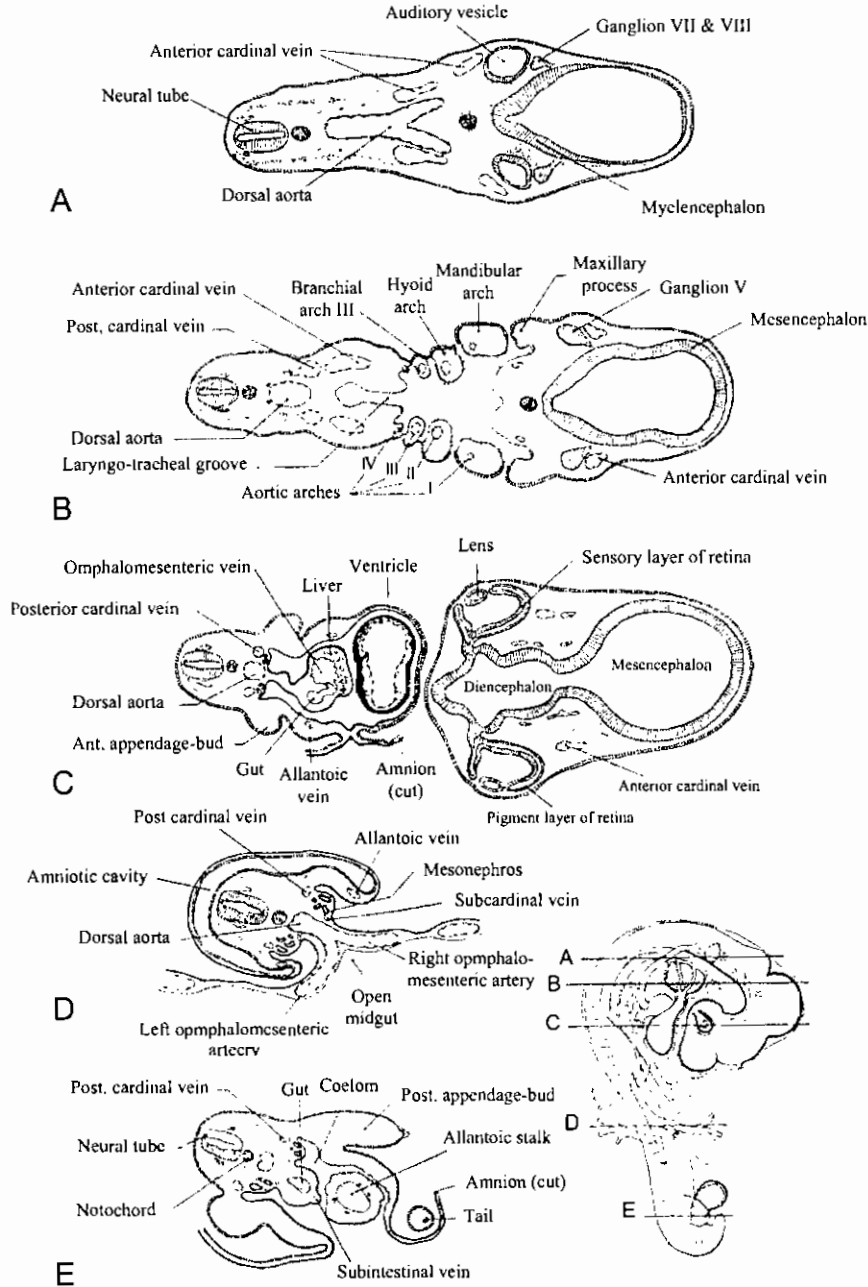




منظر ظهري لجنين كتكوت ذو ٣٦ قطعة ميزودرمية (في عمر ثلاثة أيام)

Dextrodorsal View (X 16) of entire chick embryo of 36 somites (about 3 days' incubation).

خمسة مقاطع عرضية في جنين ككتوت في عمر ثلاثة أيام
(في مناطق محددة على الشكل الجانبي)

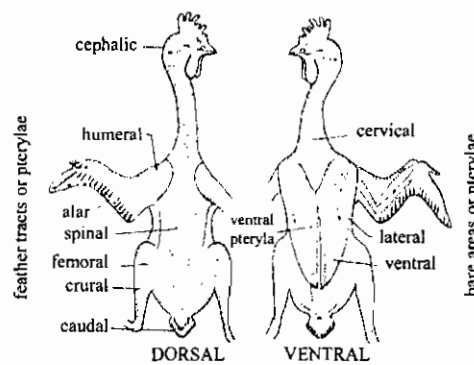
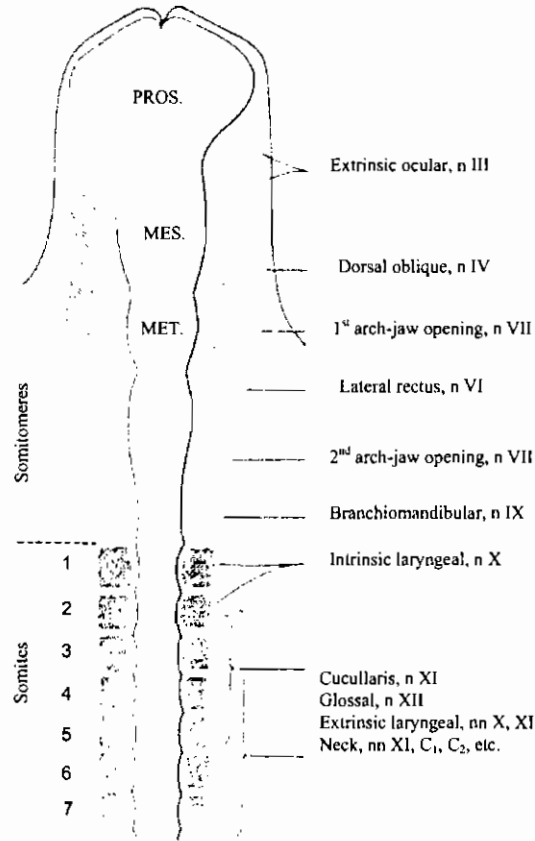


Diagrams of five representative transverse sections of a 3-day chick. The location of the sections is indicated on the small outline sketch of the entire embryo.

تكوين القطع العضلية والأعصاب في جنين الدجاج

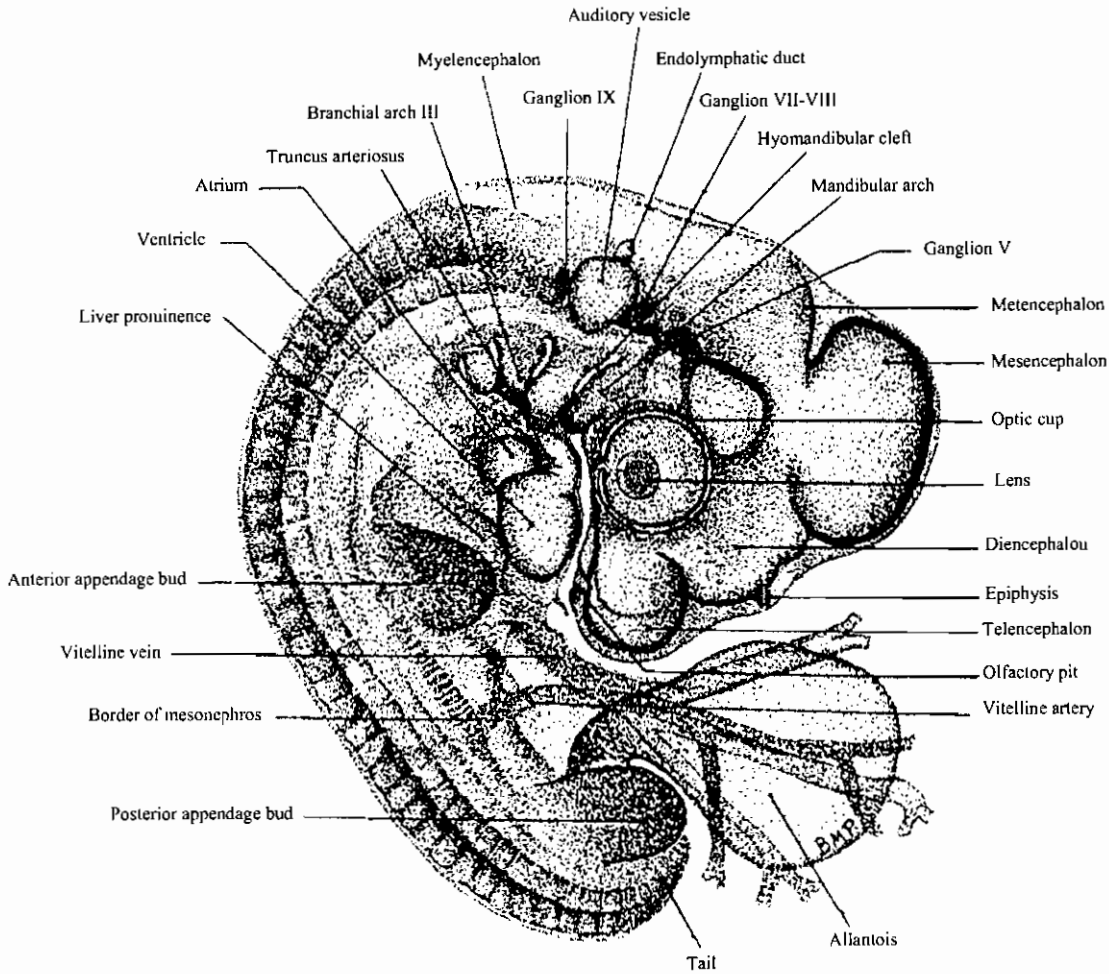
Derived Muscles and Nerve Supply

ORIGINS



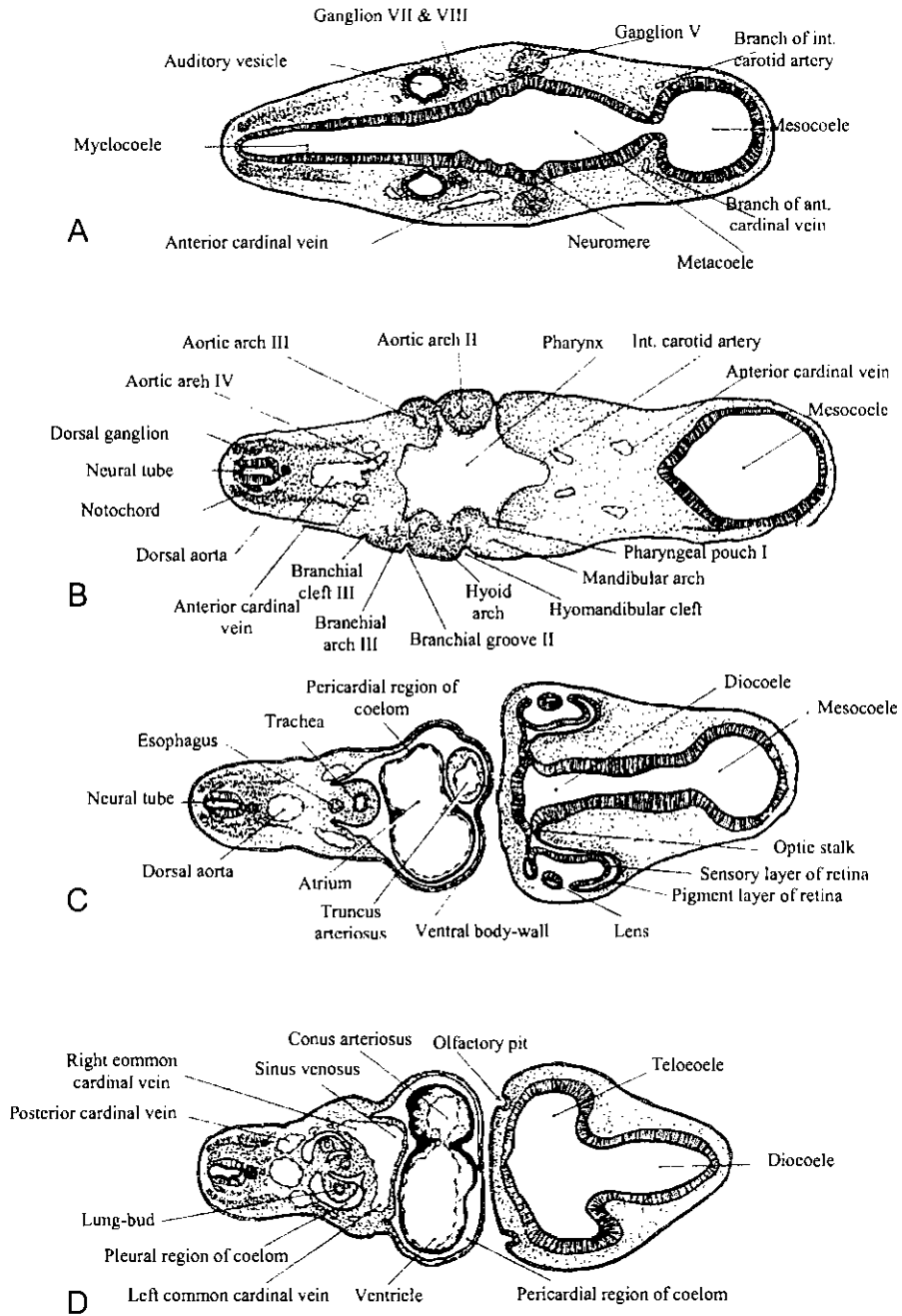
مناطق إنتشار الريش على جلد الدجاجة

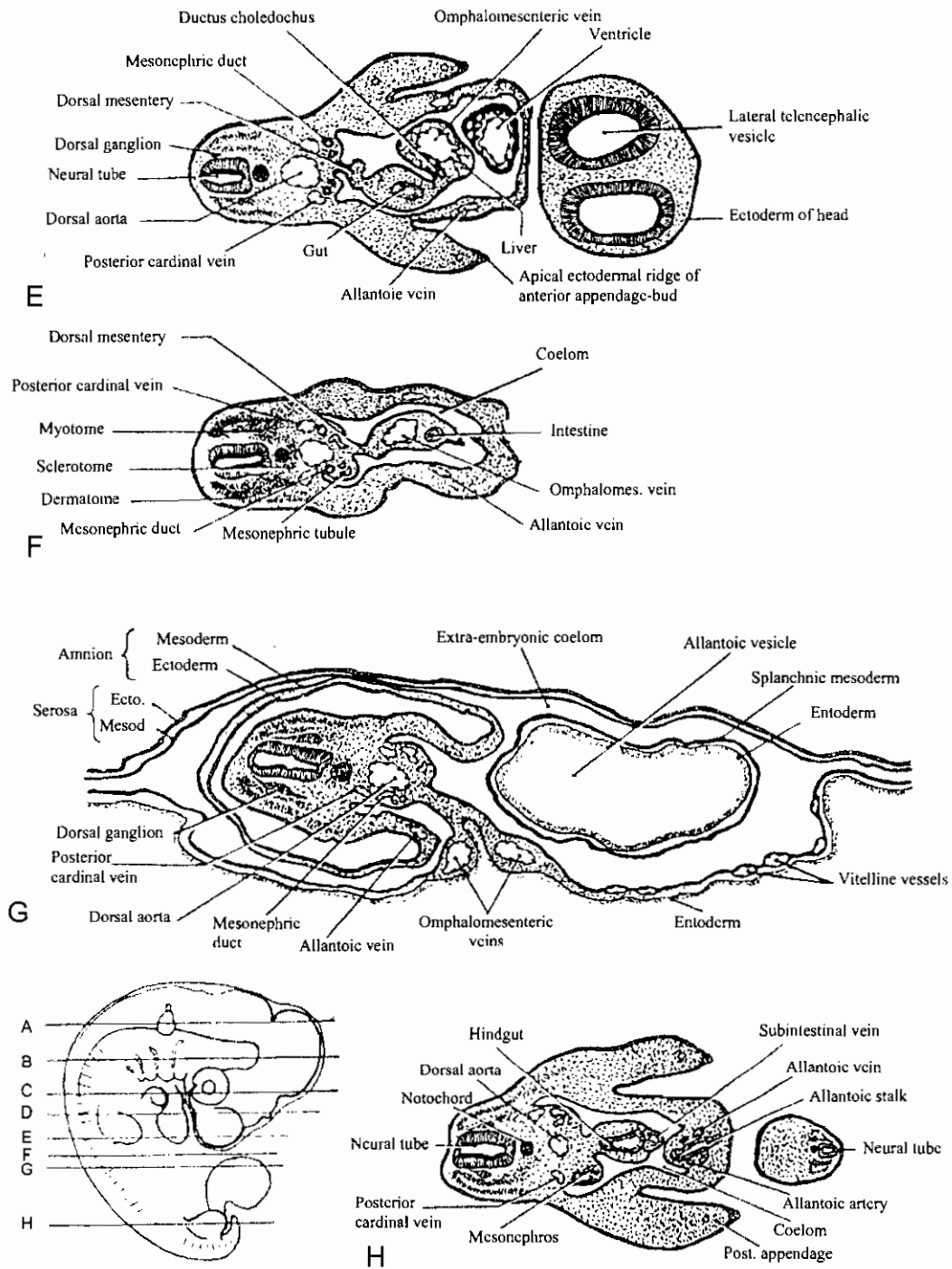
Feather tracts of the domestic fowl. (After Nitzsch.)



منظر ظهري لجنين كتكوت ذو ٤١ قطعة ميزودرمية (في عمر أربعة أيام)

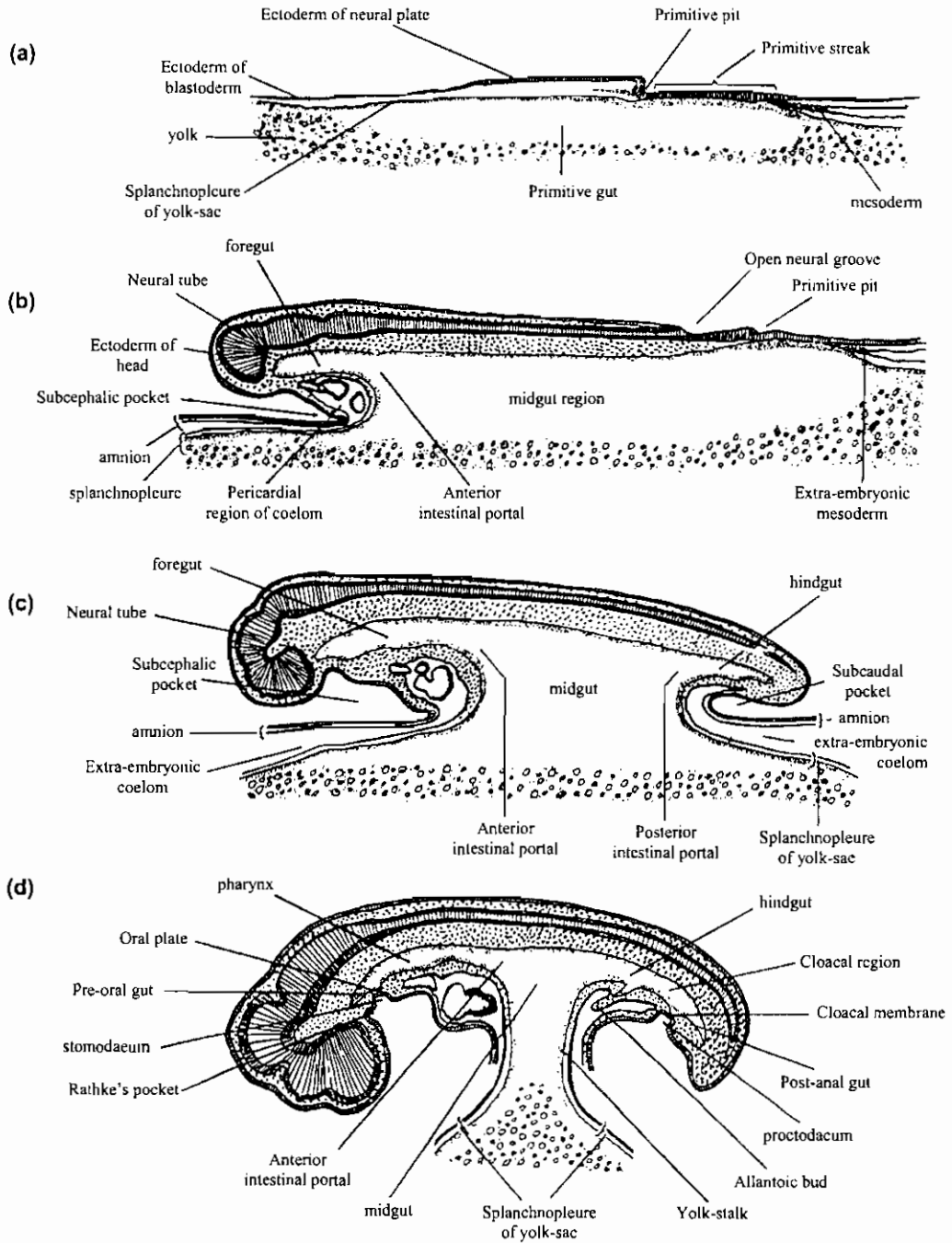
Dextral view (X16) of entire chick embryo of 41 somites (about 4 days' incubation). Stained and cleared preparation draw by transmitted light.





قطاعات عرضية في جنين كتكوت في عمر أربعة أيام في مناطق موضحة على الرسم الجانبي

Diagrams of transverse sections of a 4-day chick. The location of the sections is indicated on a small outline sketch of the entire embryo.

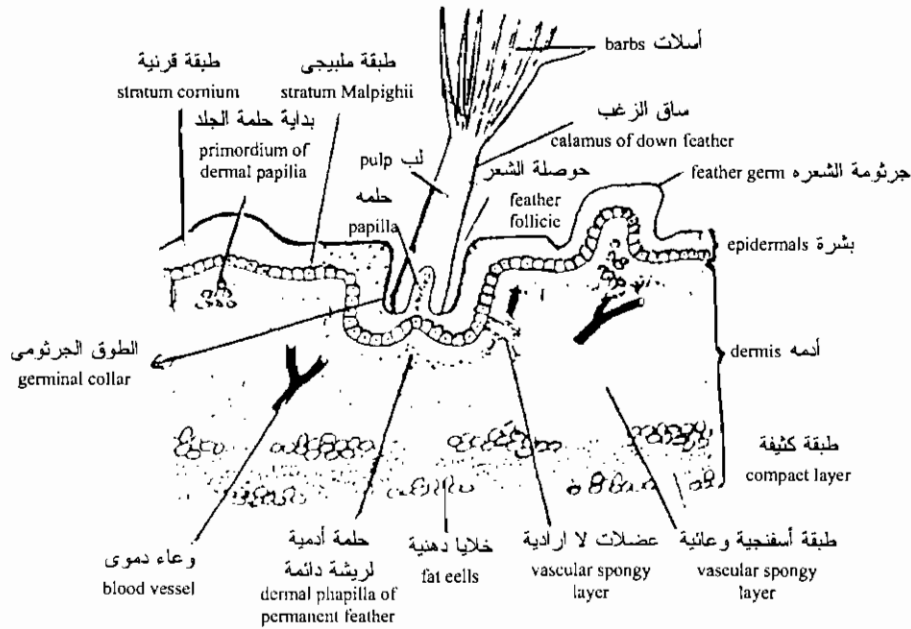
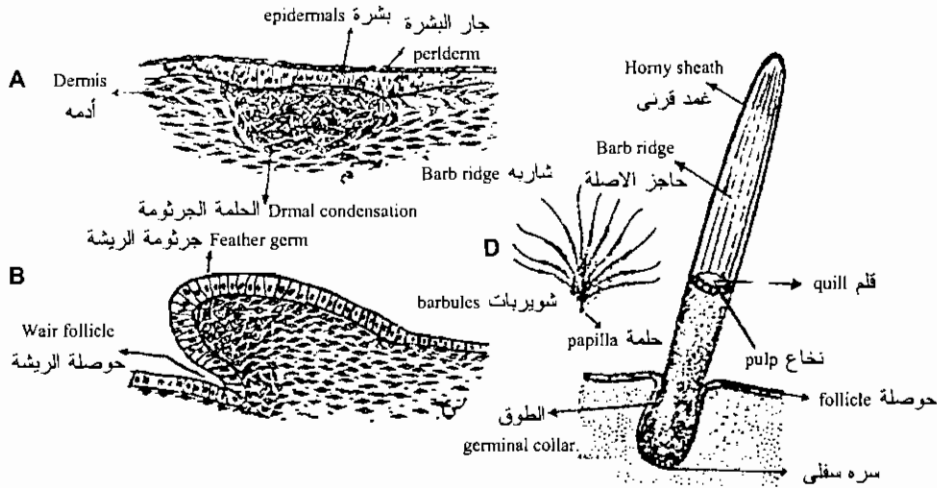


قطاعات طولية في أجنة دجاج في مراحل مختلفة توضح تكوين الأمعاء والجهاز العصبي والقلب

Later stages of development of the chick embryo: (a) primitive streak stage (end of first day); (b) foregut established (end of second day); (c) foregut, midgut, and hindgut established (about 3 days); (d) foregut and hindgut increased in length at expense of midgut; yolk stalk formed. (With permission from B. M. Patten, *Early Embryology of the Chick*. McGraw-Hill, New York, 1951.)

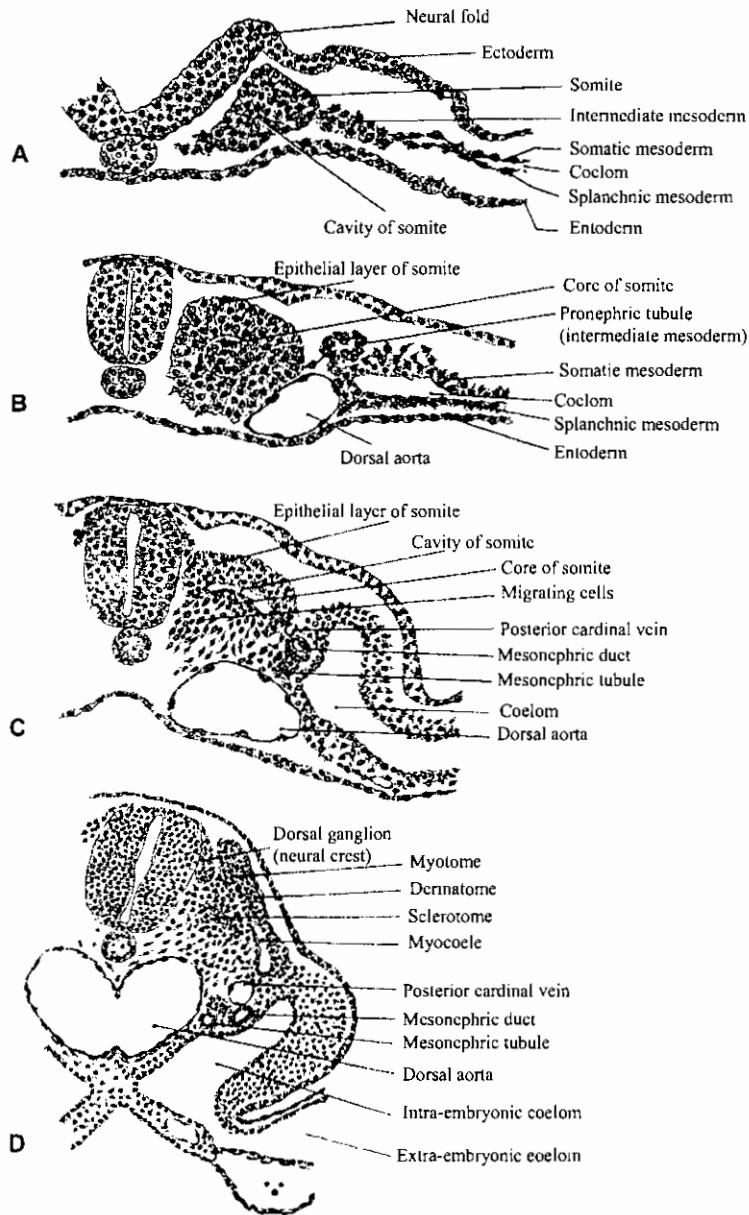
تكوين الريش في الطيور كما يظهر في قطاعات عمودية في الجلد

V.S. of Skin of a bird Showing the development of feathers



الحمامة: قطاع عمودي في الجلد

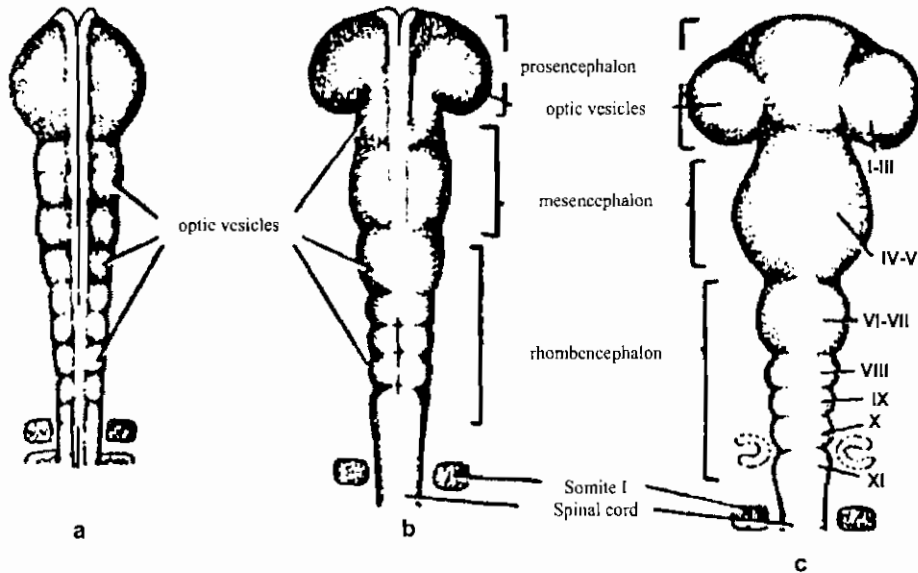
V.S. Skin of a bird



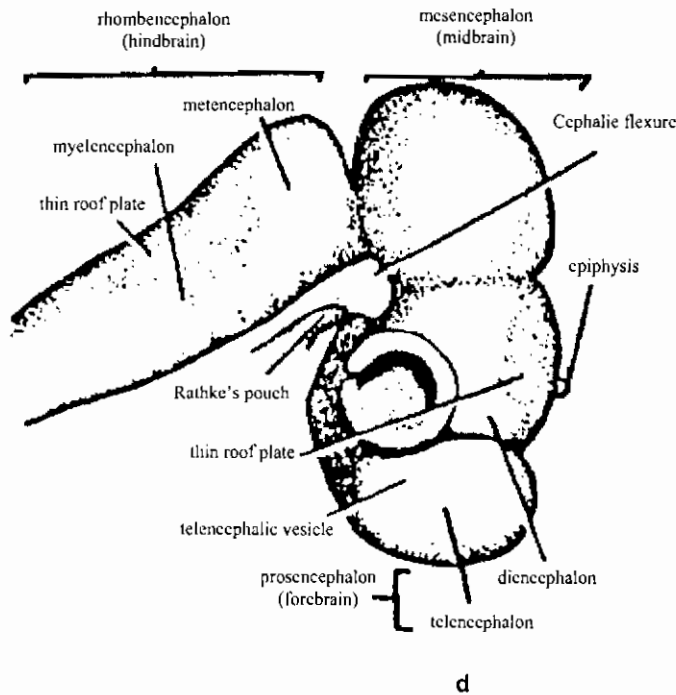
قطاعات عرضية في أجنة الدجاج توضح تميز القطع الميزودرمية إلى قطع عضلية وجلدية وعظمية

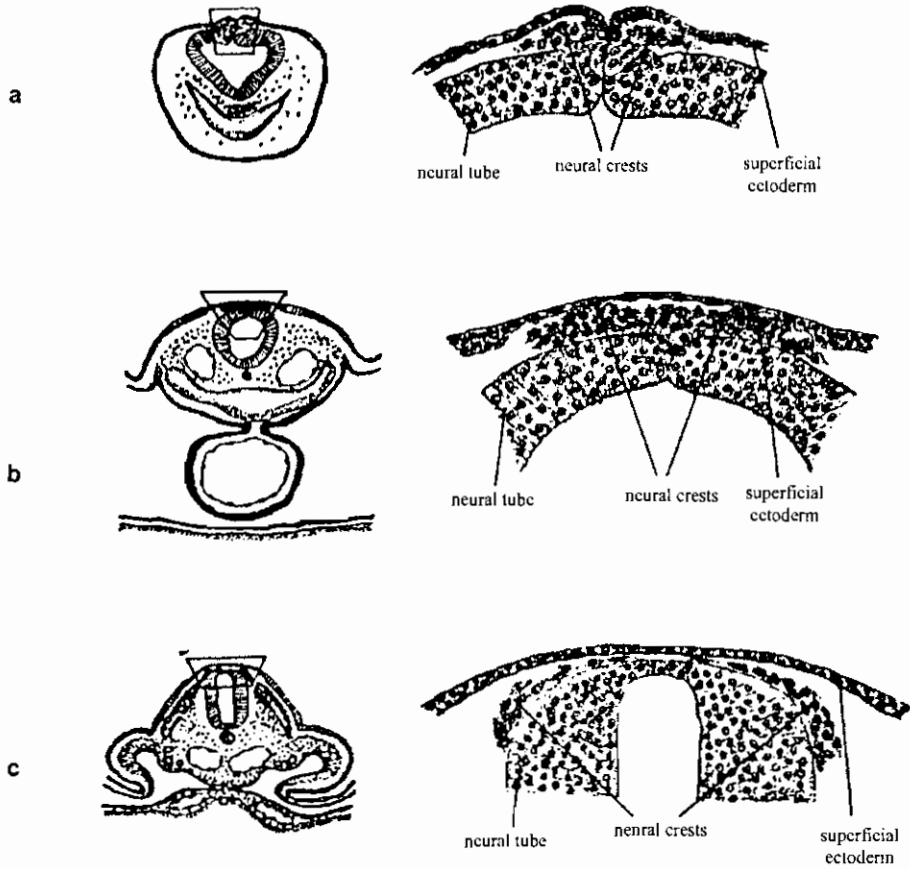
Drawings from transverse sections to show the differentiation of the somites. (A) Second somite of a 4-somite chick; (B) ninth somite of a 12-somite chick; (C) twentieth somite of a 30-somite chick; (D) seventeenth somite of a 33-somite chick.

تميز المخ في أجنة الدجاج



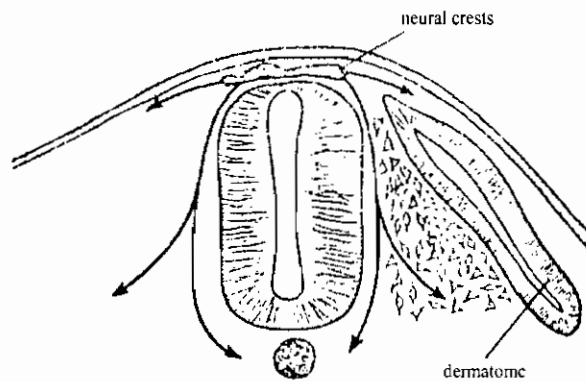
Early development of the brain of the chick. a Dorsal view at 7 pairs of somites. b Dorsal view at 11 pairs of somites. c Dorsal view at 14 pairs of somites. d Lateral view at about 75 to 80 hours of incubation. [a-d From O. E. Nelsen, "Comparative Embryology of the Vertebrates," McGraw-Hill, 1953.] e Ventral view of a chick embryo of 9 somites (29 to 30 hours) showing the development of the cephalic region and other anterior structures. [From B. M. Patten and B. M. Carlson, "Foundations of Embryology, 3rd ed., McGraw-Hill, 1974.]





قطاعات ع. في أجنة كتكوت تظهر تكوين العرف العصبي وهجرته

Transverse sections to show the origin of neural-crest cells. The location of the area drawn is indicated on the small sketch to the left of each drawing. a Anterior rhombencephalic region of 30-hour chick. b Posterior rhombencephalic region of 36-hour chick. c Middorsal region of cord in 55-hour chick. [From B. M. Patten and B. M. Carlson, "Foundations of Embryology," 3rd ed., McGraw-Hill, 1974.]



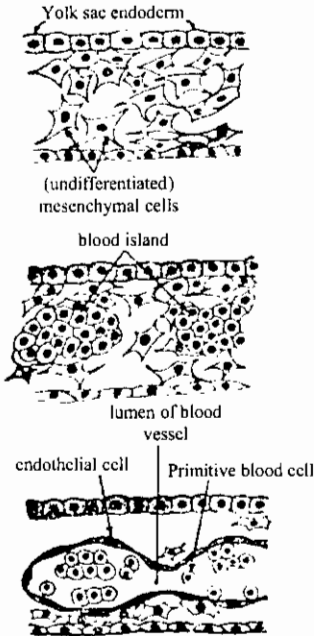
هجرة خلايا العرف العصبي

Neural crest. Direction in which labelled cells were found to migrate in the chick embryo.

(After Weston, 1963.)

تكوين الدم والأوعية الدموية

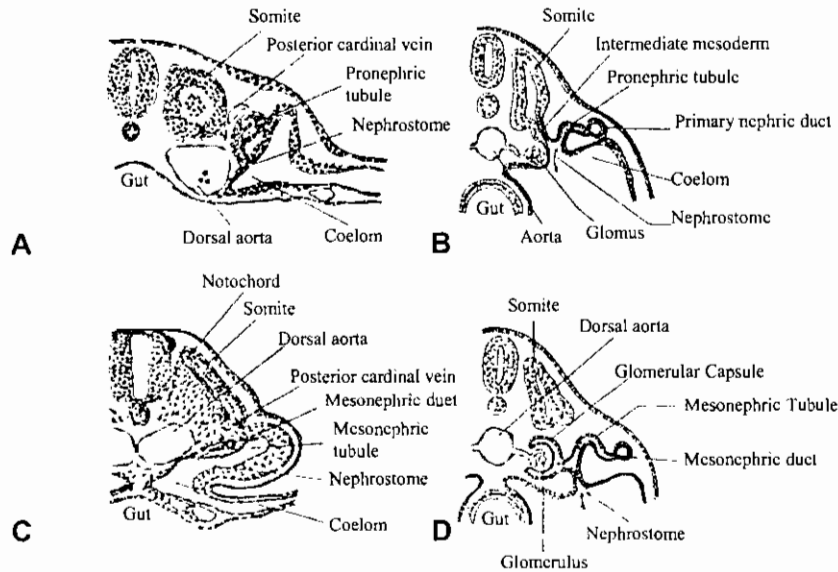
Successive stages of formation of blood vessels



(A) Undifferentiated mesenchymal cells in the wall of the yolk sac.

(B) Two blood islands are formed.

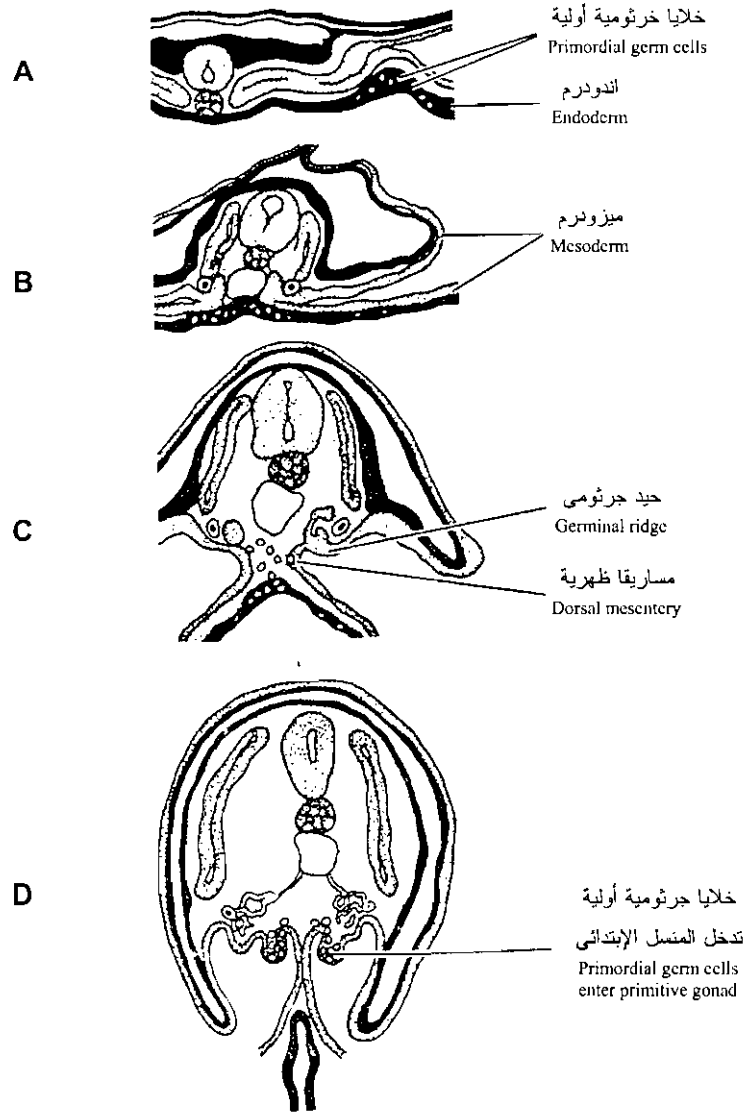
(C) An early capillary is formed. The undifferentiated mesenchymal cells form the primitive blood cells and the endothelial lining of the early capillary.



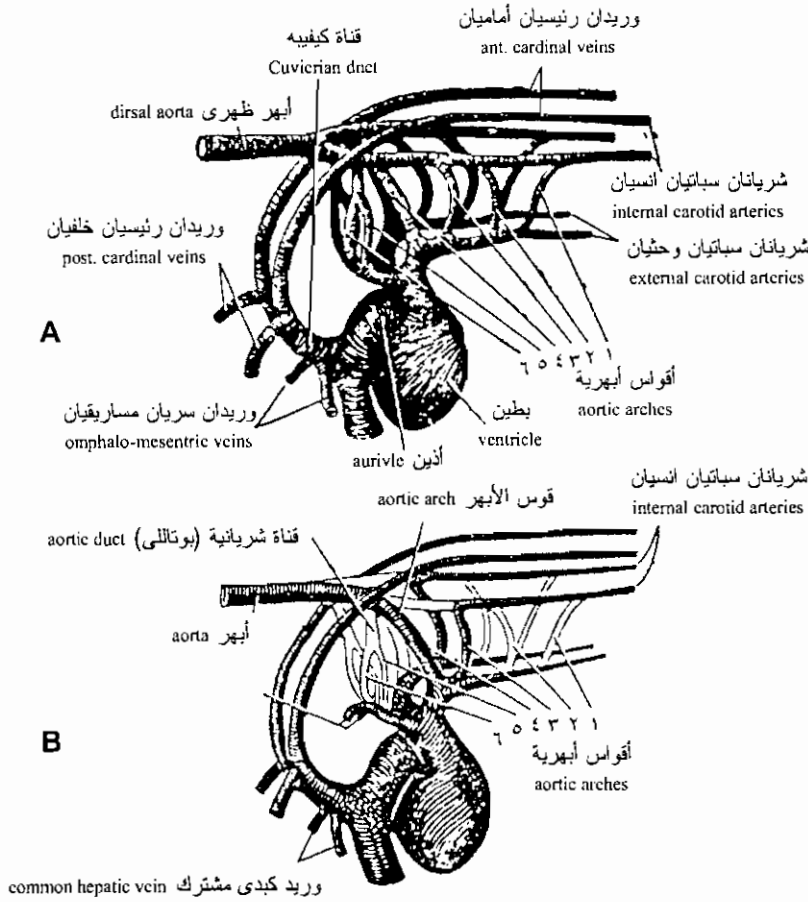
تكوين الأنبيبات والقناة الكلوية كما تظهر في مقاطع عرضية في أجنة الدجاج في مراحل مختلفة

Drawing to show nephric tubules. (A) Drawing from transverse section through twelfth somite of 16-somite chick to show pronephric tubule. (After Lillie.) (B) Schematic diagram of functional pronephric tubule. (After Wiedersheim.) (C) Drawing from transverse section through seventeenth somite of 30-somite chick to show primitive mesonephric tubule. (D) Schematic diagram of functional mesonephric tubule of primitive type. (After Wiedersheim.)

قطاعات عرضية في أجنة الدجاج توضح منشأ الخلايا الجرثومية الأولية



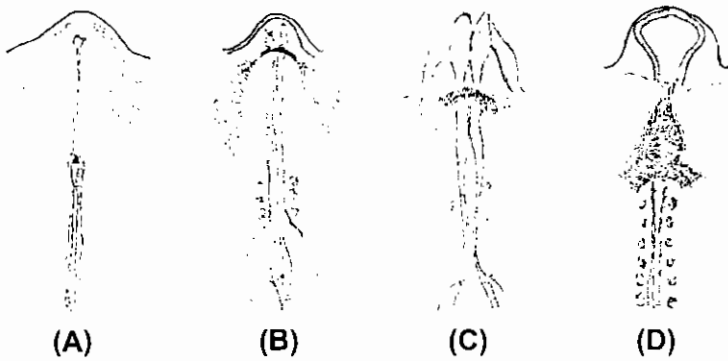
Schematic sections through midregion of young chick embryos illustrating the migratory pathway of primordial germ cells. A and B, Germ cells originate in extraembryonic endoderm and migrate by way of blood vessels to region of gonadal primordia. C, Cells travel through dorsal mesentery to site of primitive gonad, D.



الأقواس الأبهرية لجنين الدجاجة والتغيرات التي تحدث لها فيما بعد:

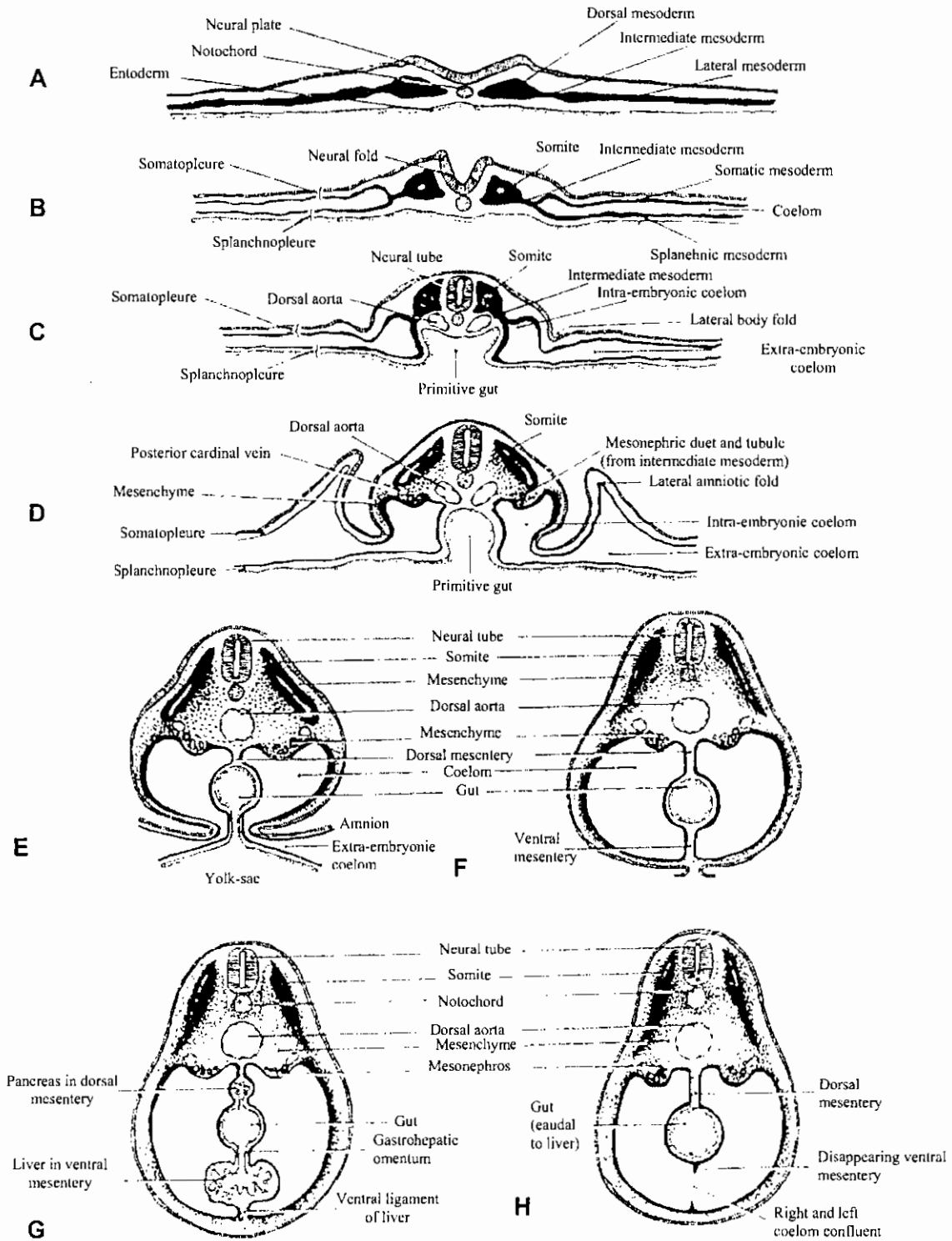
A) The aortic arches of the chick embryo.

B) The arteries of the adult chick.



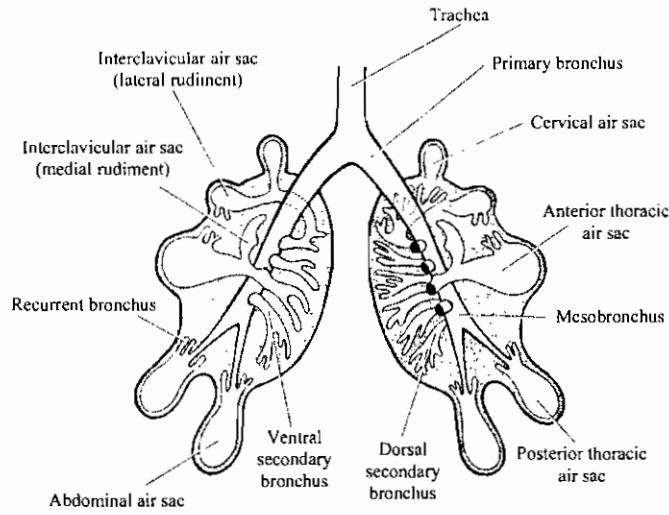
مناظر بطنية لأجنة دجاج في مراحل مختلفة من النمو توضح بداية تكوين القلب والتحام بداياته المزدوجة

Bilateral origin of the heart during early stages in the development of the chick embryo. A-D: successive positions occupied by heart-forming tissues at Hamburger – Hamilton stages 6-, 8-, 8+, and 10+, respectively. (Adapted from R. L. DeHaan, Acta Embryol. Et Morphol. Exptl., 6 : 26-38, 1963.)



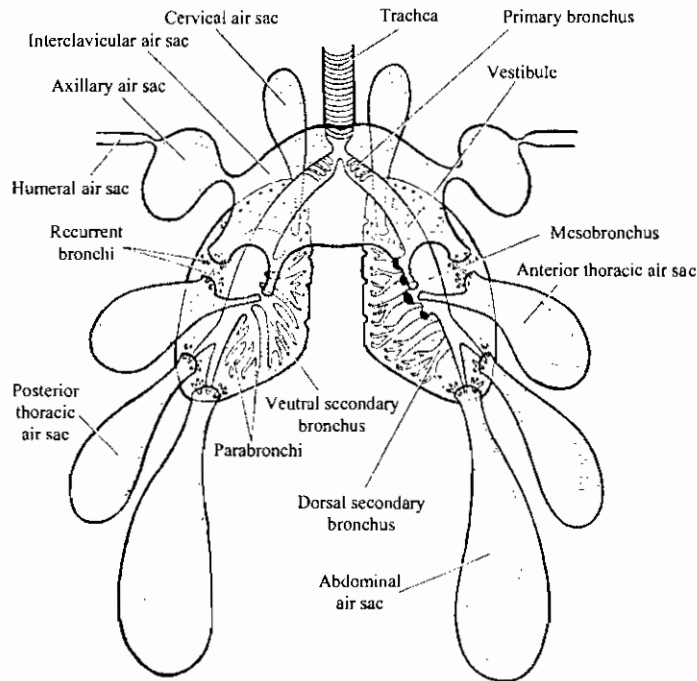
قطاعات عرضية في أجنة دجاج توضح تكوين السيلوم والمساريقا

Schematic diagrams of cross sections at various stages to show the establishment of the coelom and mesenteries.



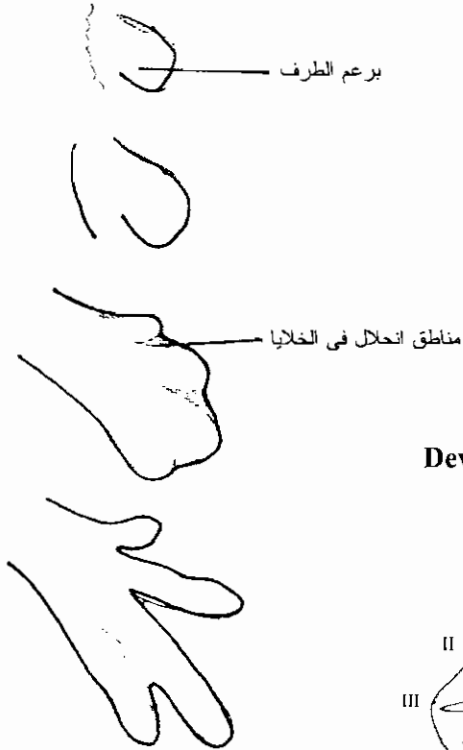تكوين الرئات والأكياس الهوائية في جنين الكتكوت في عمر عشرة أيام

Diagram of the lungs and air sac rudiments in the ten-day chick embryo



ثم في الدجاجة البالغة

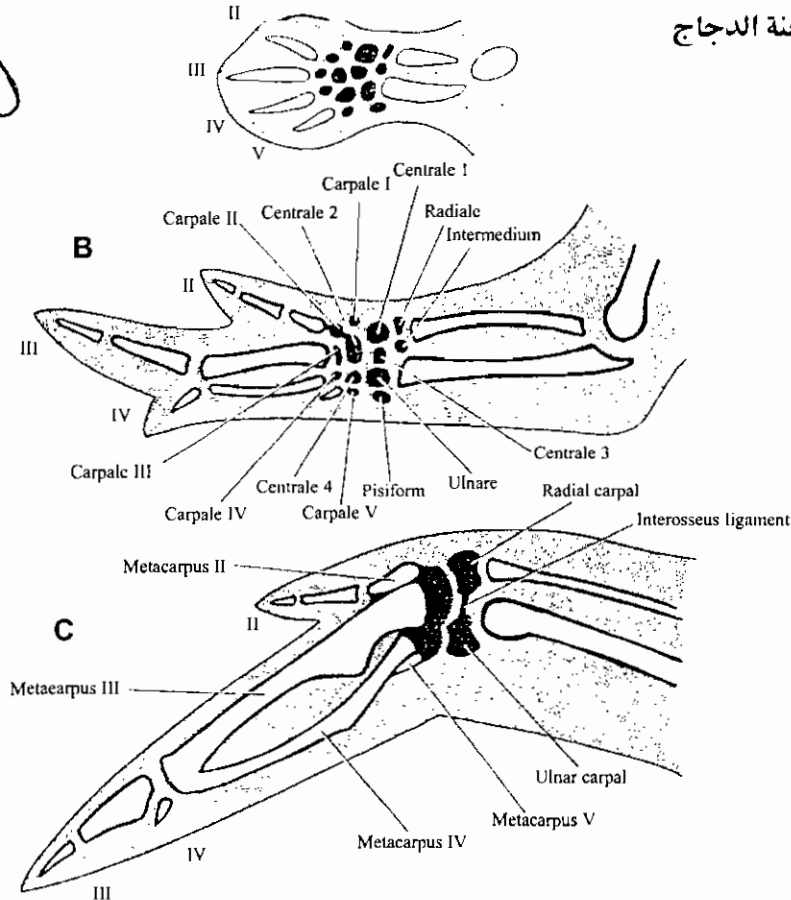
Diagram of the lungs and air sacs in the adult chicken



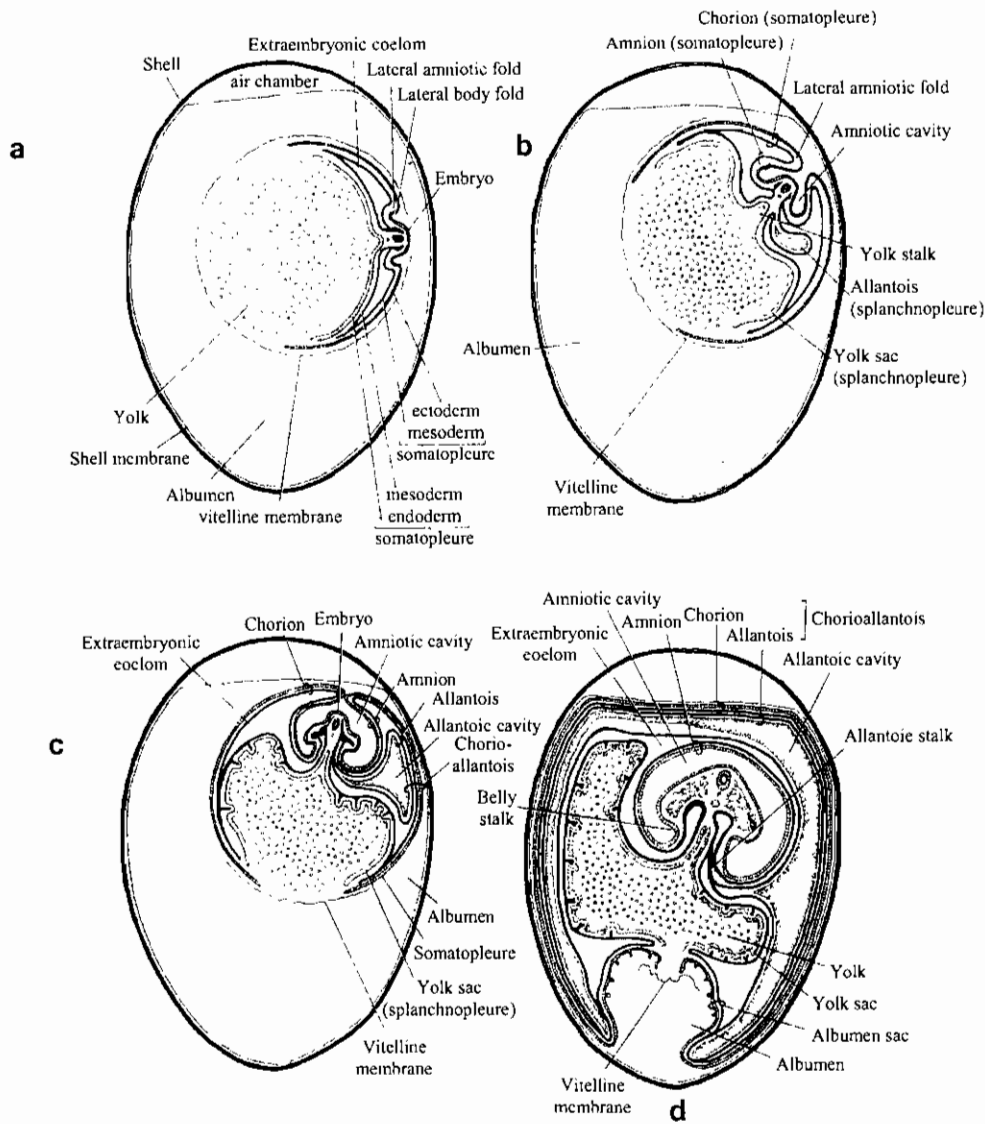
تكوين الطرف الخلفي لجنين الدجاج

Development of digits in the hindlimb of a chick embryo. The undergoing necrosis are shown by stippling.

تكوين الجناح في أجنة الدجاج



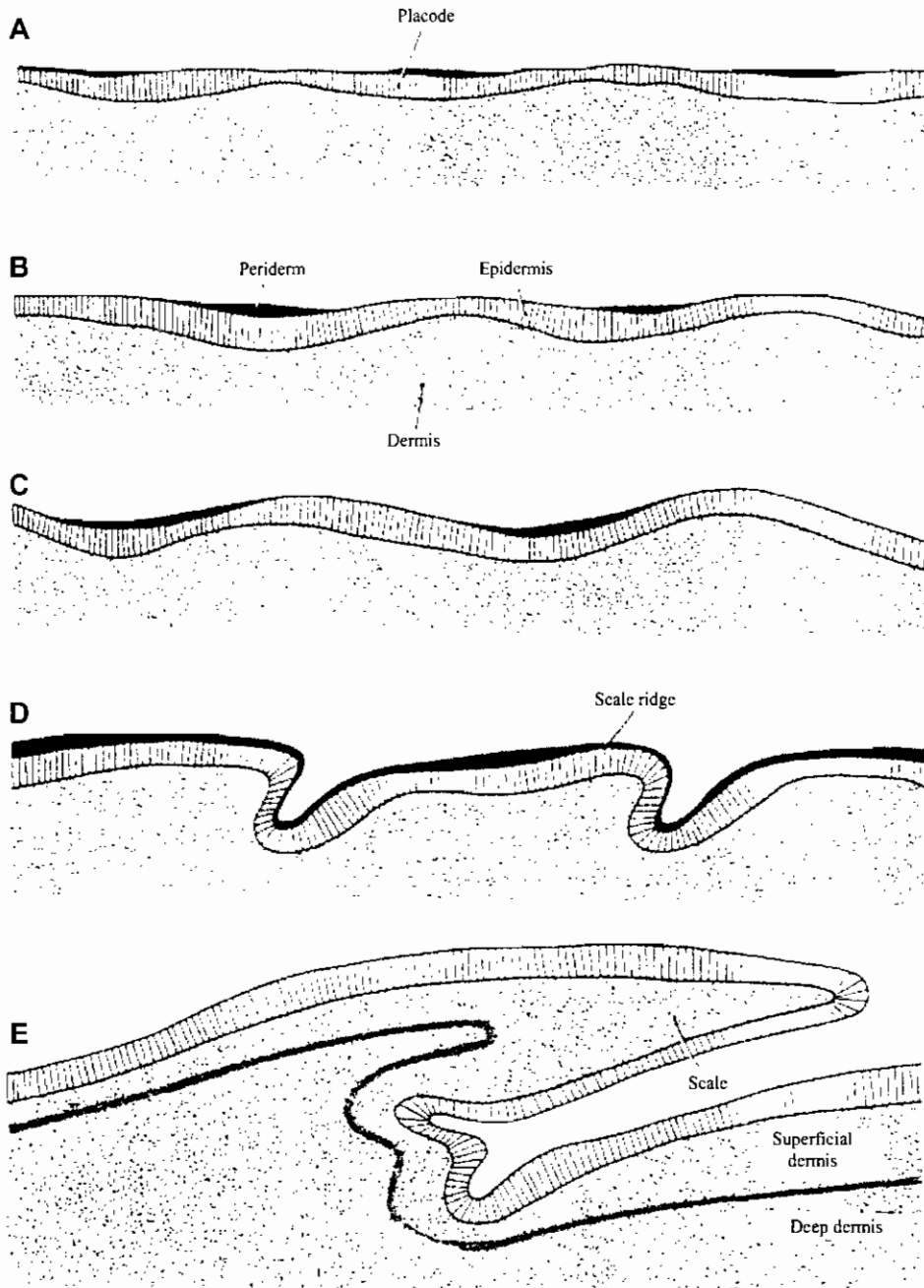
The development of the wing A. Six-day embryo, B. Eight-day embryo, C. Twelve-day embryo



قطاعات طولية في بيض الدجاجة تظهر تكوين الأغشية خارج الجنين، ويظهر فيها قطاعات عرضية في الجنين

Schematic diagrams to show the extraembryonic membranes of the chick. (After Duval.) The diagrams represent longitudinal sections through the entire egg. The body of the embryo, being oriented approximately at right angles to the long axis of the egg, is cut transversely. a, embryo of about 2 days incubation. b, embryo of about 3 days incubation. c, embryo of about 5 days incubation. d, embryo of about 14 days incubation. (From B. M. Patten, *Early Embryology of the Chick*. Copyright 1951 by McGraw-Hill Book Co. Copyright renewed 1957 by B. M. Patten. Used with permission of McGraw-Hill Book Co.)

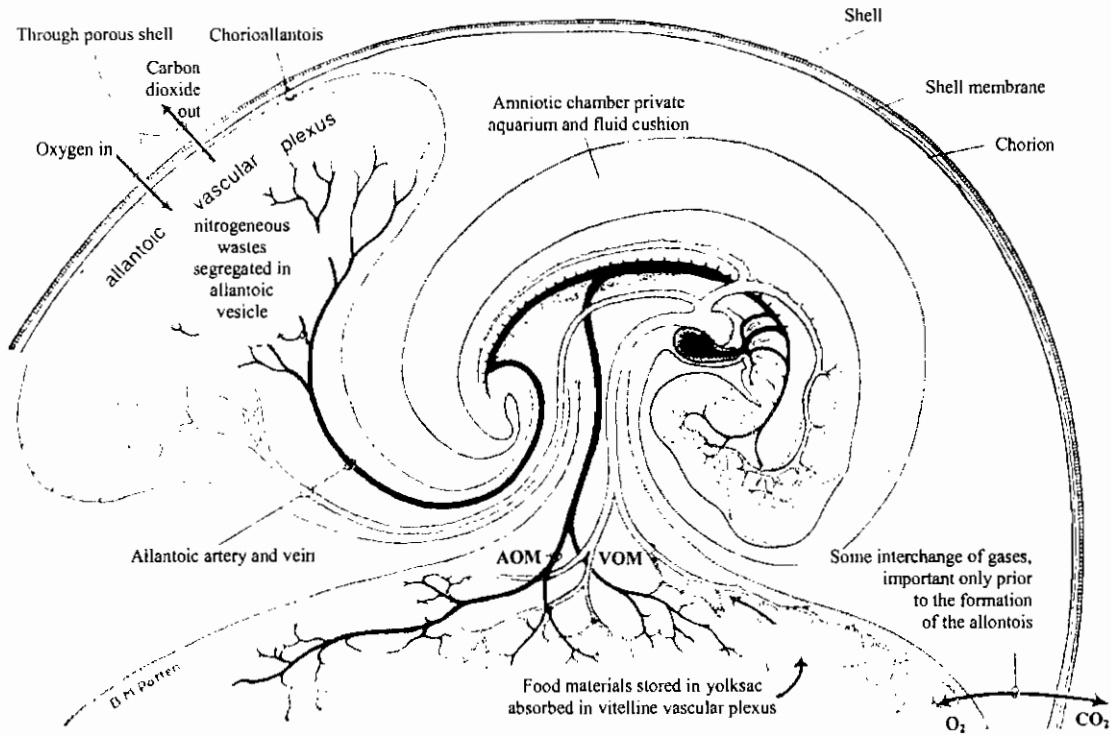
تكوين القشور القرنية الموجودة على أرجل الطيور



Stages in the formation of a scale in the bird. (A) Placode stage; (B) asymmetrical placode stage; (C) hump stage; (D) definitive scale ridge stage; (E) mature scale.

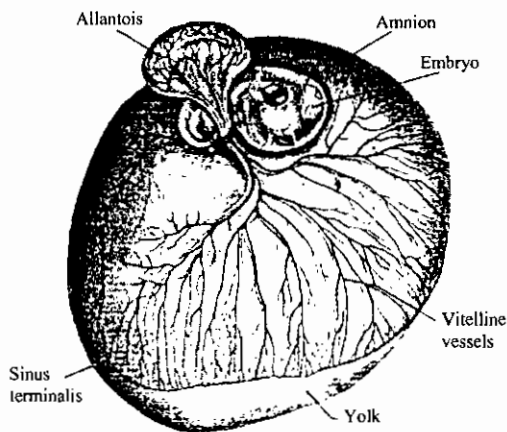
(After Sawyer, 1972, J. Exp. Zool., 181:367.)

منظر جانبي يوضح الدورة الدموية في جنين كتكوت في عمر أربعة أيام



Schematic diagram showing the arrangement of main circulatory channels in a 4-day chick embryo. The sites of some of the extraembryonic interchanges important in its physiology are indicated by the labeling. The vessels within the embryo carry food and oxygen to all its growing tissues, and relieve them of the waste products incident to their metabolism. Abbreviations: AOM, omphalomesenteric (vitelline) artery; VOM, omphalomesenteric (vitelline) vein. [From B. M. Patten, *The first heart beats and the beginning of embryonic circulation*. American Scientist 39:225 (1951). Used with permission of American Scientist.]

منظر سطحي لجنين كتكوت في عمر خمسة أيام ونصف يظهر الأغشية الجنينية




Chick of about 5 1/2 days' incubation taken out of the shell with yolk intact. (Modified from Kerr.) The albumen and the serosa have been removed to expose the embryo lying within the amnion. The allantois has been displaced upward in order to show the relations of the allantoic stalk. Compare this figure with figure 11-1, C, which shows schematically the relations of the membranes in a section through an embryo of similar age.

مراحل في تكوين جنين الكنكوت


Stages in Development of the Chick Embryo (From V. Hamburger and H.L. Hamilton, 1951, J. Morph. 88:49-92.




Stage 2
6-7 hrs



Stage 5
19-22 hrs



Stage 8
26-29 hrs




Stage 10
33-38 hrs



Stage 12
45-47 hrs



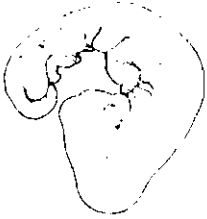Stage 15
50-55 hrs



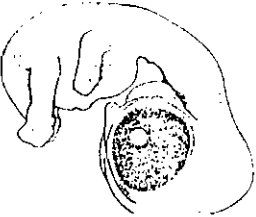
Stage 18
65-67 hrs



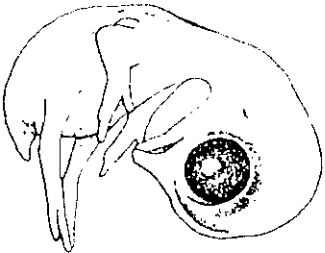
Stage 20
70-72 hrs



Stage 24
4 days



Stage 30
6 1/2 days

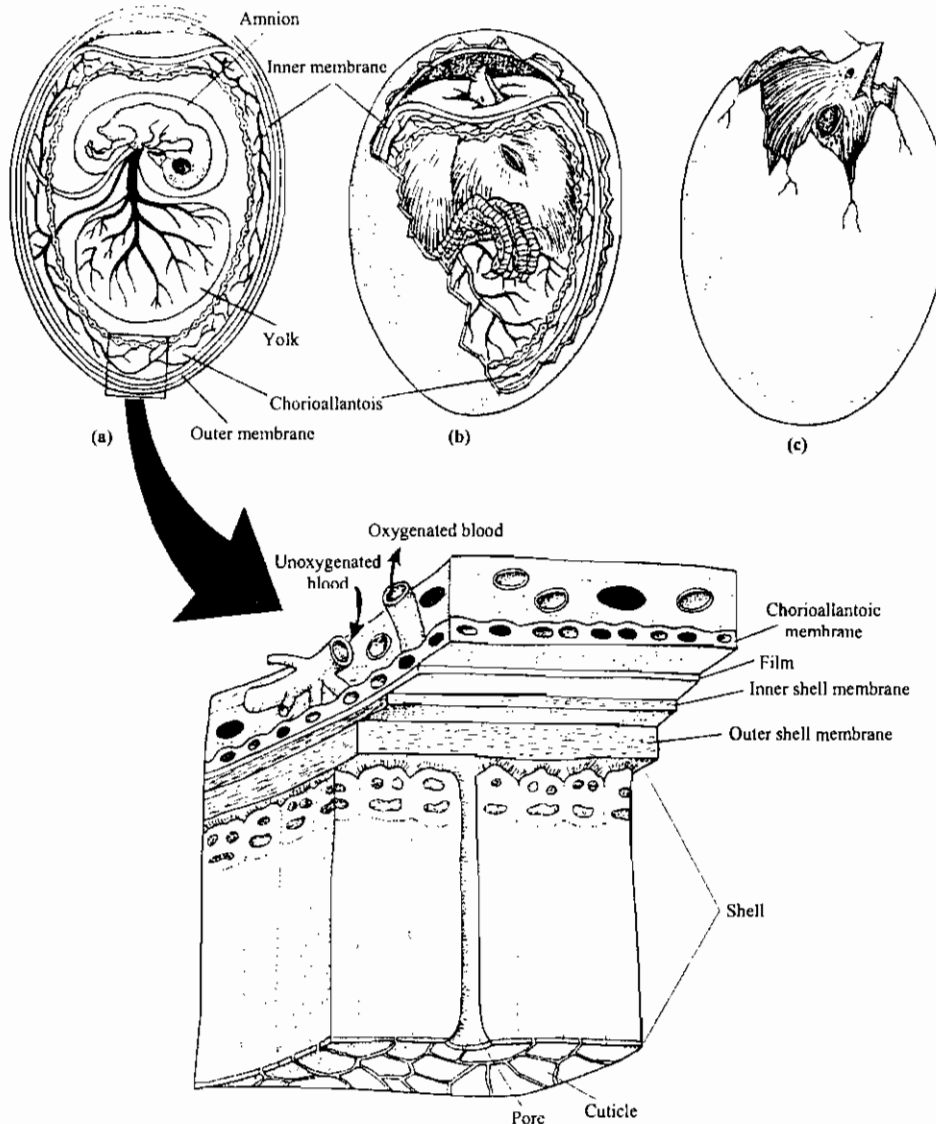


Stage 35
8-9 days



Stage 39
13 days

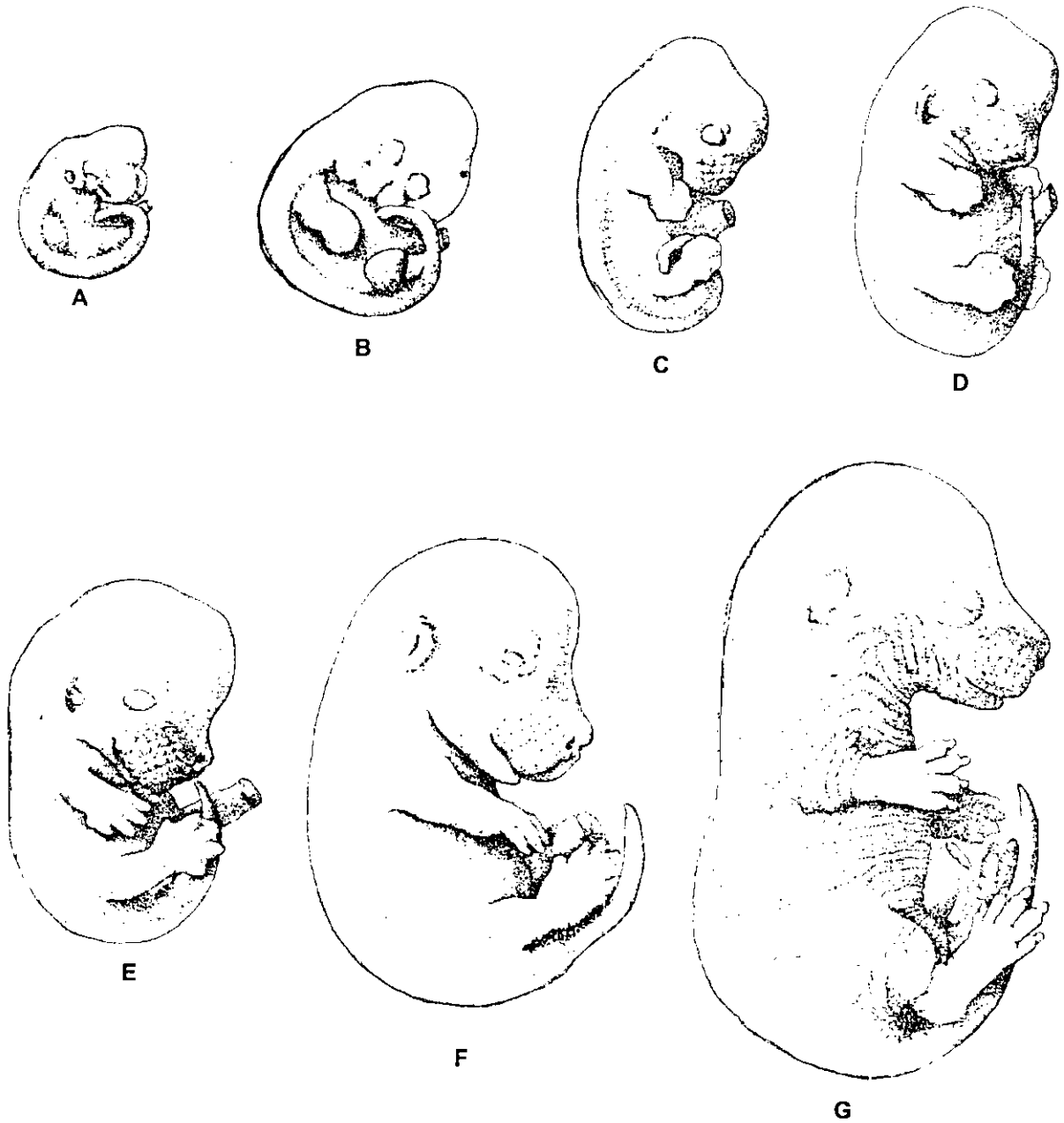
كيفية الفقس في جنين الدجاج والأغشية الخارجية التي يتنفس خلالها



Respiration in the chicken embryo. (a) While the chick embryo is enclosed in its shell, it respire through this porous shell. The chorioallantois carries blood to the inner surface of the shell to exchange gases at this interface. The shell proper is made up of calcite crystals pierced by tiny pores. Inner and outer shell membranes separate the shell from the vascularized chorioallantois. The chick embryo meets all its respiratory needs, up to day 19 of incubation, as air passes through the porous shell and exchanges gases with blood in the

chorioallantois. (b) On day 19, the embryo pokes its beak through the inner shell membrane into the air space between both membranes. Its lungs inflate, and the chick breathes air in addition to continued respiration via the chorioallantois. (c) Six hours later, the chick pecks through the shell proper, a process termed *pipping*, to breathe atmospheric air directly. Thereafter, chorioallantoic respiration declines and the chick further cracks the shell and soon steps out.

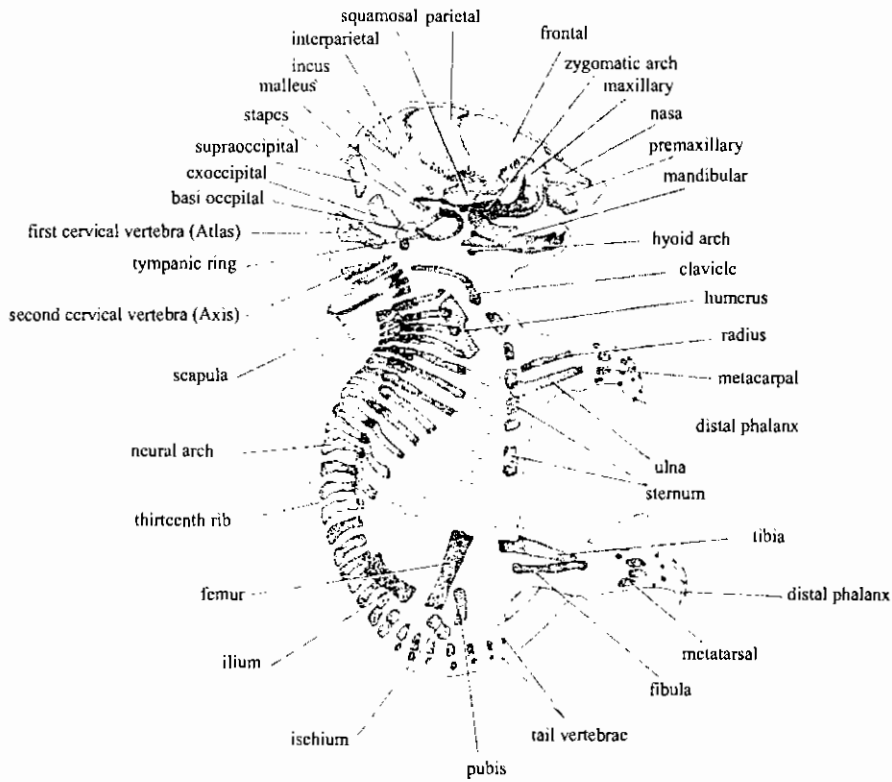
الشكل الخارجى لجنين فأر من عمر عشرة حتى ستة عشر يوماً



Diagrams showing development of mouse embryo from 10 ½ to 16 ½ Days

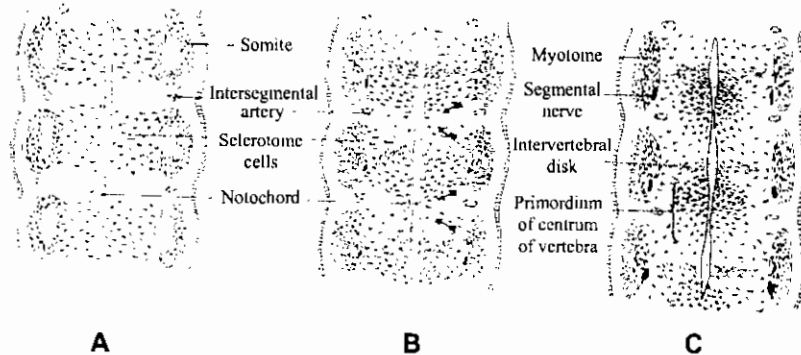
From R. Rugh. Vertebrate Embryology. 1964. Harcourt, Brace and World, New York.

هيكل جنين فأر في اليوم الثامن عشر من الحمل
Skeletal System of Mouse at 18 g.d.



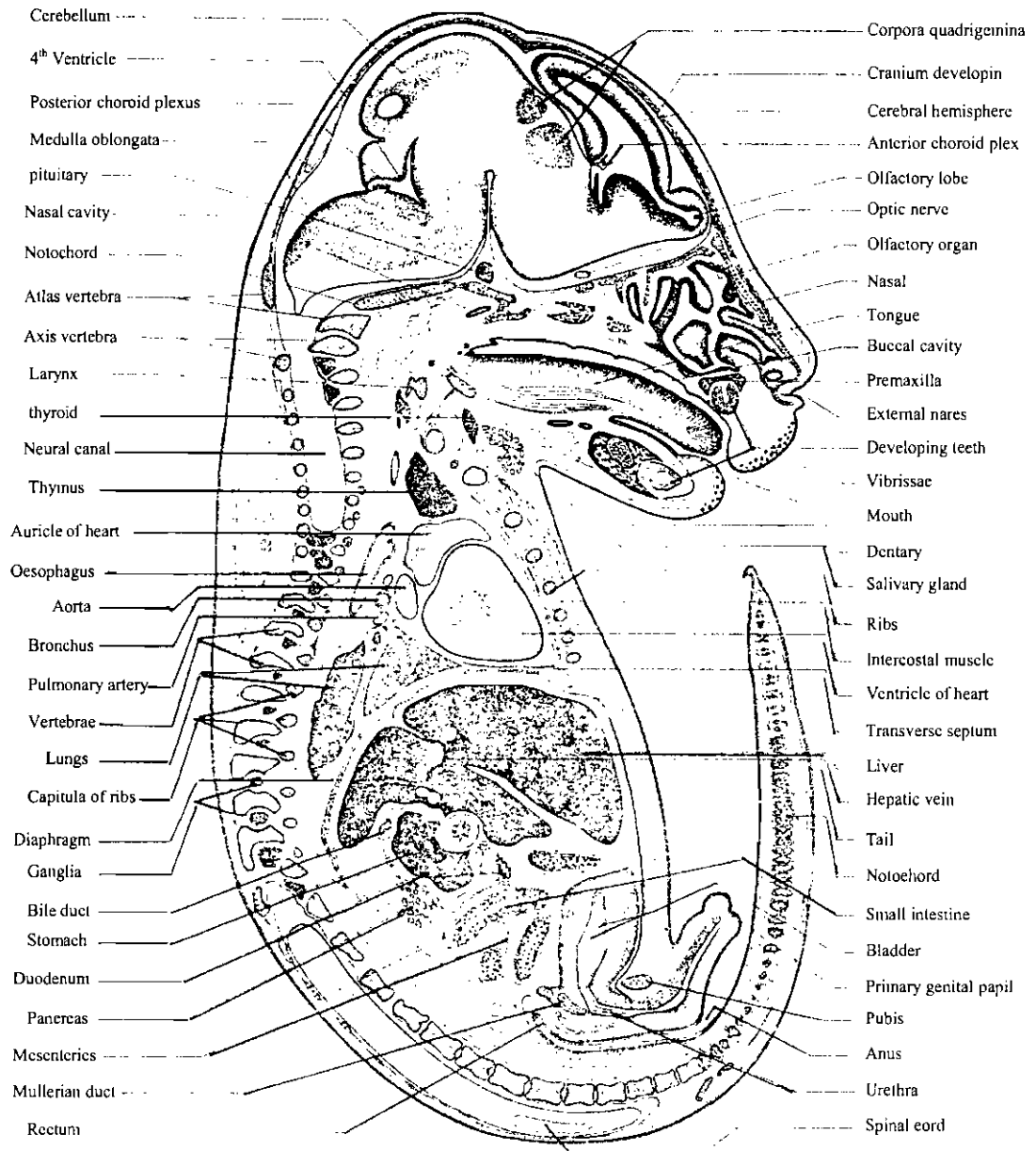
تكوين الفقرات وتحركها بالنسبة للقطع العضلية المجاورة

Semischematic coronal sections through dorsal region of young embryos to show how vertebrae become intermyotomal in position. Note that the primordium of a centrum is formed by cells originating from sclerotomes of both adjacent pairs of somites.



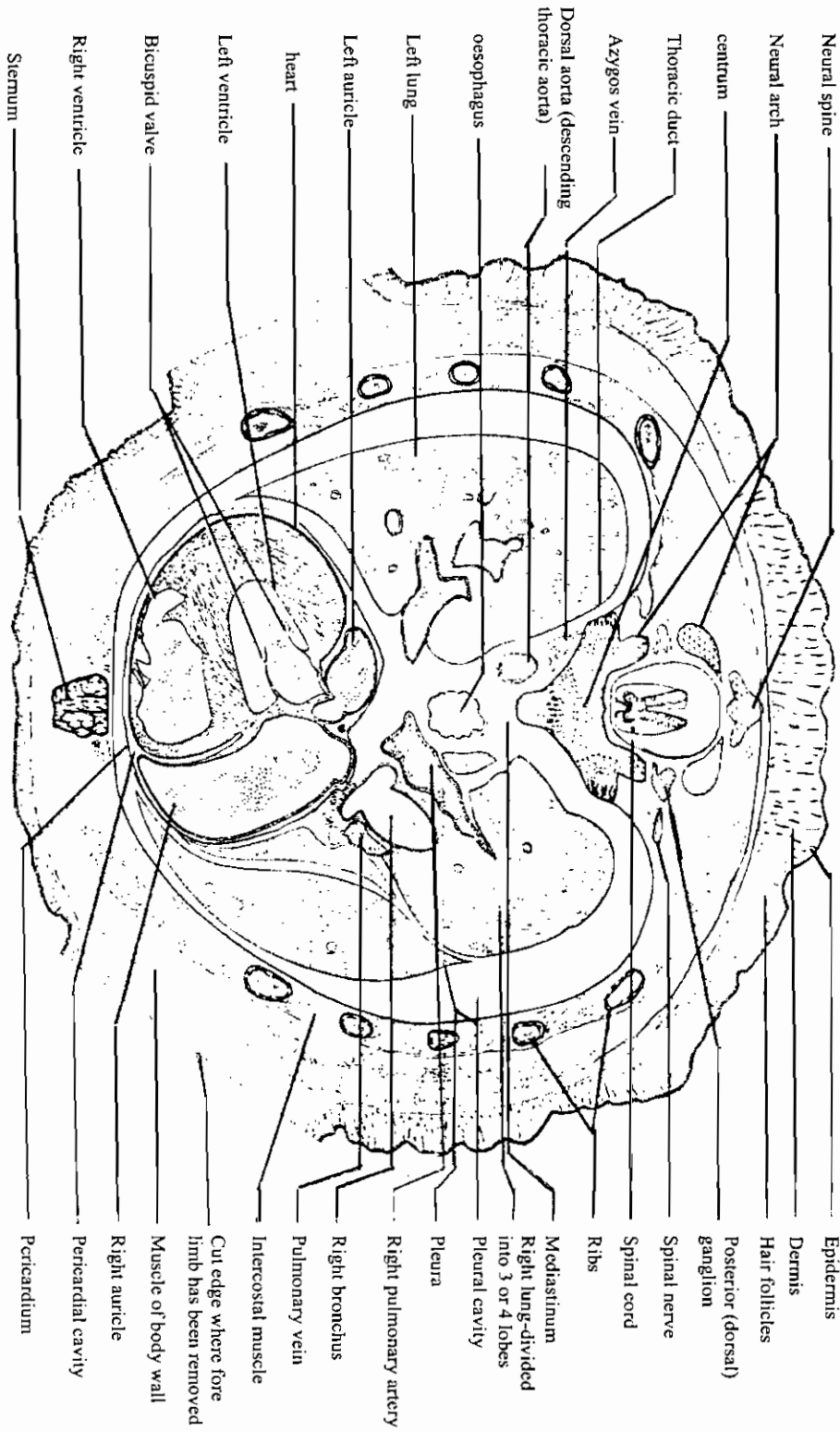
ق. ط. في جنين فأر في اليوم العاشر من الحمل

Mouse embryo, 10 days, L.S. mag. 12X



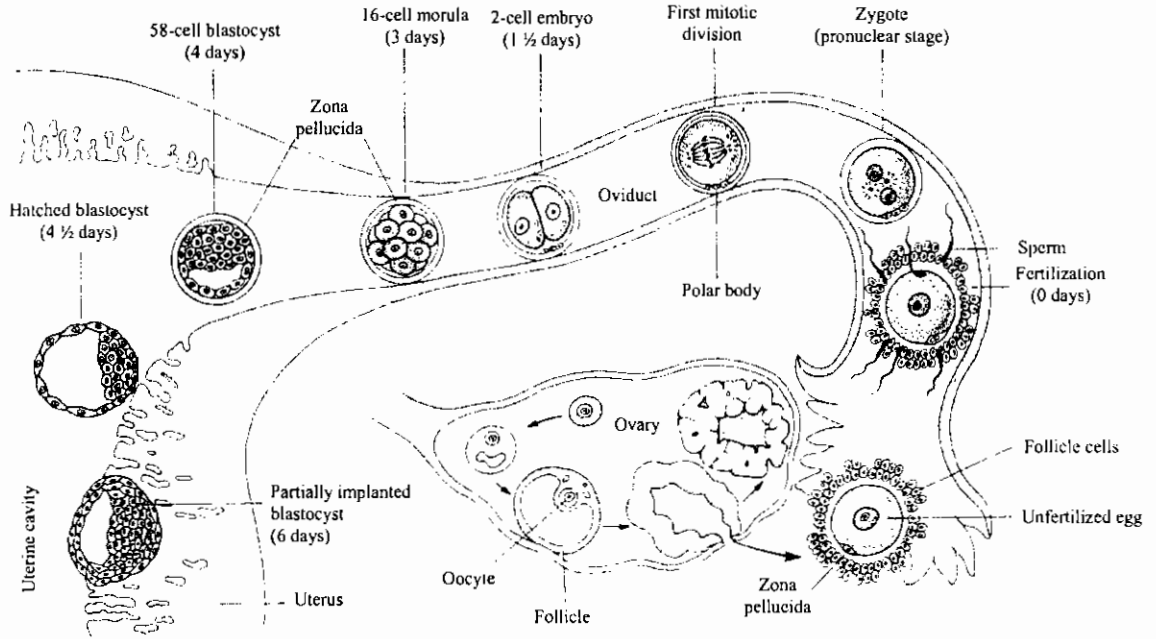
ق.ع. في جنين حيوان ثديي

T. s. of a mammalian embryo

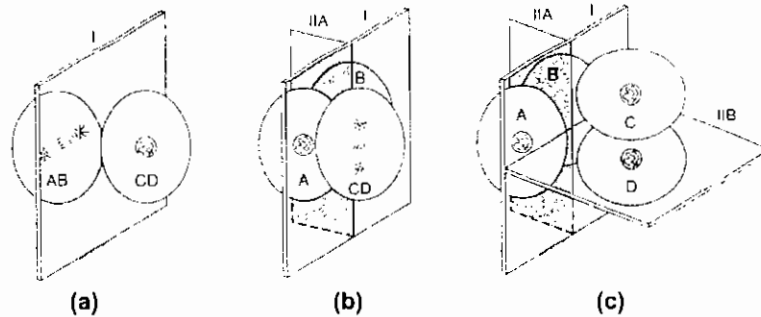


التبويض وانتقال الجنين إلى الرحم

Ovulation and the transport of embryo to uterus

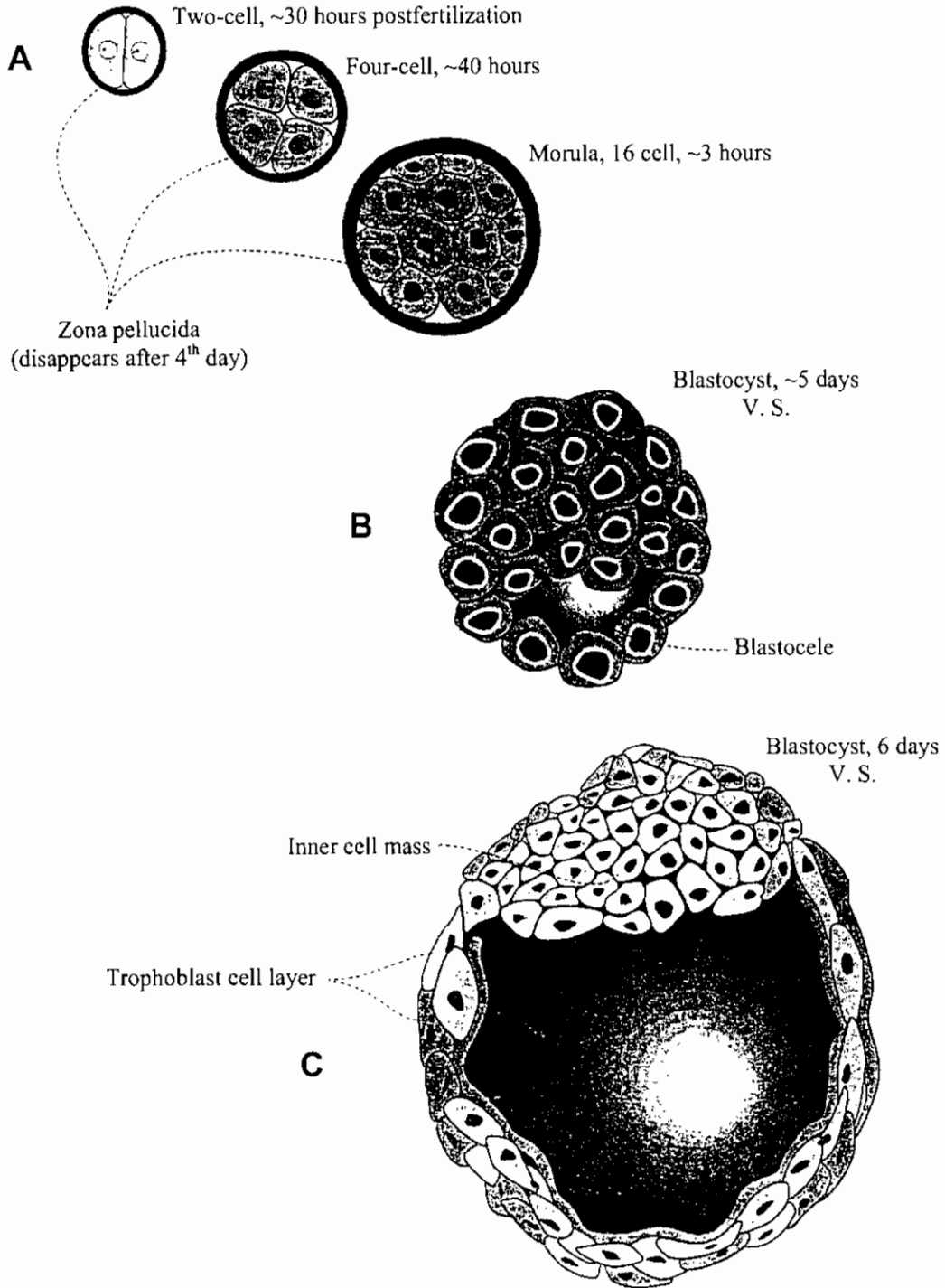


First week of human development. Fertilization occurs in the upper third of the oviduct. The zygote undergoes cleavage as it travels down the oviduct. About 4.5 days after fertilization, the embryo hatches from the zona pellucida and becomes implanted in the inner layer of the uterus.



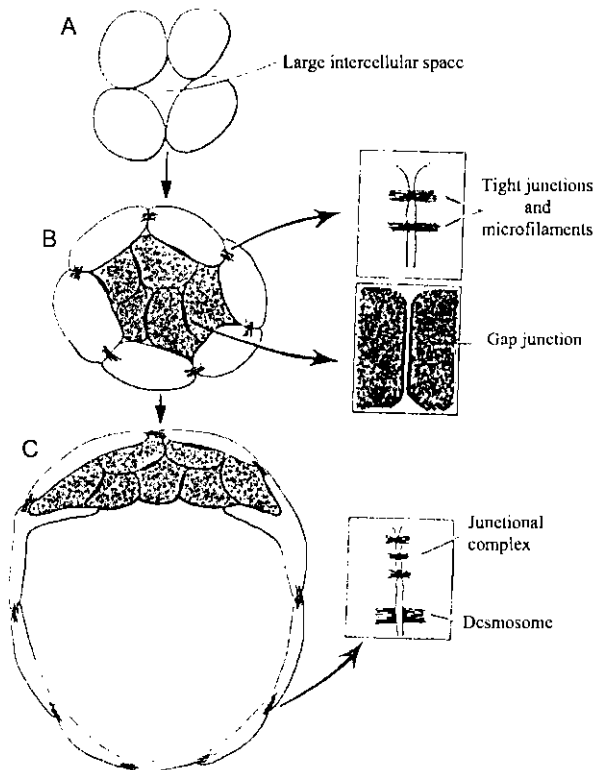

Rotational cleavage in mammals. (a) The first cleavage is on a meridional cleavage plane (I) passing through the animal-vegetal axis. The resulting two blastomeres are designated AB and CD. (b) The AB blastomere divides first, again on a meridional cleavage plane (IIA). The CD blastomere, which lags behind, elongates parallel to the furrow between A and B. Its mitotic spindle is oriented parallel to the long axis of the cell. (c) The CD blastomere divides on a cleavage plane (IIB) that is perpendicular to both I and IIA.

التفليج في جنين الإنسان
Cleavage in human embryo



منظر سطحي وقطاع رأسي في بلاستولة الإنسان

A scanning electron micrograph of a mouse blastocyst. The closely compacted appearance of the cells is attributable to the tight junctions that have developed between them. X 800.

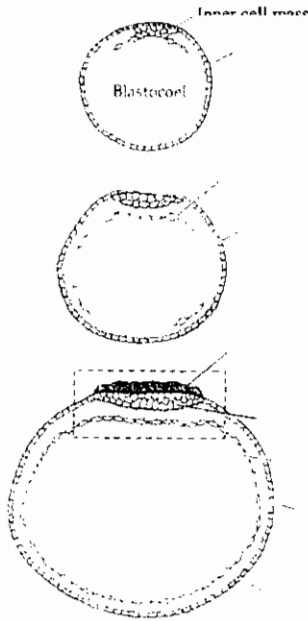


إلتحام الخلايا إثناء التفليج في جنين الفأر

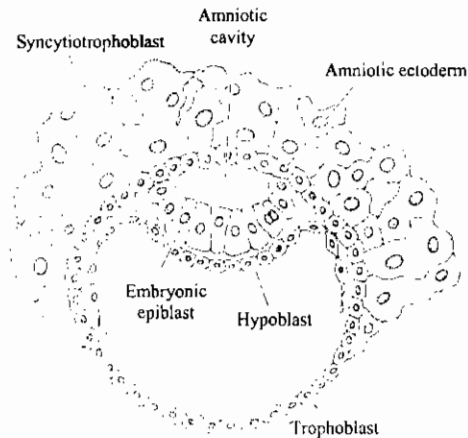
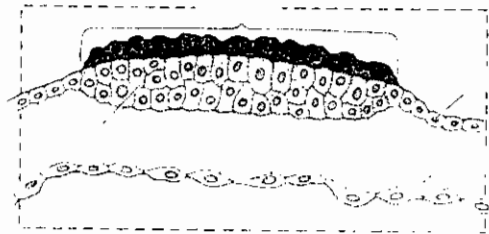
Cell junctions during cleavage of the mouse embryo. (Adapted from Denker, 1983.)

تكوين القرص الجنيني ذو الطبقتين في جنين الإنسان

Formation of two-layered blastodisc in human embryo



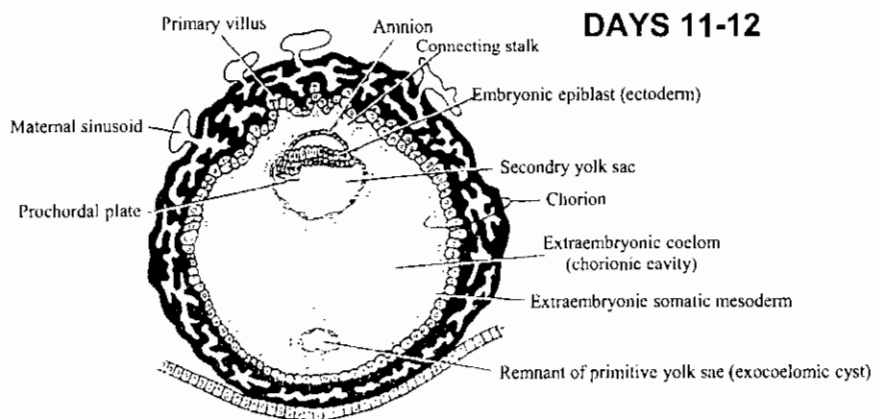
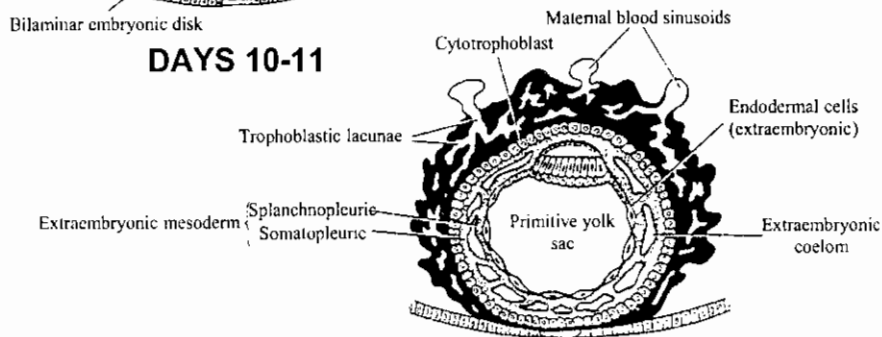
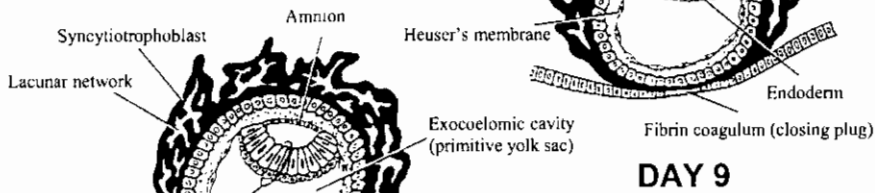
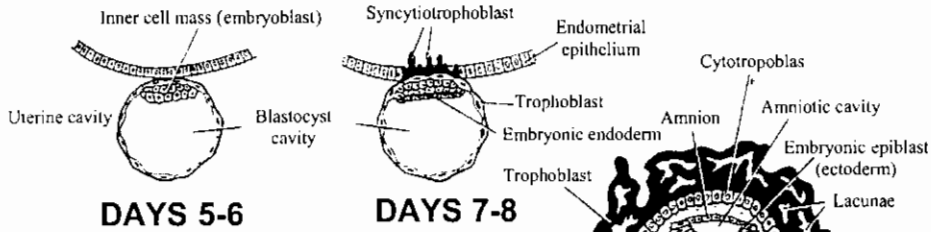
The mammalian blastocyst immediately prior to gastrulation. The inner cell mass delaminates hypoblast cells that line the trophoblast, thereby forming the primitive gut (A-C) and a two-layered (epiblast and hypoblast) blastodisc (D) similar to that seen in avian embryos. (After Carlson, 1981.)



Formation of the amnion in human embryos. The hypoblast is complete near the site of the inner cell mass, and the trophoblast cells are dividing to form the syncytiotrophoblast, which will invade the uterus. Meanwhile, the epiblast has split into the amniotic ectoderm and the embryonic epiblast. All subsequent development of the embryo will focus on the embryonic epiblast. (After Carlson, 1981.)

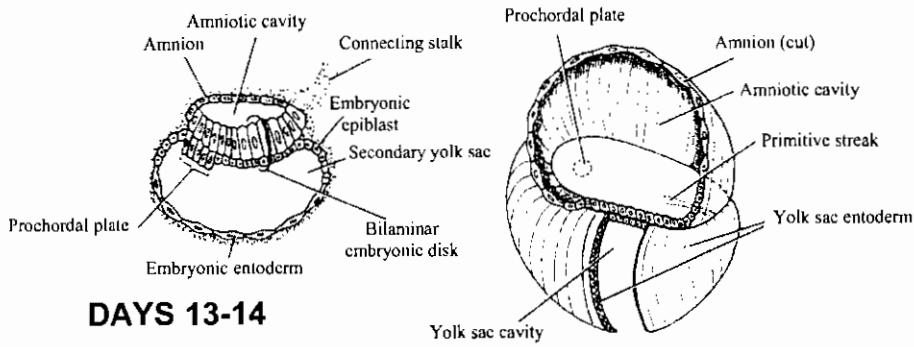
إنعقاد جنين الإنسان

Implantation of human embryo

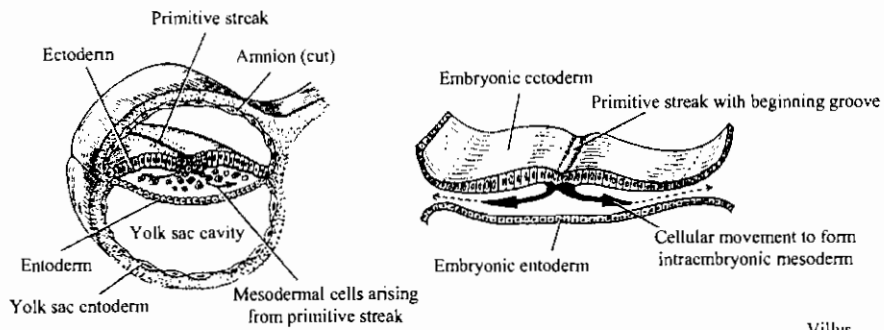


DAYS 13-14

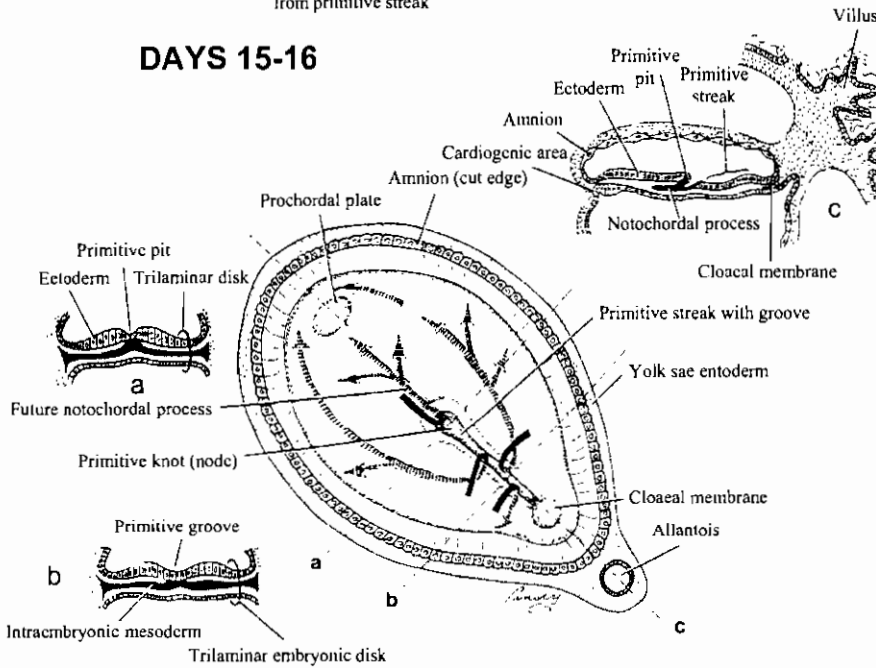
التكوين الأولي لجنين الإنسان



DAYS 13-14



DAYS 15-16

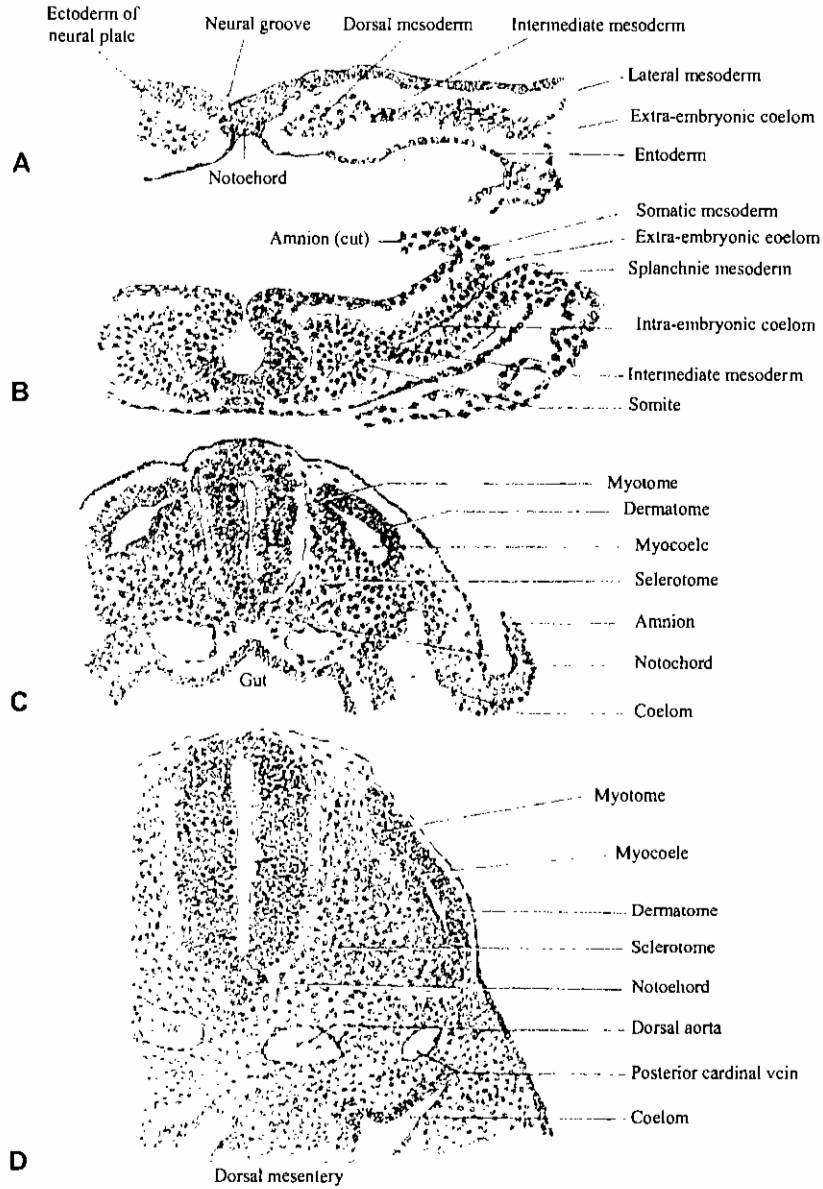


منظر ظهري للقرص الجرثومي في الإنسان، توضح الأسهم تحرك الخلايا الميزودرمية بين الأكتودرم والإندودرم

Dorsal view of Germ Disk

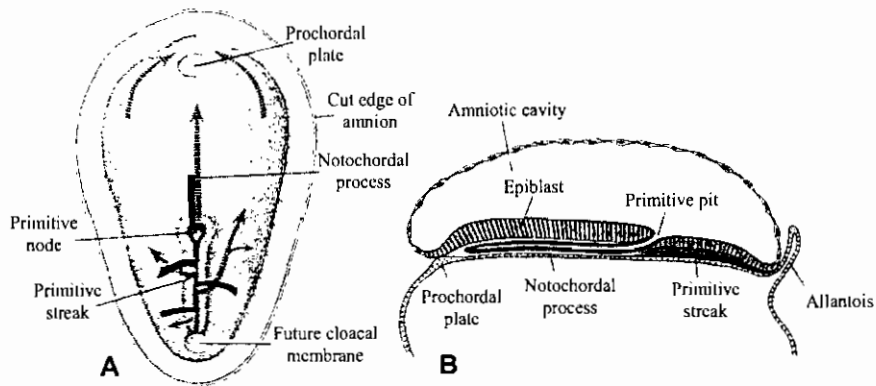
Arrows show movement of mesodermal cells between ectoderm and entoderm

قطاعات عرضية في أجنة خنزير في مراحل مختلفة توضح تكوين وتميز القطعة الميزودرمية

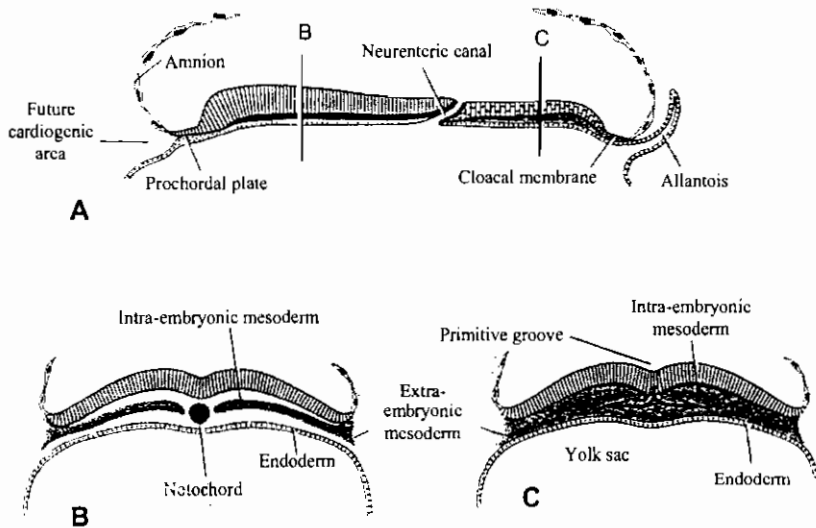


Drawings (X 150) from transverse sections of pig embryos of various ages to show formation and early differentiation of somites. (From series in the Carnegie Collection.) (A) Beginning of somite formation; (B) 7-somite embryo; (C) 16-somite embryo; (D) 30-somite embryo.

تكوين الجبل الظهرى فى جنين الانسان

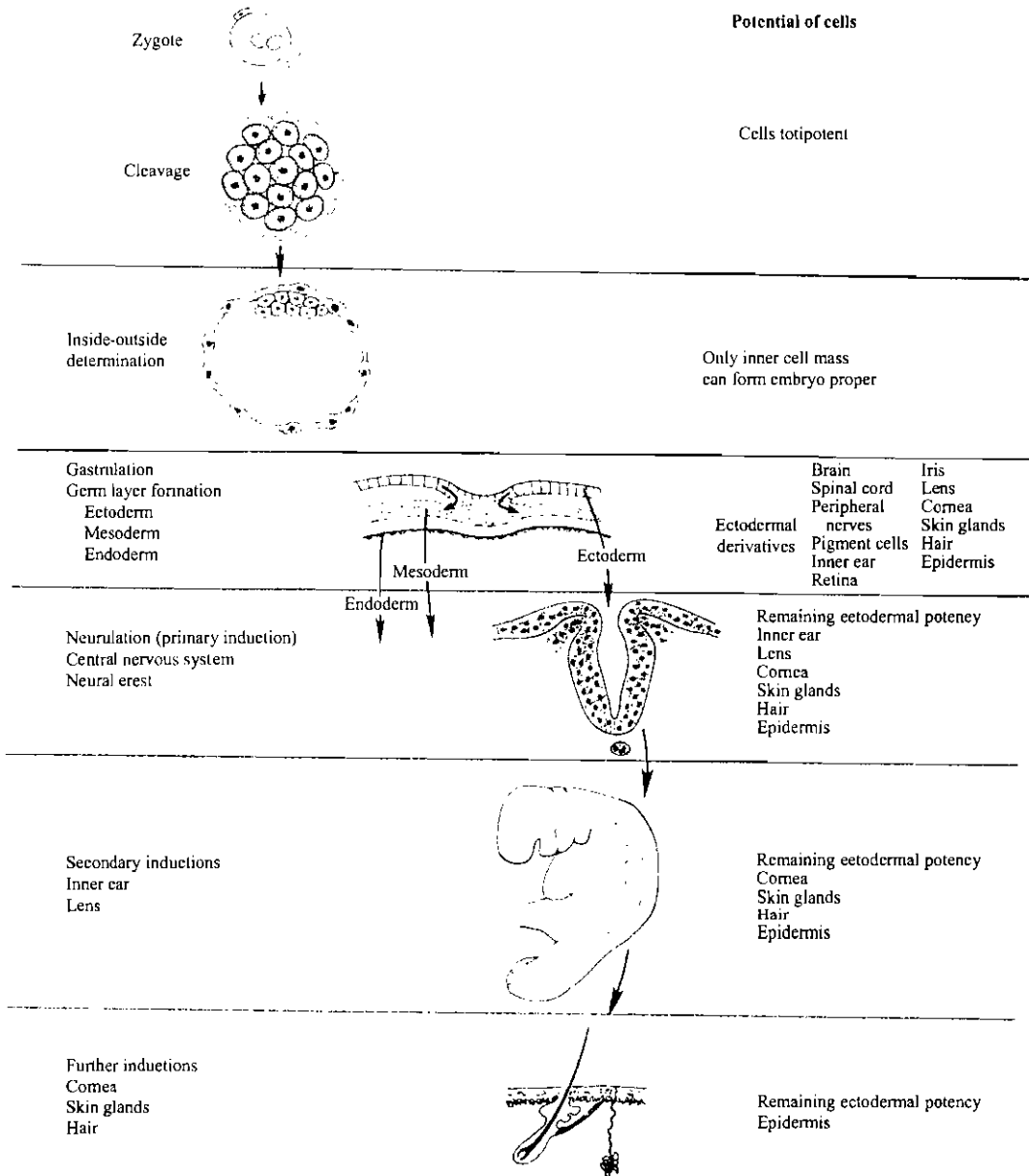


A, Schematic representation of the dorsal side of the germ disc, indicating the movement of surface cells (solid black lines) toward the primitive streak and node and the subsequent migration of cells between the hypoblast and epiblast germ layers (broken lines). **B**, Cephalocaudal midline section through a 16-day embryo. The notochordal process occupies the midline region extending from the prochordal plate to the primitive node. Note the notochordal or central canal in the center of the notochordal process.



A, Drawing of a cephalocaudal midline section through an 18-day embryo. The definitive notochord is established. The neurenteric canal connects the amniotic cavity with the yolk sac. **B**, Transverse section through the cephalic part of the embryo showing the definitive notochord flanked by intraembryonic mesoderm. **C**, Transverse section through the primitive streak region. Mesoderm formation in the caudal part of the embryo continues into the 4th week.

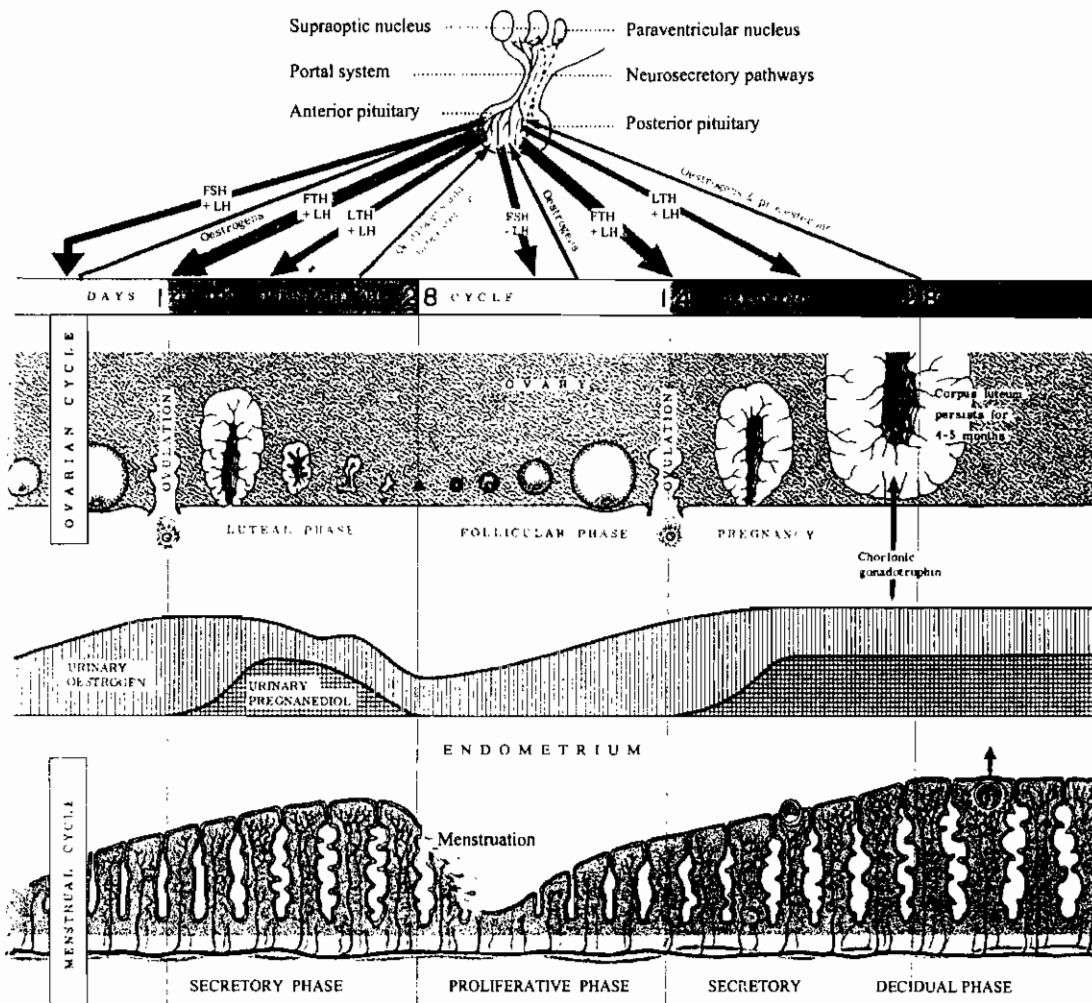
تحديد المسار أثناء النمو الجنيني



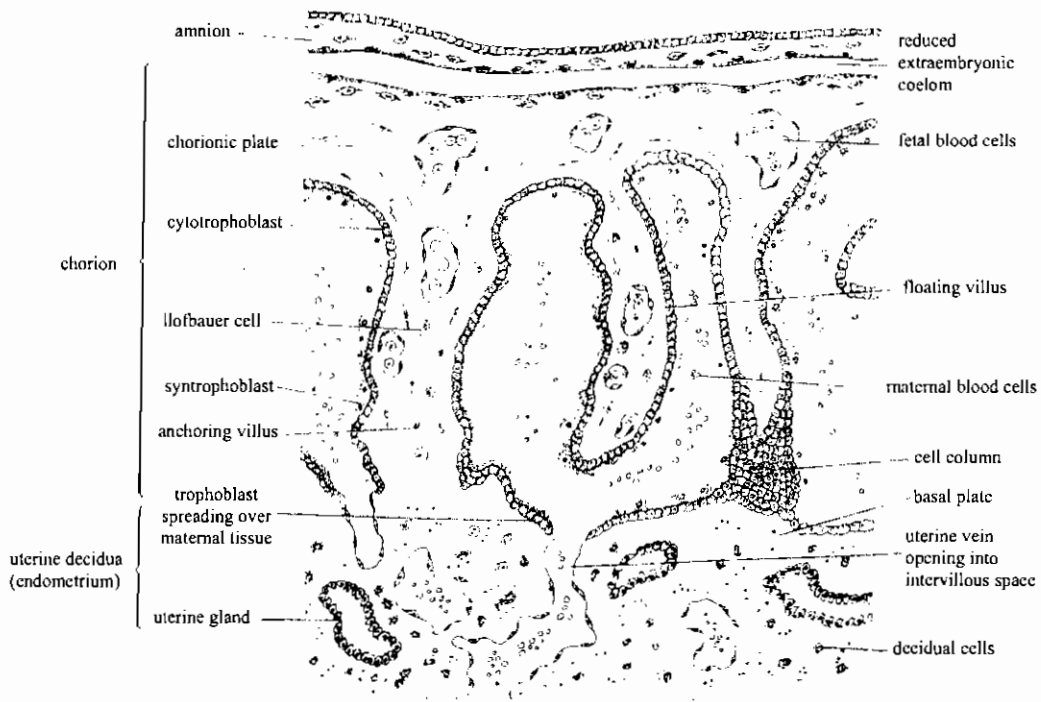
Restriction during embryonic development. The labels on the right illustrate the progressive restriction of the developmental potential of cells that are in the line leading to formation of the epidermis. On the left are developmental events that remove groups of cells from the epidermal track.

العوامل المؤثرة على التبويض في الثدييات
 Factors involved in mammalian ovulation

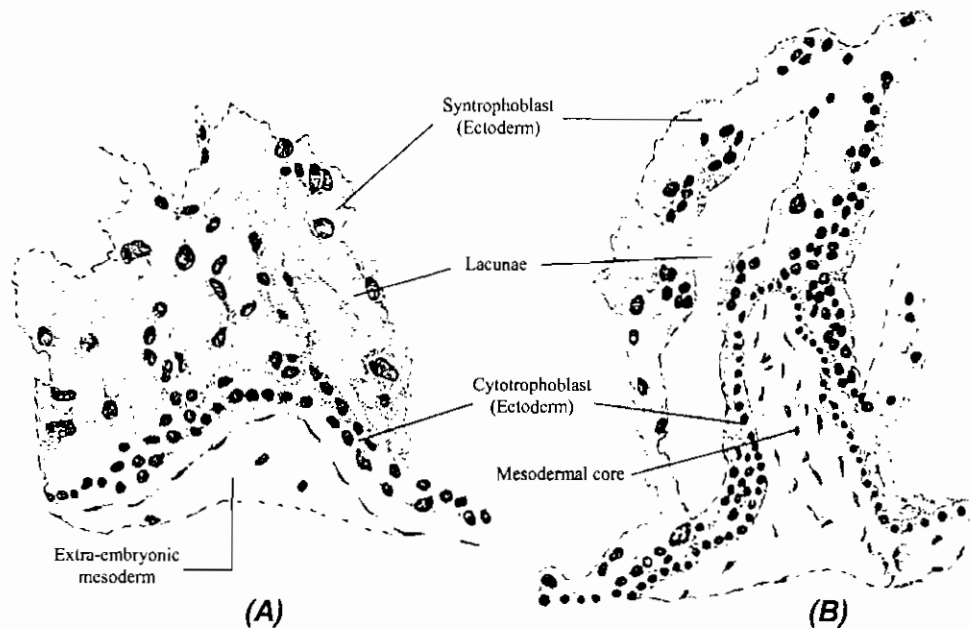
The Female Reproductive Cycles



تكوين الخملات السلوية في الثدييات



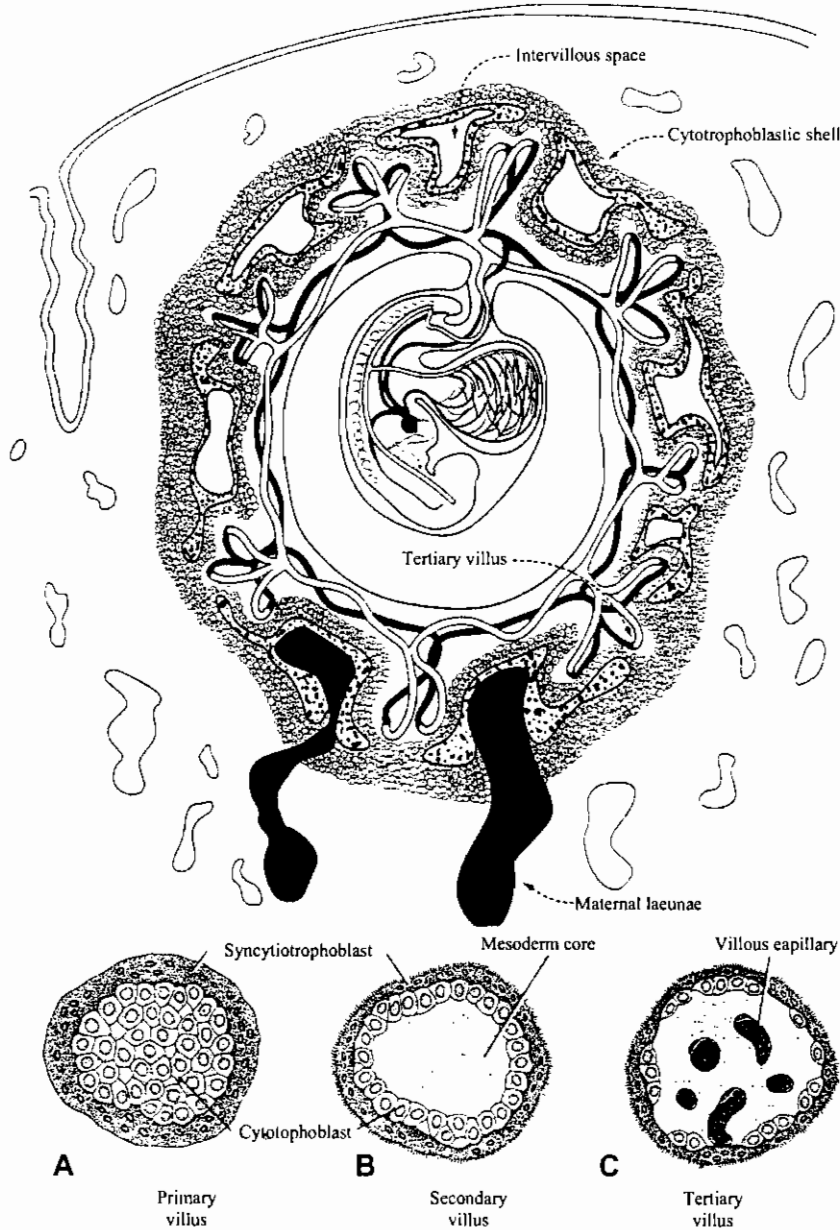
Semischematic drawing showing the relations of the chorionic villi and trophoblast to maternal endometrial tissues of the human placenta. (Redrawn from B. M. Patten (after Hill), *Human Embryology*. Copyright 1968 by McGraw-Hill Book Co. Used with permission of the McGraw-Hill Book Co.)



The early development of chorionic villi. (A) Ectodermal primary villus. (B) Early invasion of mesodermal core, creating secondary villus. (Drawn from photographs by Streeter.)

تكوين خملات السلى فى جنين الانسان

Development of human chorionic villi

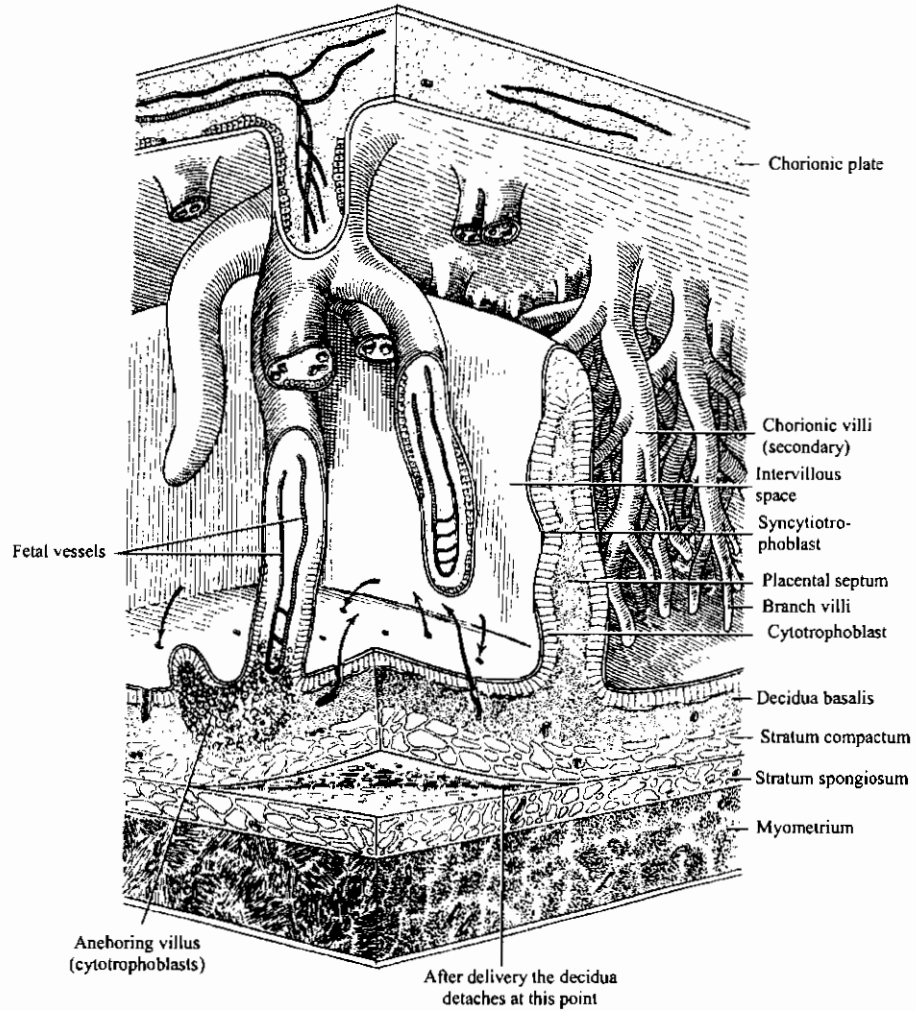


قطاعات عرضية توضح تكوين الخملات

Schematic drawings to show the development of the villus. **A**, Transverse section of a primary villus, showing a core of cytotrophoblastic cells covered by a layer of syncytium. **B**, Transverse section of a secondary villus with a core of mesoderm covered by a single layer of cytotrophoblastic cells, which in turn is covered by the syncytium. **C**, The mesoderm of the villus shows a number of capillaries and venules.

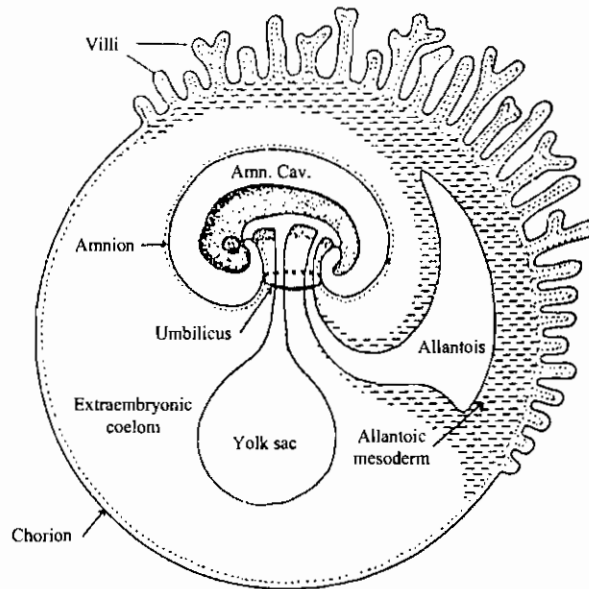
تبادل المواد عبر المشيمة

Exchange of substances across the placenta

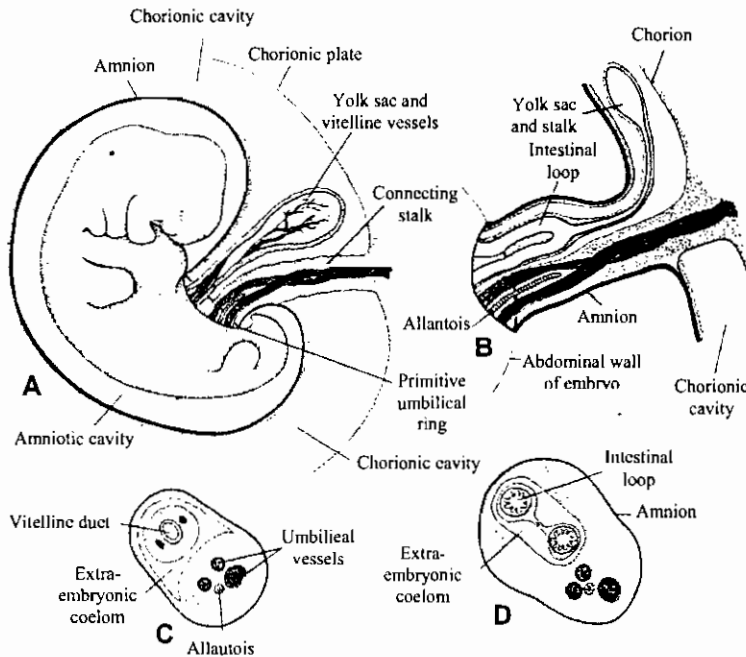


Schematic drawing of placental structure. Arrows indicate the blood flow from decidual arteries to intervillous space and back to decidual veins. This direction is determined by the difference in pressure between arterial and venous blood. (Redrawn and reproduced, with permission, from Duplessis GDT, Haegel P: *Embryologie*. Masson, 1971. [English edition © Springer-Verlag, 1972; Masson, 1972.]

تكوين الحبل السرى فى جنين الإنسان
 Development of human umbilical cord



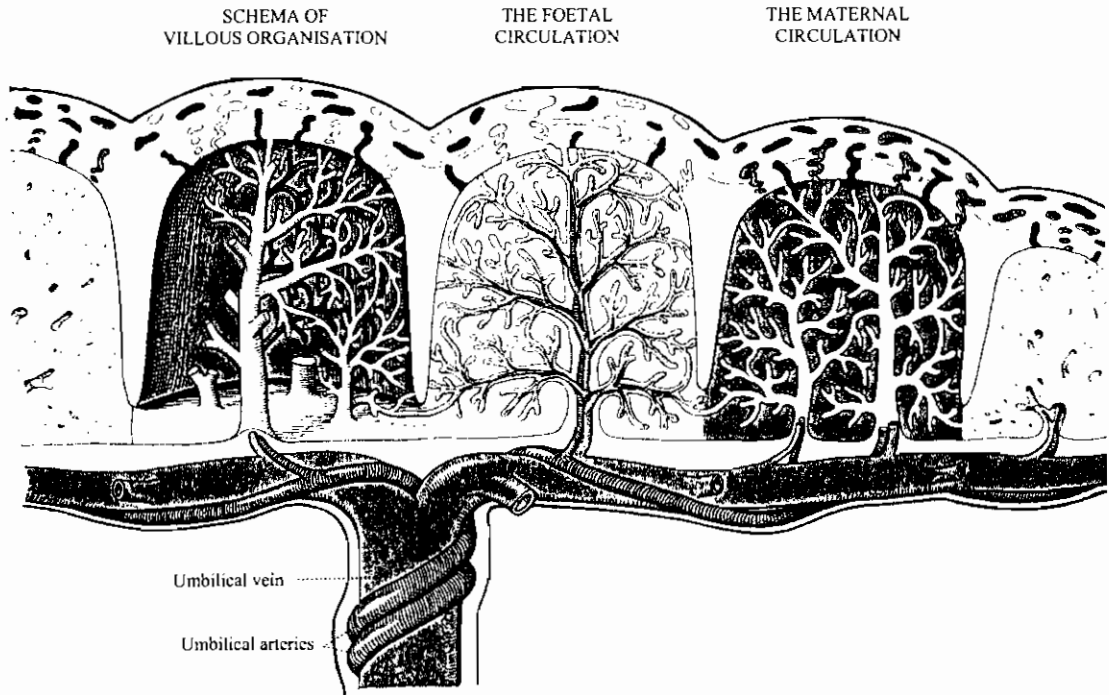
Embryo and membranes of a placental mammal, showing placental development from fused chorion and allantoic wall, extending as fingerlike villi that interlock with uterine tissue.



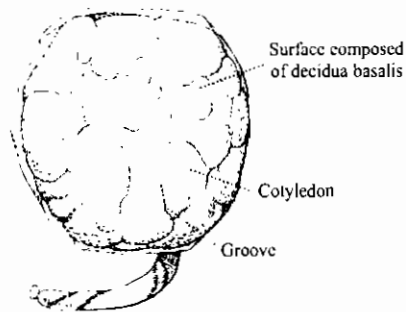
A, Schematic drawing of a 50week embryo to show the structures passing through the primitive umbilical ring. **B**, Schematic drawing of the primitive umbilical cord of a 10-week embryo. **C**, Transverse section through the structures at the level of the umbilical ring. **D**, Transverse section through the primitive umbilical cord, showing the intestinal loops protruding in the cord.

المشيمة في نهاية الحمل

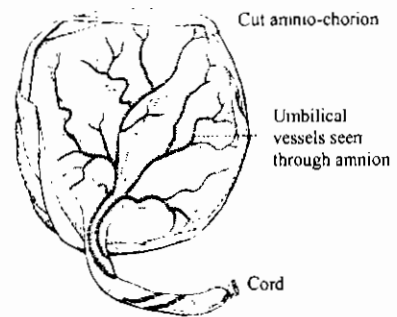
The Placenta at Term



FOETAL SURFACE



MATERNAL SURFACE



مقارنة بين الأغشية الجنينية للدجاج والخنزير والإنسان

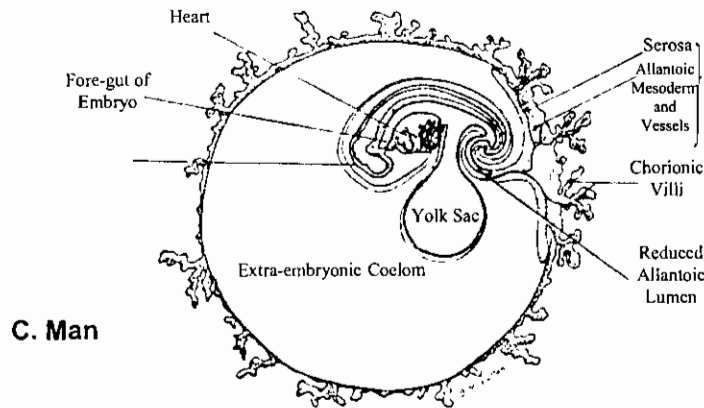
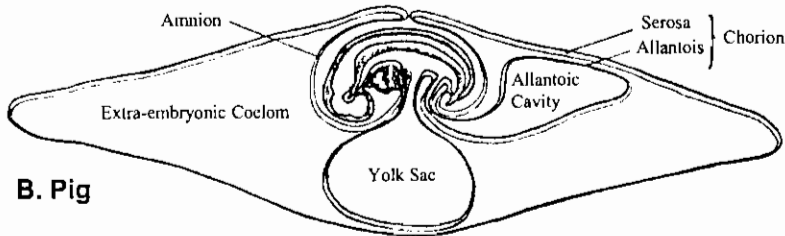
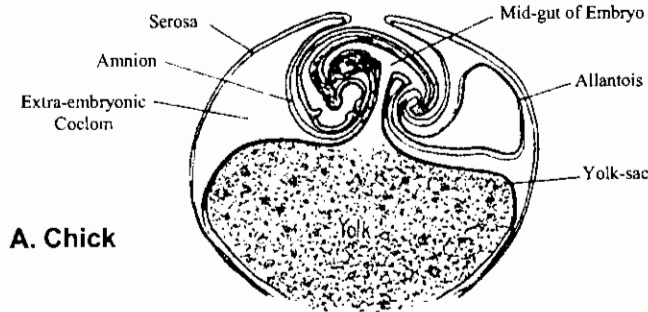
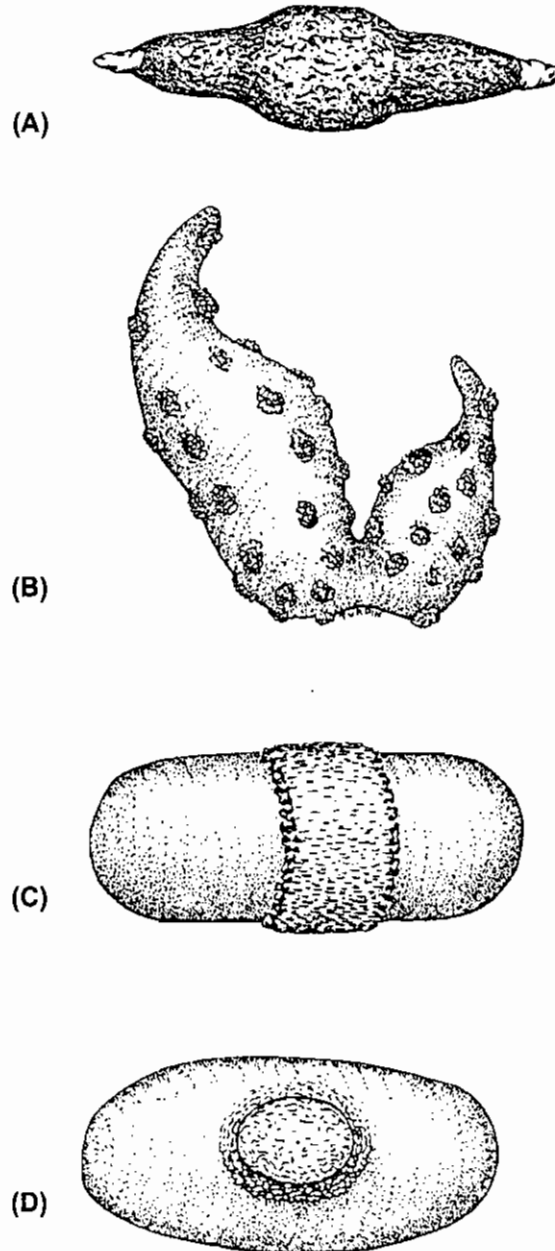


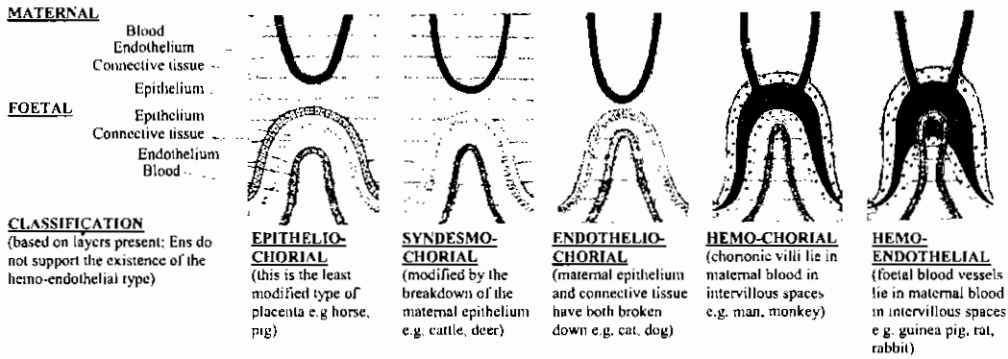
Diagram showing interrelations of embryo and extra-embryonic membranes characteristic of higher vertebrates. Neither the absence of yolk from its yolk-sac nor the reduction of its allantoic lumen radically changes the human embryo's basic architectural scheme from that of more primitive types.

أنواع الأكياس السلوية في الثدييات حسب توزيع الخملات على سطحها

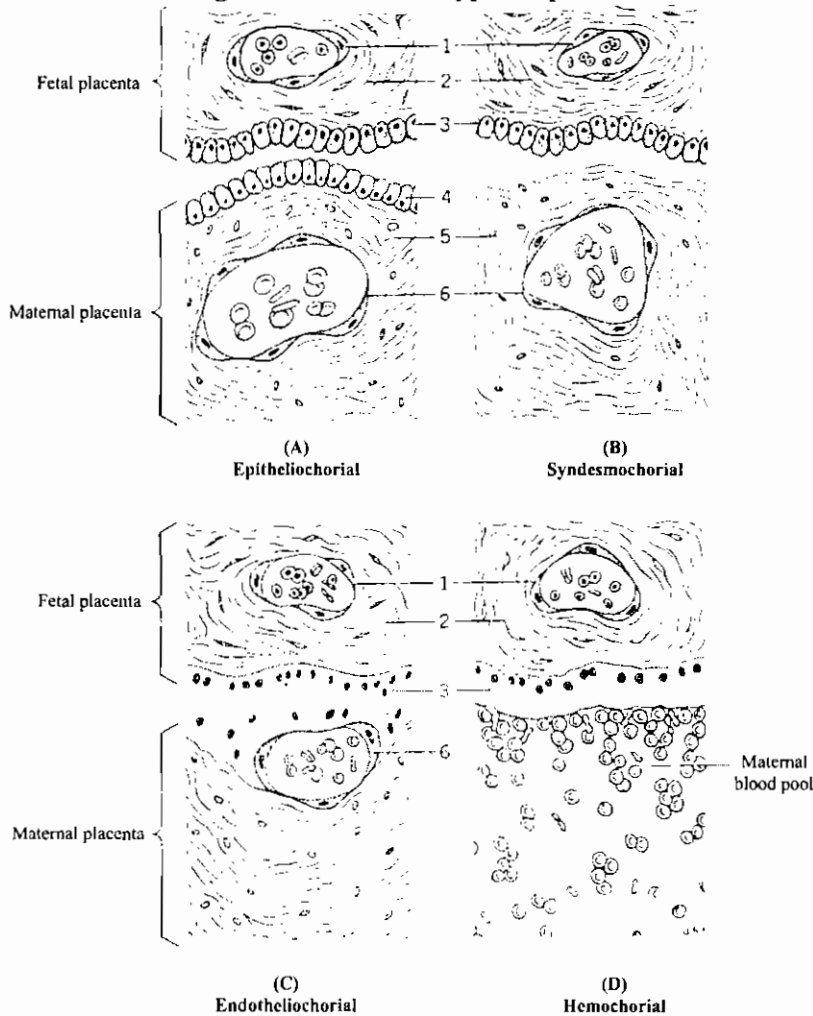


Diagrams of chorionic sacs of representative mammals, showing gross forms of the placenta. (A) Diffuse placenta of the pig. (B) Cotyledonary placenta of the sheep. (C) Zonary placenta of the dog. (D) Discoidal placenta of the bear.

الأنواع النسيجية في مشيمة الثدييات المختلفة



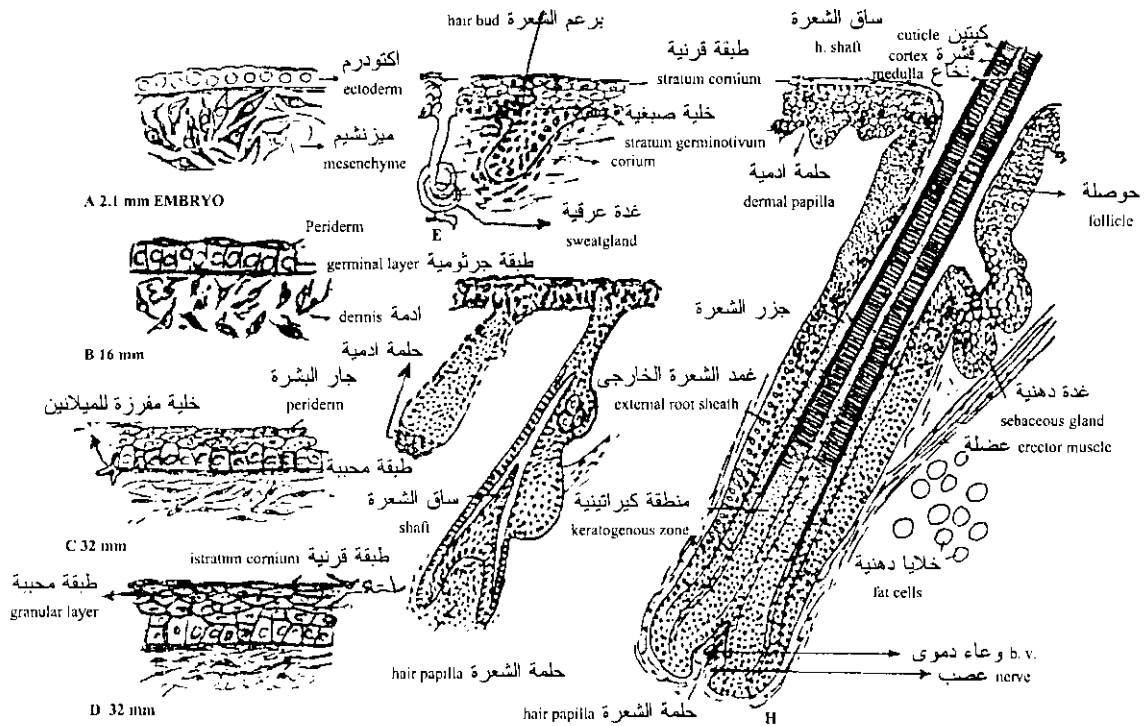
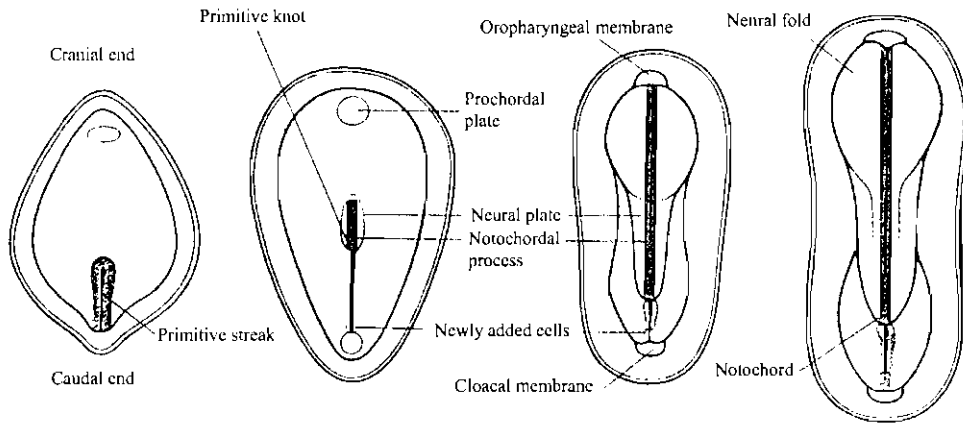
Diagrams of different types of placenta



Histological types of mammalian placentae. 1- endothelium of fetal blood vessel. 2- chorionic connective tissue. 3- chorionic epithelium. 4- uterine epithelium. 5- endometrial connective tissue (mucosa). 6- endothelium of maternal blood vessel.

تكوين الشق البدائي وعقدة هensen في جنين الانسان

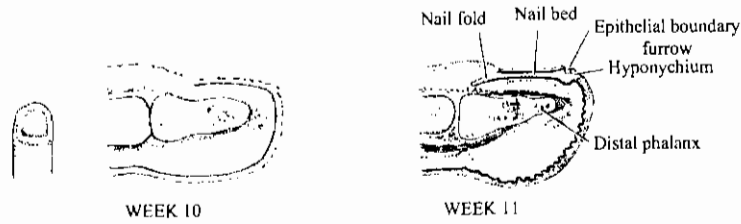
The appearance of the primitive streak and primitive knot along the embryonic disc. These progressive changes occur through the process of induction.



مراحل تكوين الجلد والشعر في الثدييات

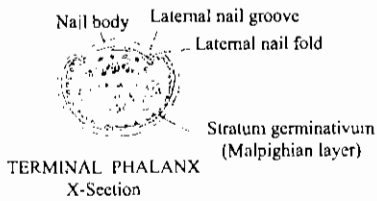
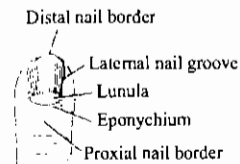
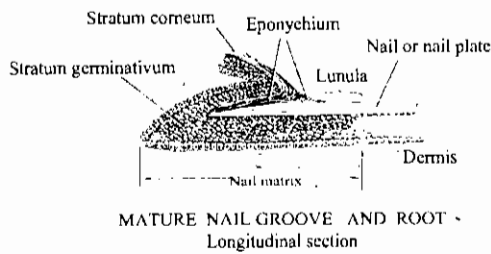
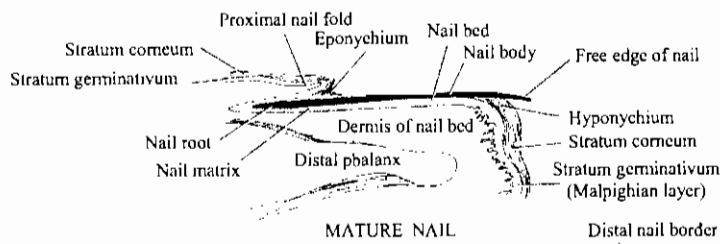
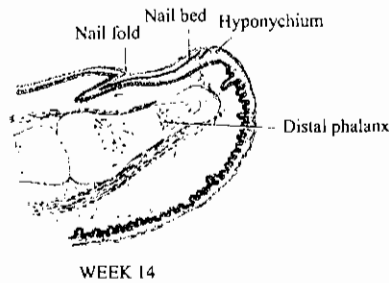
Development of the human epidermis and hair follicle. A, epidermis of 2.1 mm embryo / B, epidermis of 16-mm embryo: C, epidermis of 32-mm embryo: D, epidermis of 85-mm embryo / E to H, progressive stages in the development of the follicle and hair. (After Potten, 1946).

تكوين الظفر في الإصبع



DEVELOPMENT OF FINGERNAIL

Sections of fingertip

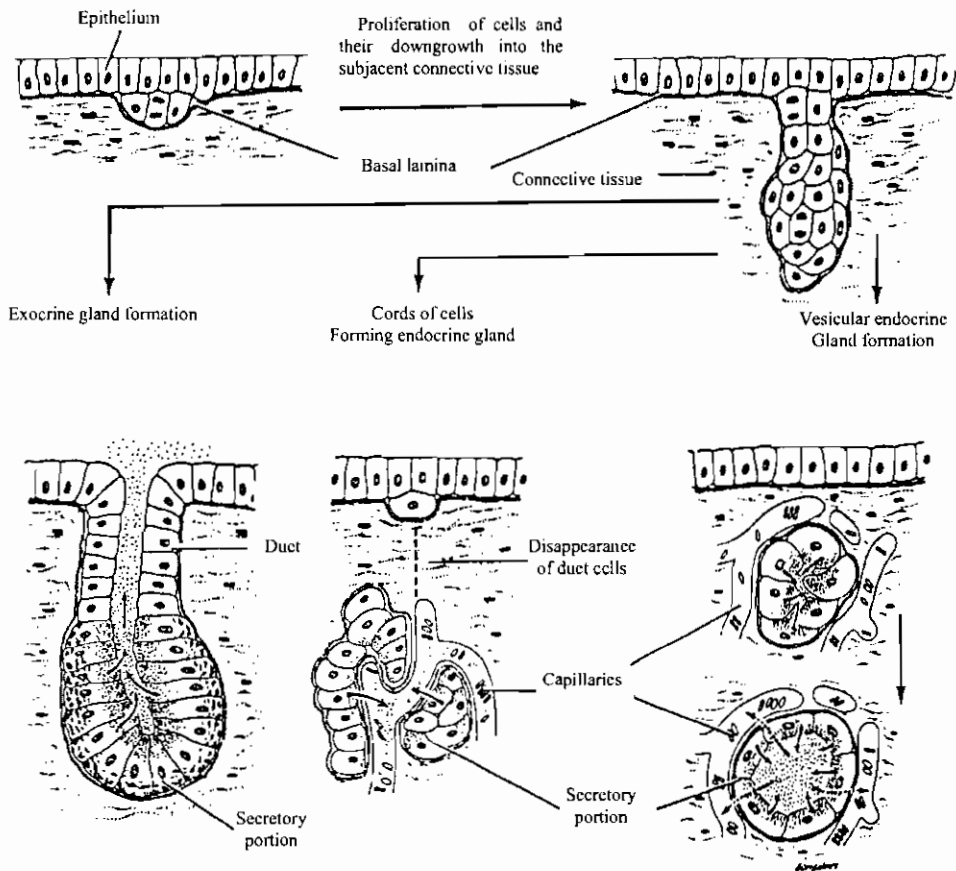


تكوين الغدد

Development of glands:

Glands are formed in the following sequence

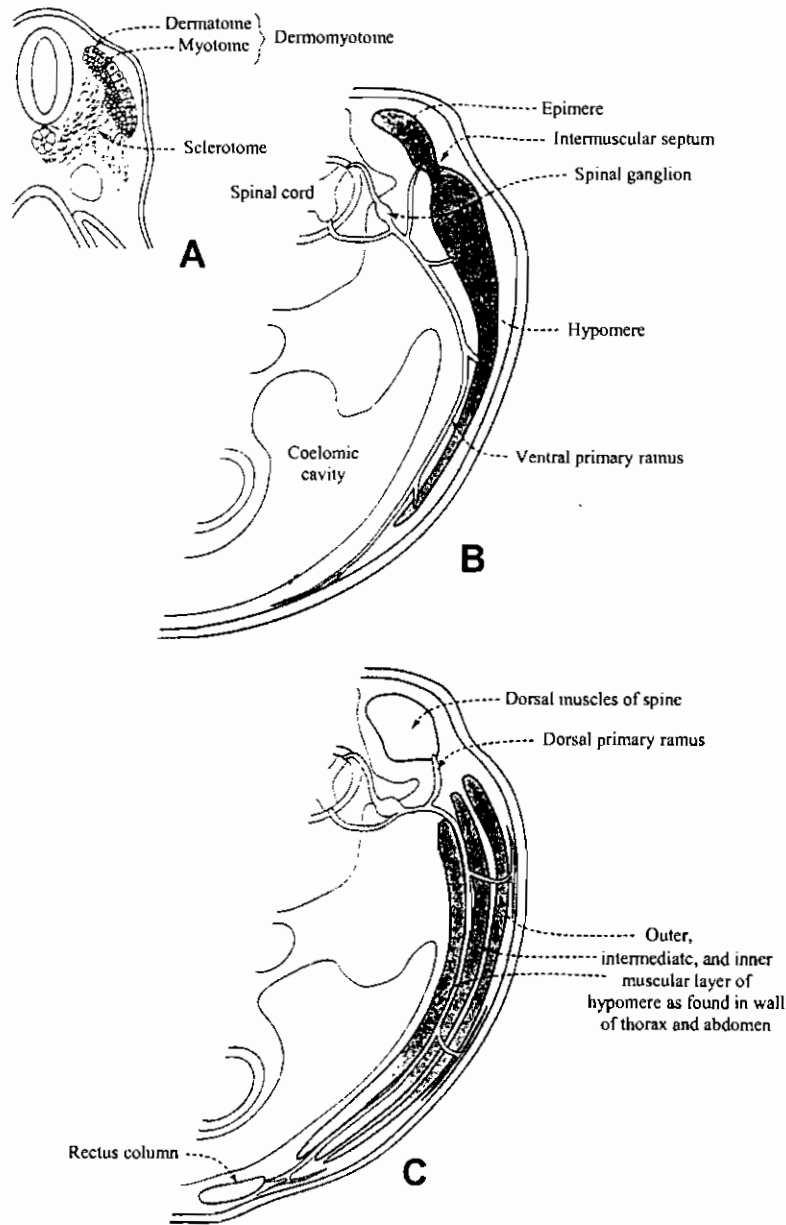
- 1- Invagination of a solid cord of epithelial cells.
- 2- Branching of the cord.
- 3- Cords hollow out to produce ducts.
- 4- Ends of branches hollow out to produce acini.



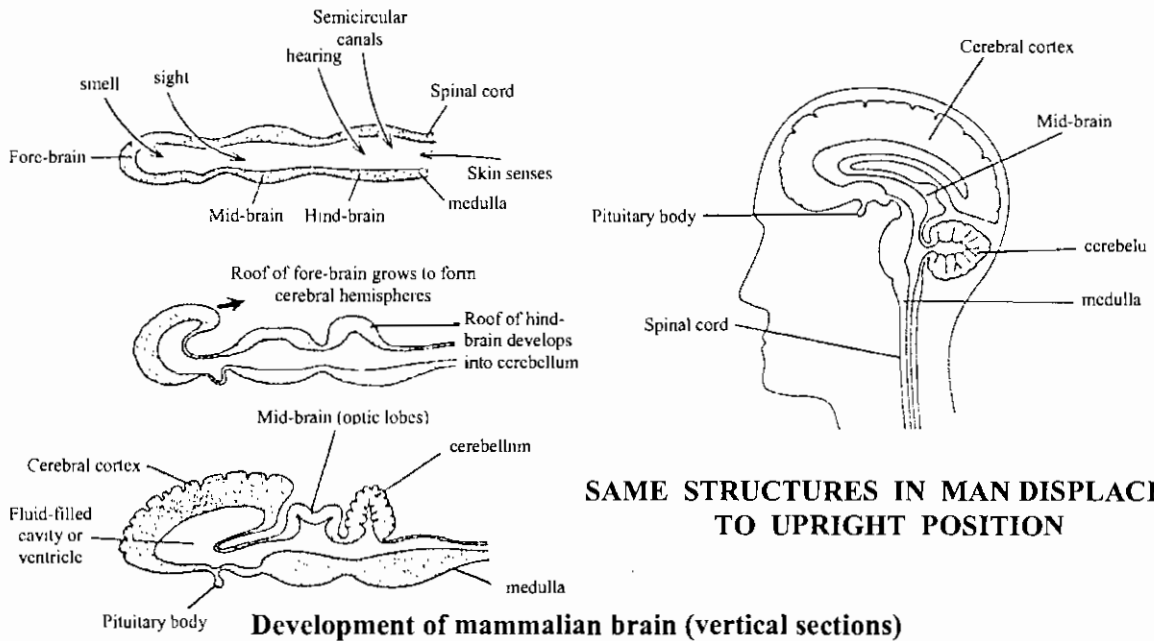
Formation of glands from covering epithelia. Epithelia cells proliferate and penetrate into connective tissue. They may or may not maintain contact with the surface. When contact is maintained, exocrine glands are formed; when contact is not maintained, endocrine glands are formed. The cells of these glands can be arranged in cords or follicles. The lumens of follicles accumulate large quantities of secretion; cells of the cords store only small quantities in their cytoplasm. (Redrawn and reproduced, with permission, from Ham AW: *Histology*, 6th ed. Lippincott, 1969.)

قطاعات ع. في أجنة الانسان توضح تميز القطعة الميزودرمية ثم تميز العضلات المختلفة وإمدادها بالأعصاب

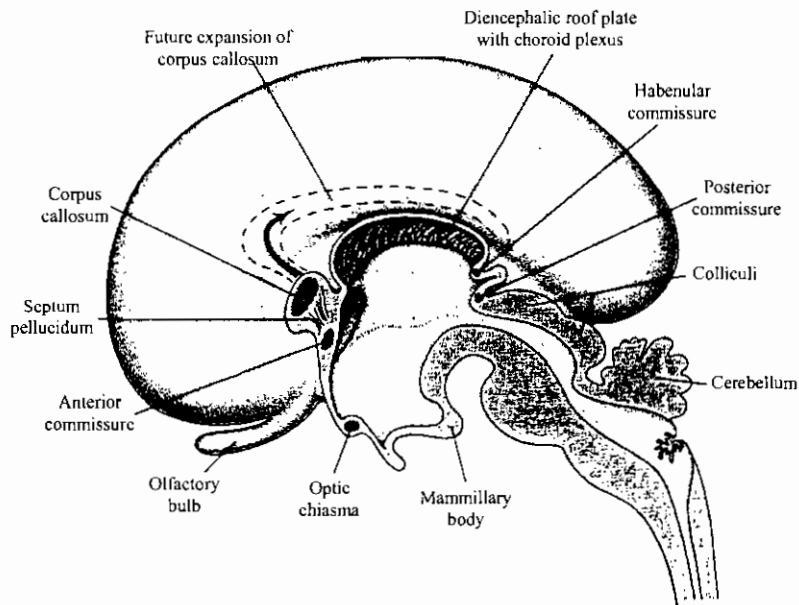
T. s. of human embryos showing differentiation of the mesodermal somites and the differentiation of the muscles and their innervation



تكوين مخ الإنسان



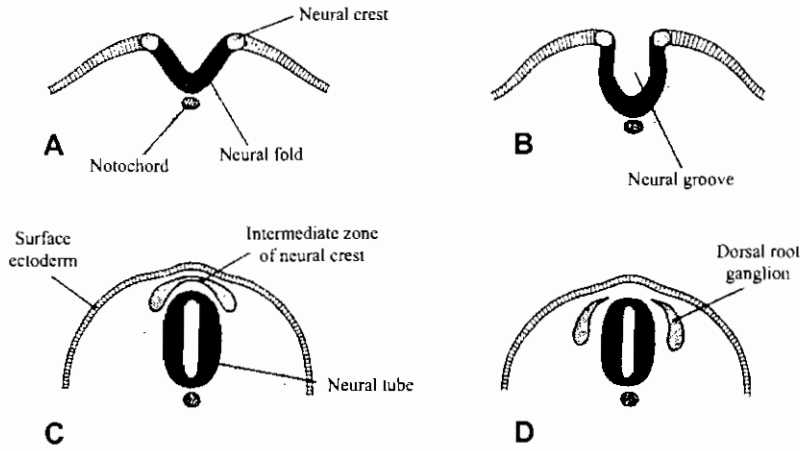
Development of mammalian brain (vertical sections)



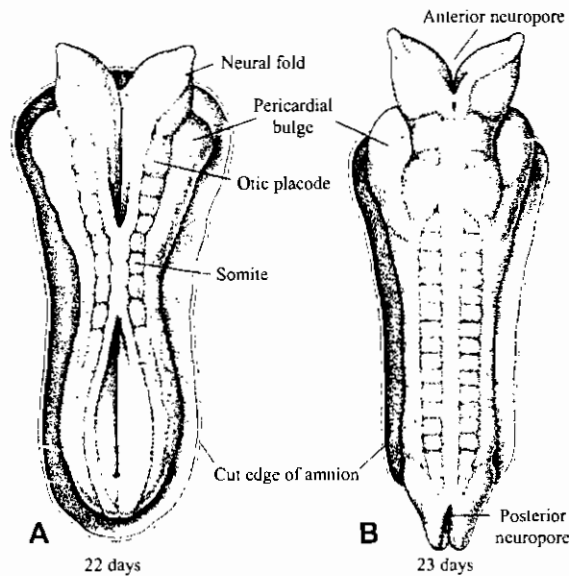
تركيب مخ الإنسان Structure of the human brain

L. View of the medial surface of the right half of the brain in a 4-month embryo, showing the various commissures. The broken line indicates the future expansion of the corpus callosum. The hippocampal commissure is not indicated.

تكوين الأنبوبة العصبية في جنين الإنسان

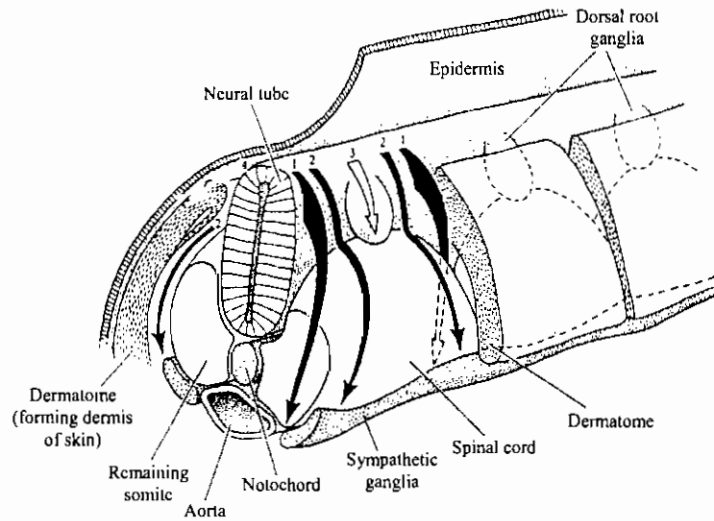


Schematic drawings of a number of transverse sections through successively older embryos, showing the formation of the neural folds, neural groove, and neural tube. The cells of the neural crest, initially forming an intermediate zone between the neural tube and surface ectoderm (C) develop into the dorsal root and cranial sensory ganglia (D).

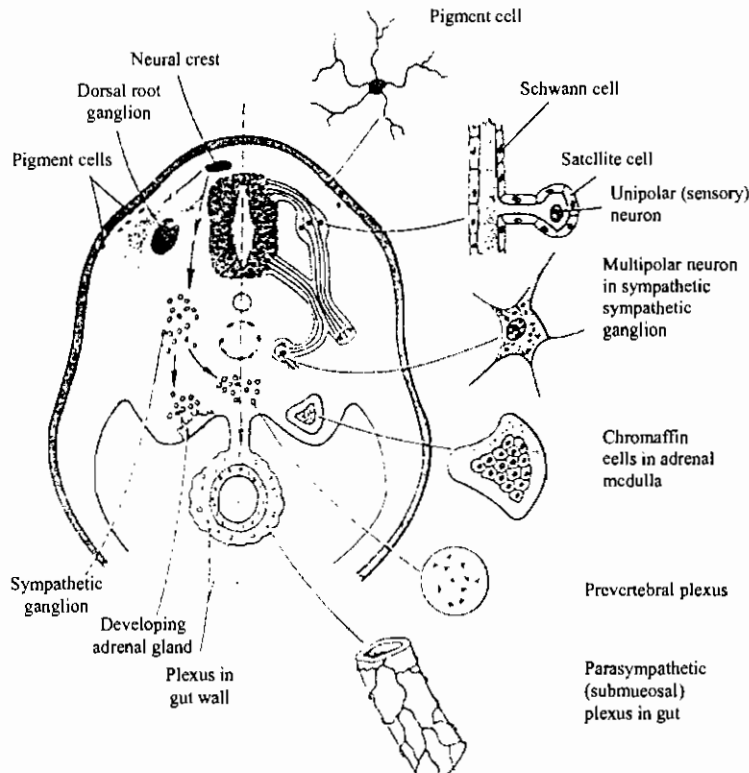


A, Dorsal view of a human embryo at approximately day 22. (Modified after Payne.) Seven distinct somites are visible on each side of the neural tube. **B**, Dorsal view of a human embryo at approximately day 23. (Modified after Corner.) Note the pericardial bulge on each side of the midline in the cephalic part of the embryo.

هجرة خلايا العرف العصبى وتميزها فى الأعضاء المتكونة منها

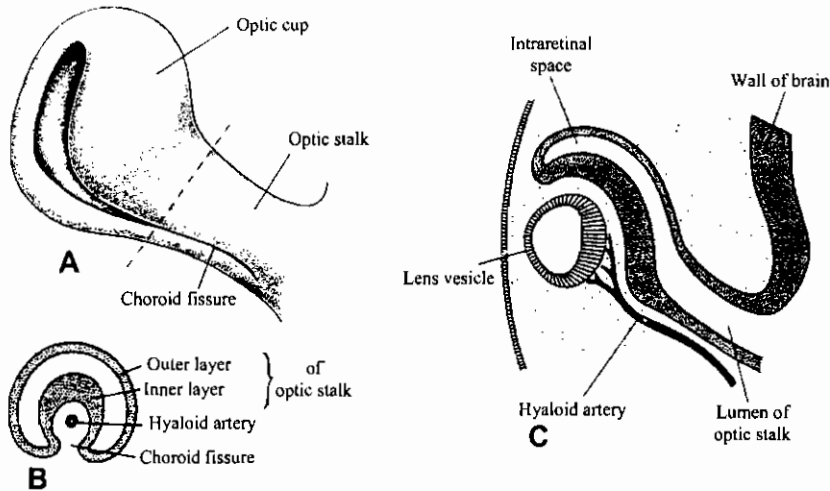


Paths of neural crest cell migration in the trunk of an embryo. Path 1 between adjacent somites, results in the formation of the sympathetic ganglia and adrenal medullary cells. In other regions of the trunk, neural crest cells form the parasympathetic ganglia. Those cells taking path 2 also contribute to the sympathetic ganglia. Neural crest cells migrating in path 3 become the neurons of the dorsal root ganglia, and those neural crest cells migrating beneath the ectoderm (4) give rise to the pigment cells.

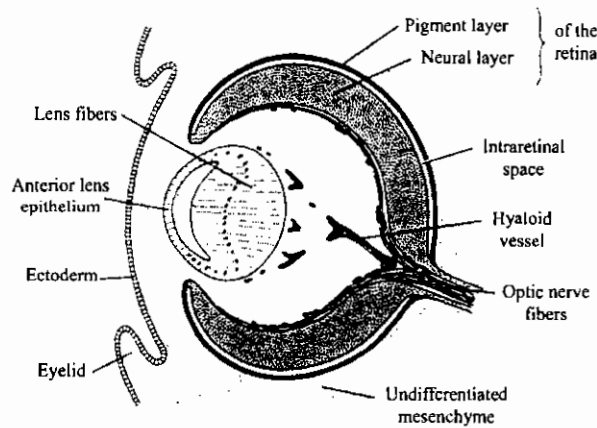


Major neural crest migratory pathways and derivatives in the trunk. Left: Pathways in the early embryo. Right: Derivatives of the trunk neural crest.

تكوين العين في الإنسان

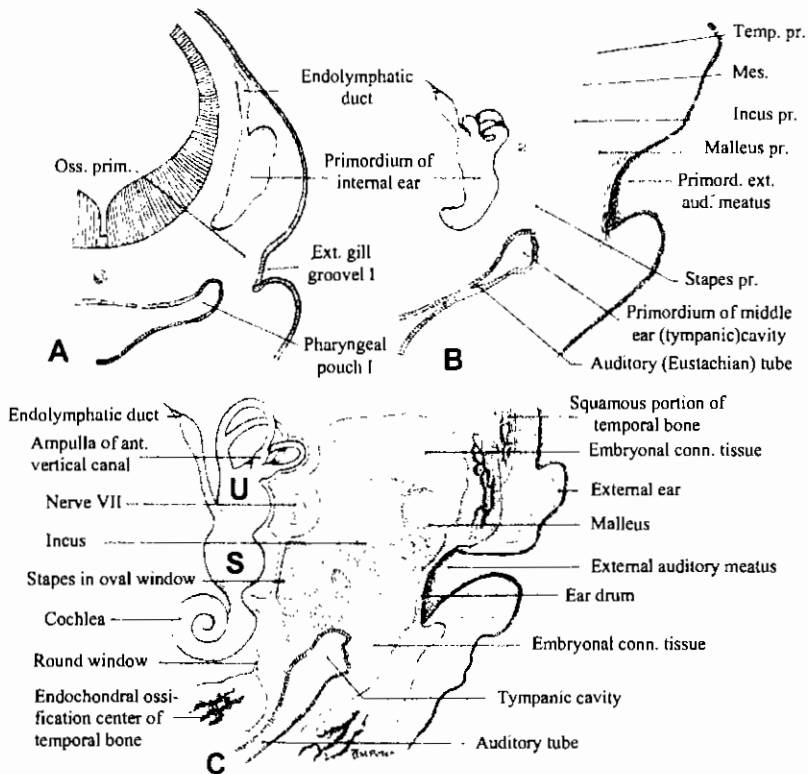


A, Ventrolateral view of the optic cup and optic stalk of a 6-week embryo. The choroid fissure located on the undersurface of the optic stalk gradually tapers off. B, Transverse section through the optic stalk as indicated in A, showing the hyaloid artery in the choroid fissure. C, Section through the lens vesicle, the optic cup, and optic stalk at the plane of the choroid fissure. (After Mann IC: The Development of the Human Eye, ed 3 [British Medical Association]. New York, Grune & Stratton, 1974.)

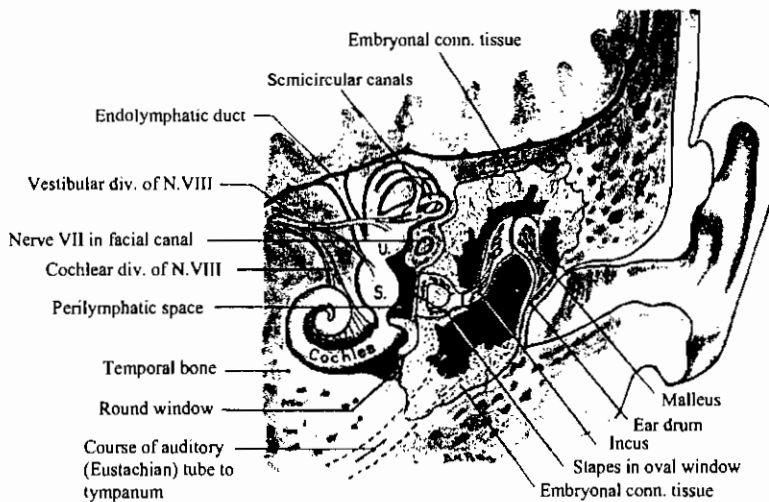


Anteroposterior section through the eye of a 7-week embryo. The eye primordium is completely embedded in mesenchyme. The fibers of the neural retina converge toward the optic nerve. (Modified after mann IC: The Development of the Human Eye, ed 3 [British Medical Association]. New York, Grune & Stratton, 1974.)

تكوين الأذن في الإنسان

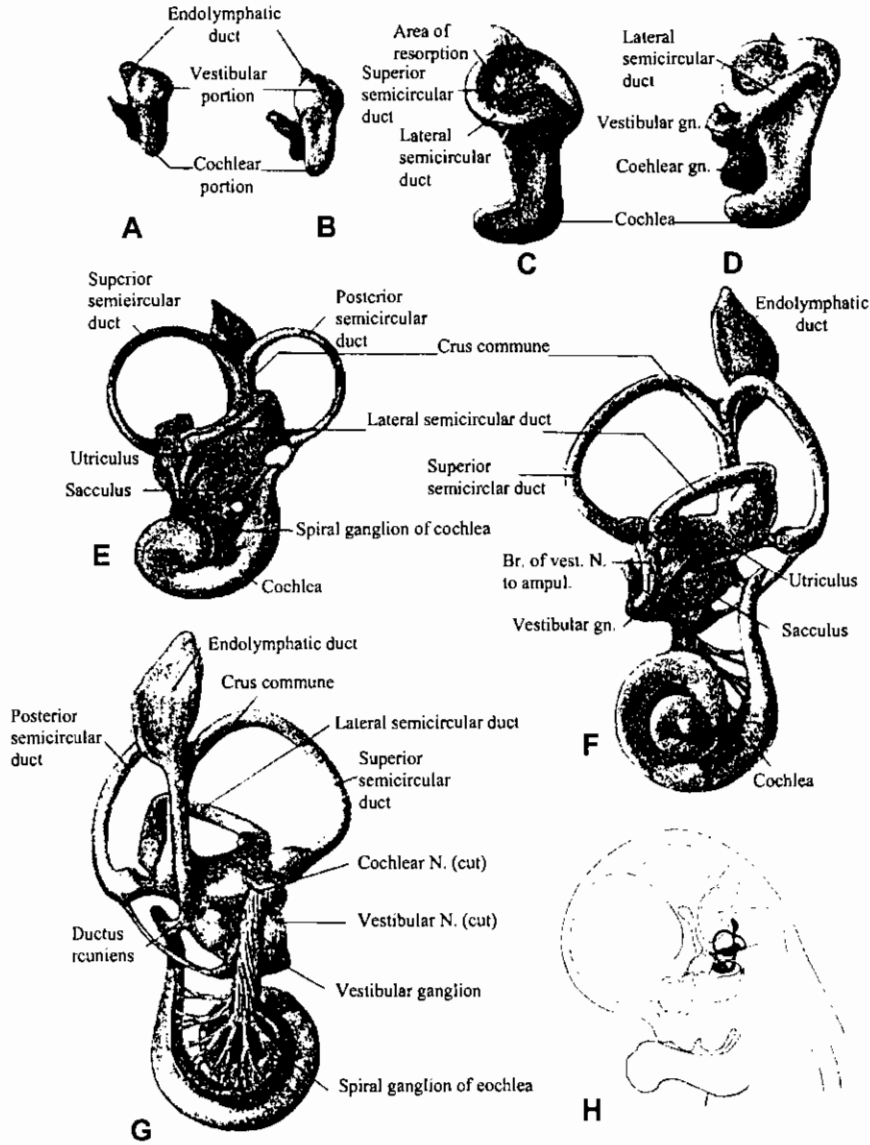


Schematic diagrams showing three stages in the development of the middle-ear chamber and the auditory ossicles. Abbreviations: Mes. –mesenchyme; Oss. Prim.-mesenchymal concentration which is the first indication of the primordia of the auditory ossicles; Temp. pr.-mesenchymal concentration where primordium of temporal bone is taking shape.



Semischematic diagram showing ear mechanism at term. The cochlea has been turned mesiad to show its spiral course.

تكوين التيه السباتى فى أذن الإنسان

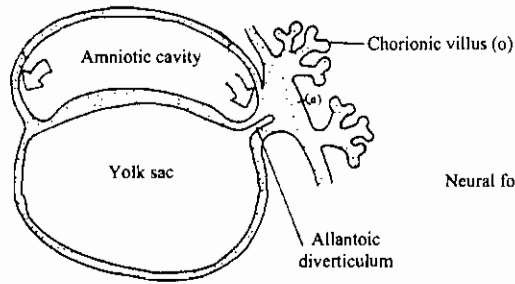


Development of the membranous labyrinth in human embryos. (After Streeter, *Am. J. Anat.*, vol. 6, 1906.) (A) 6 mm, lateral view. (B) 9 mm, lateral view. (C) 11 mm, lateral view. (D) 13 mm, lateral view. (E) 20 mm, lateral (F) 30 mm, lateral view. (G) 30 mm, medial aspect. (H) Outline of head of 30-mm embryo to show position and relations of developing inner ear.

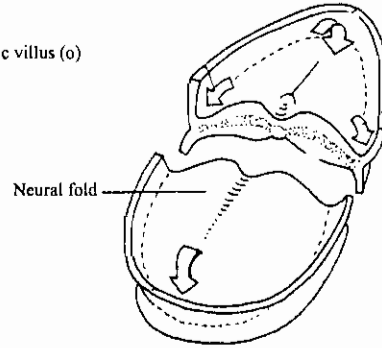
تكوين ثنية الرأس والذيل في جنين الإنسان
 Formation of human head and tail folds

HEAD AND TAIL FOLDS

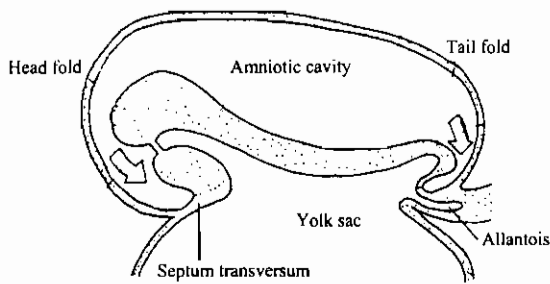
Stage 8



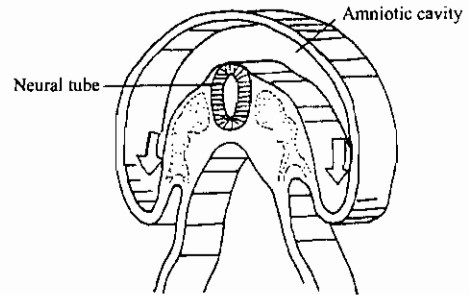
Stage 8



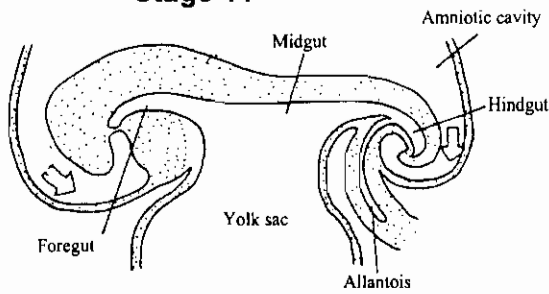
Stage 10



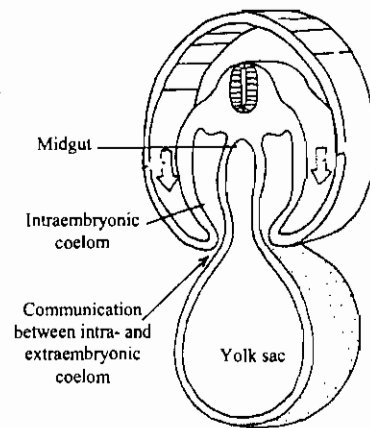
Stage 10



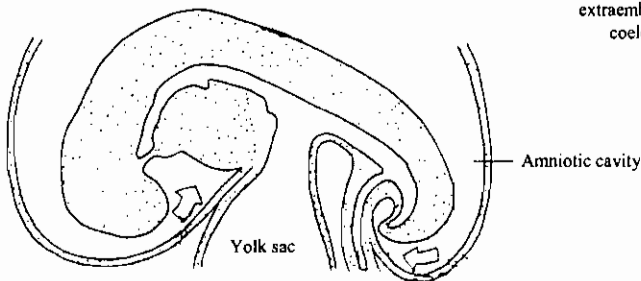
Stage 11



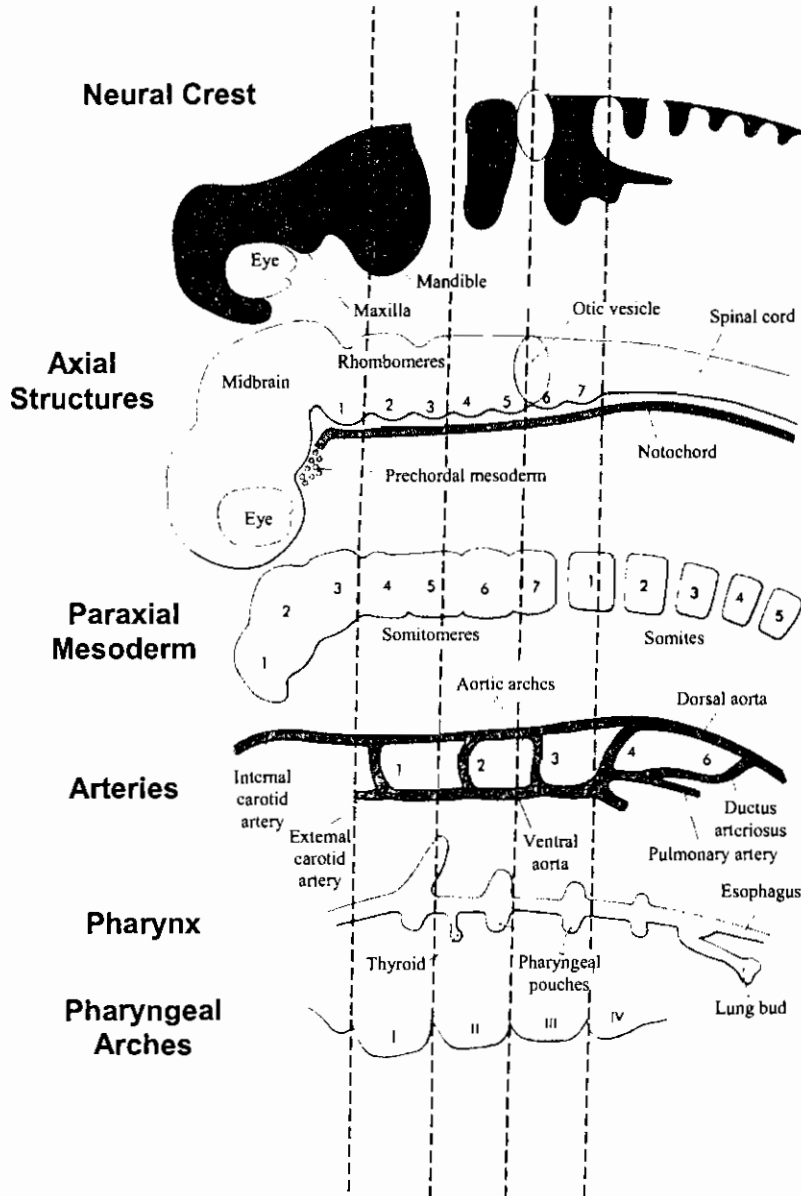
Stage 11



Stage 12



منظر جانبي يوضح تركيب الرأس والبلعوم في جنين إنسان

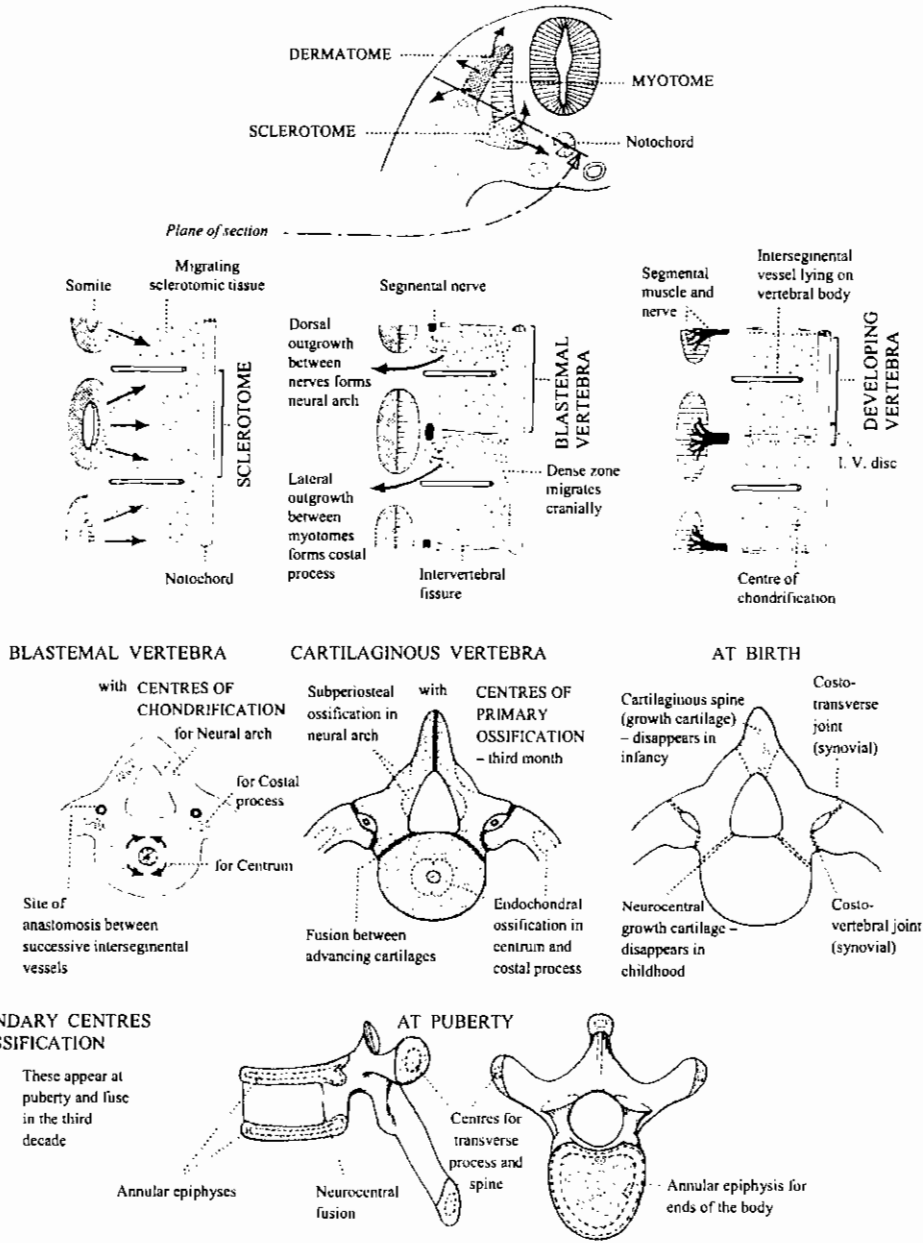


Lateral view of the organization of the head and pharynx of a 30-day-old human embryo, with individual tissue components separated but in register through the dashed lines.

(Based on studies by Noden [1991].)

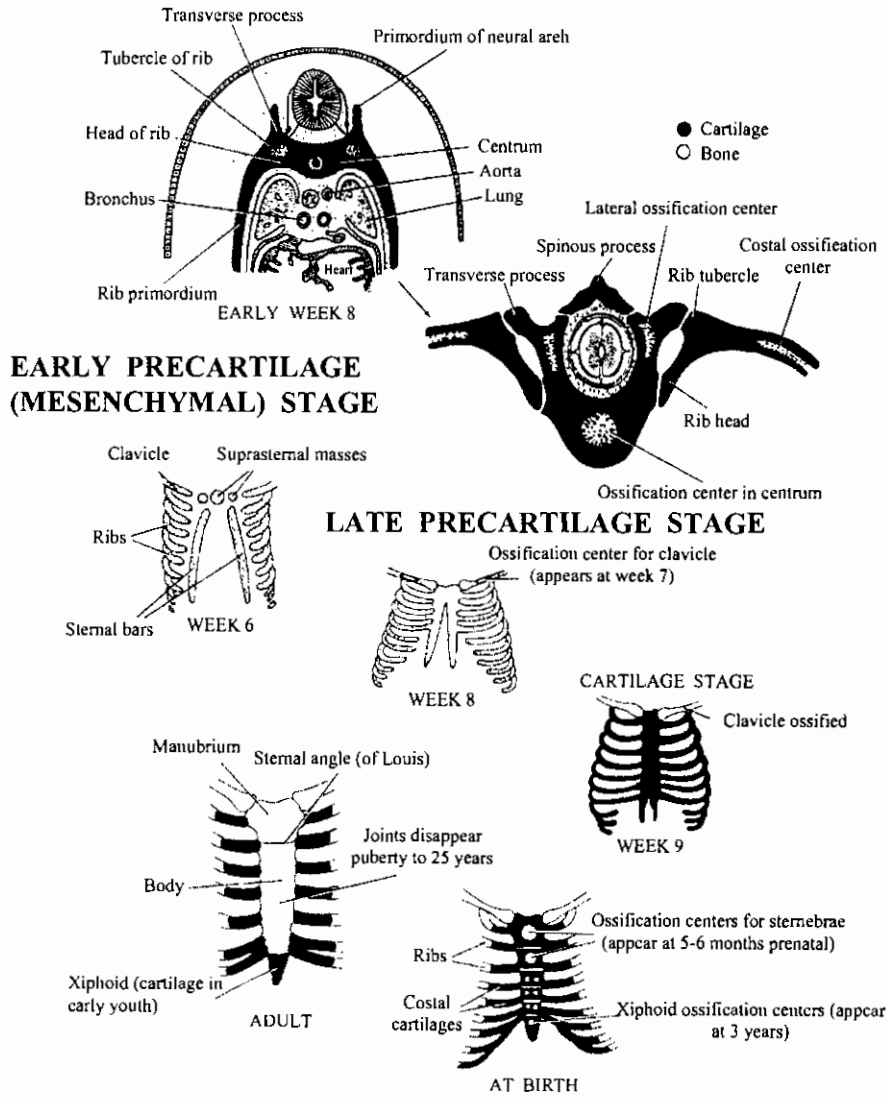
تكوين الفقرات

Development of the Vertebrae

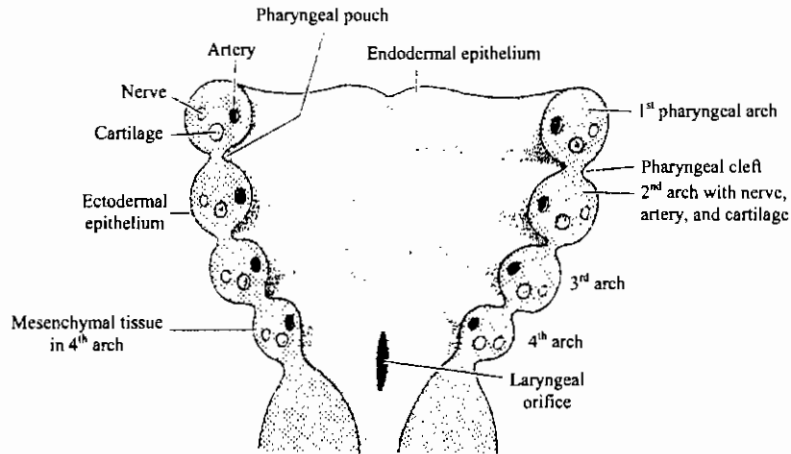


تكوين القفص والضلع

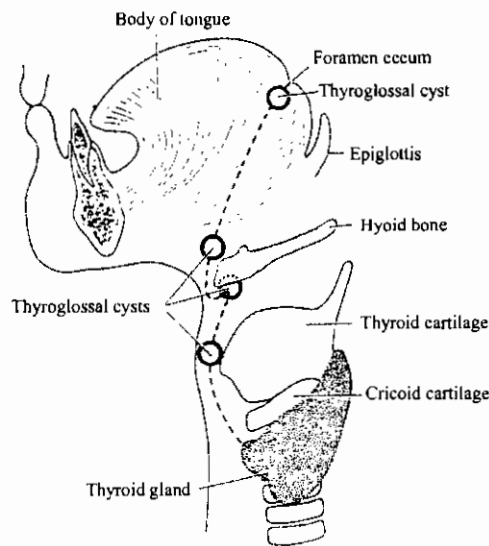
DEVELOPMENT OF STERNUM AND RIBS



رسوم تخطيطية توضح الأقواس البلعومية والحوصلات الدرقية اللسانية

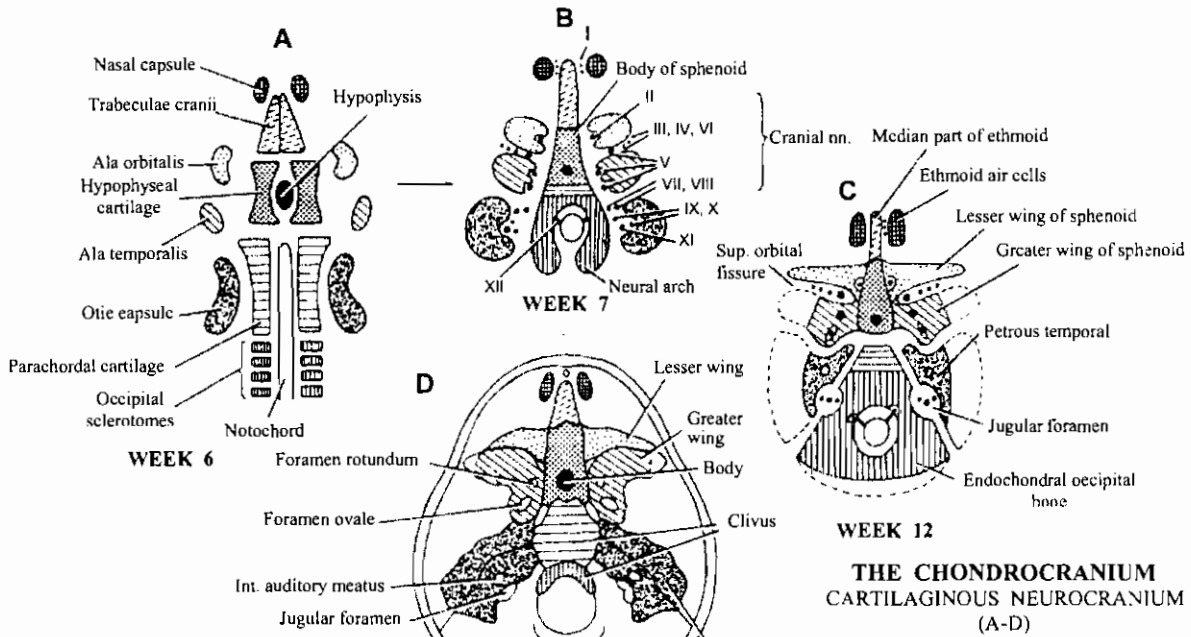


Schematic drawing of the pharyngeal arches. Each arch contains a cartilaginous component, a nerve, an artery, and a muscular component.



Schematic drawing indicating the localization of the thyroglossal cysts. These cysts, most frequently found in the thyroid region, are always located close to the midline.

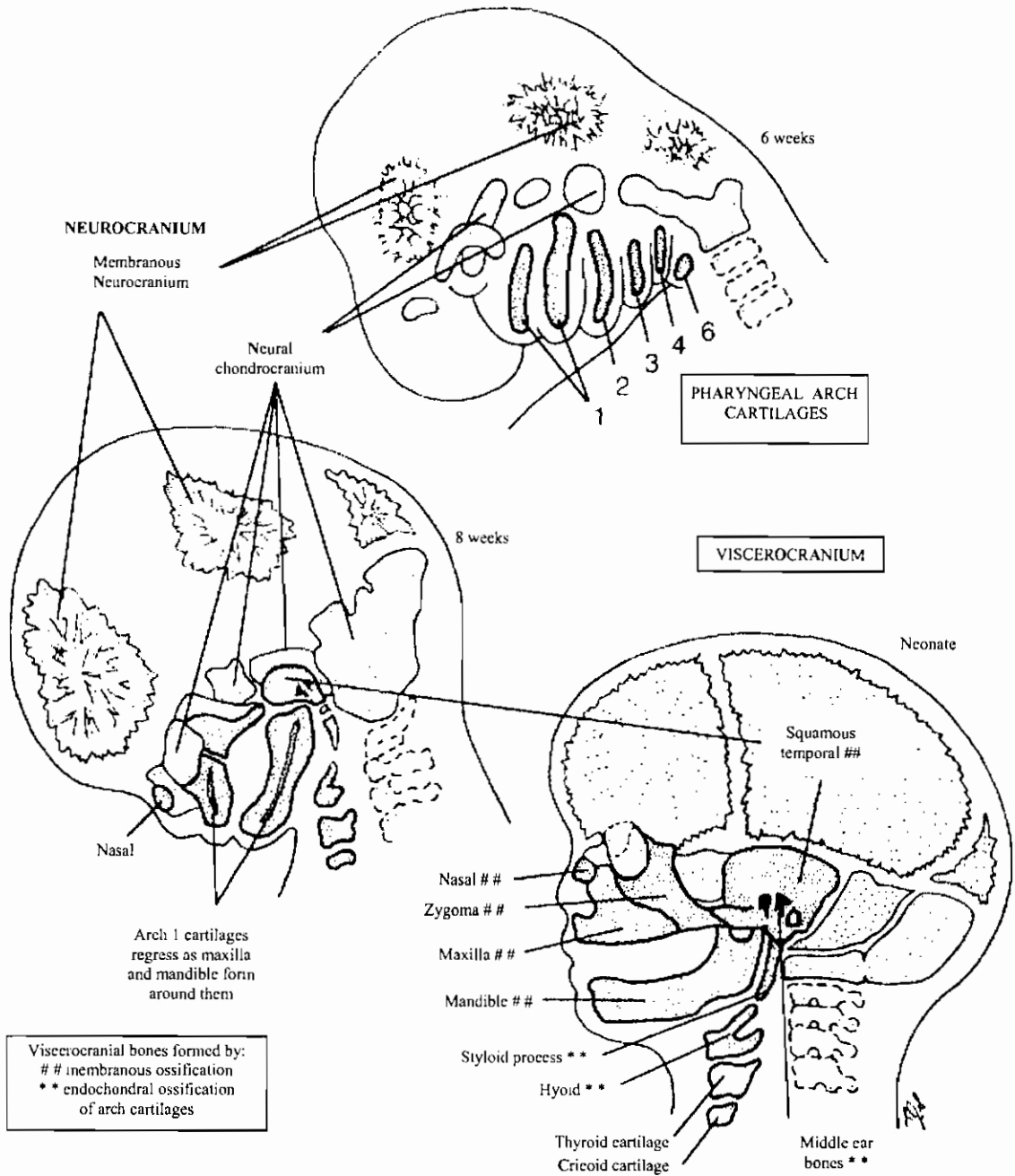
تكوين الجمجمة في الإنسان
Human Skull development



- Viscerocranium
- Chondrocranium
- ◐ Membranous neurocranium

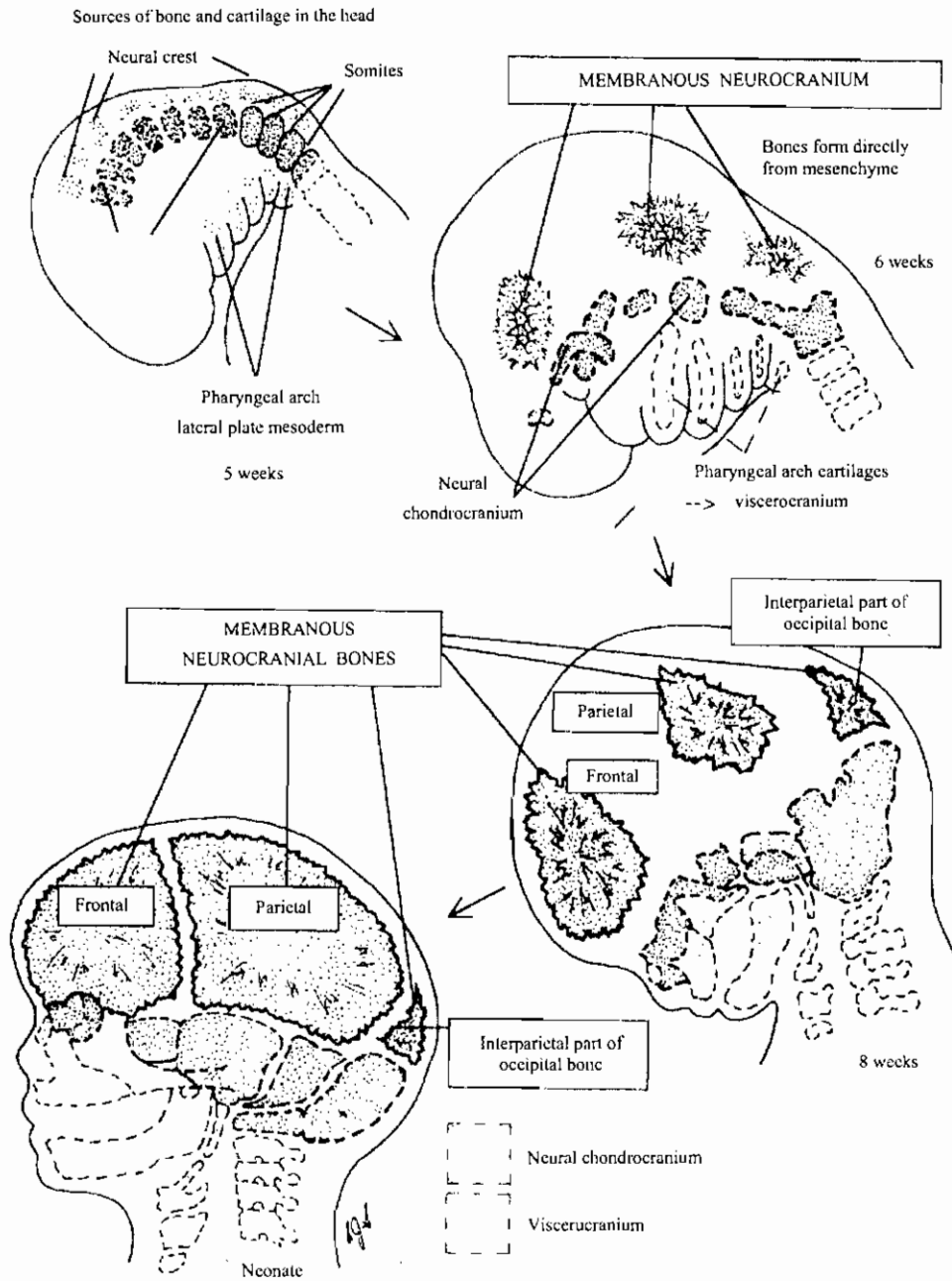
تكوين الجمجمة الحشوية من الأقواس في الإنسان

Skeletal System



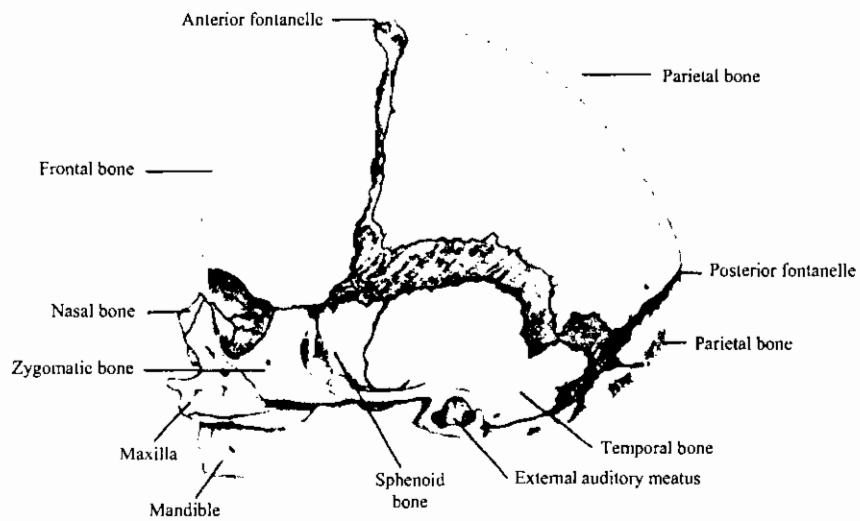
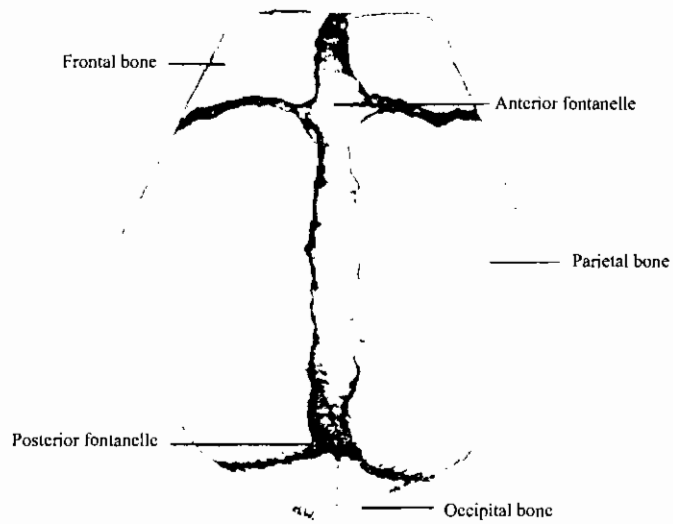
Formation of the viscerocranium from arches in man

مناطق الجمجمة وتكوين الجمجمة العصبية البين نسيجية في الإنسان
Skeletal System of man



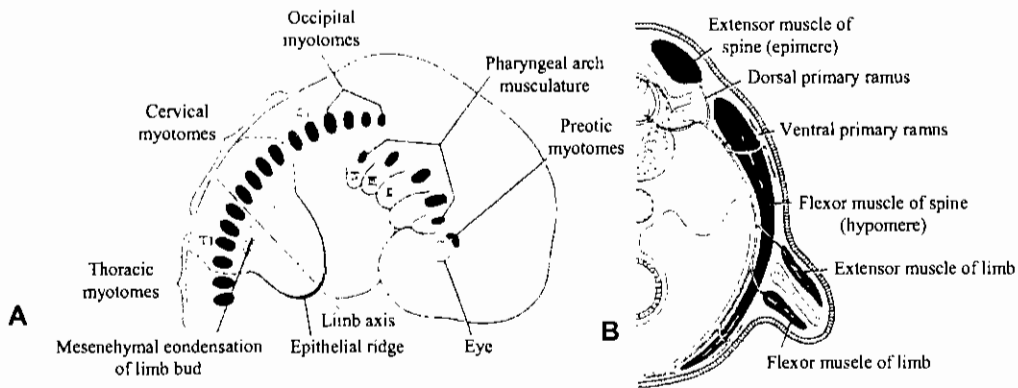
Regions of the skull and formation of intramembranous neurocranium.

العظام الأدمية

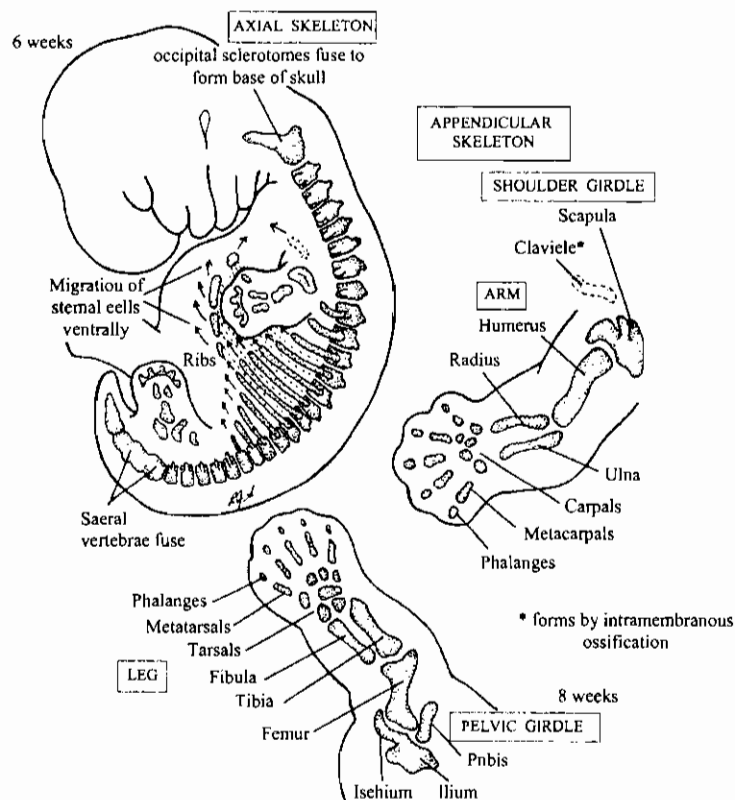


Individual dermal bones of a term fetus do not quite meet and membrane-covered spaces, known as fontanelles. Exist between them. (From Francis, C. C.: Introduction to human anatomy, ed. 6, St. Louis, 1968, The C. V. Mosby Co.)

تكوين الطرف في الإنسان



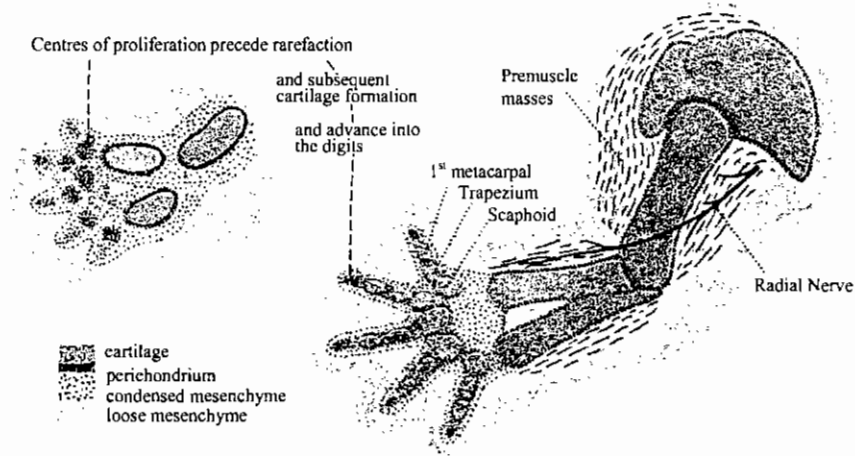
A, Schematic representation of the myotomes in the head, neck, and thoracic region of a 7-week embryo. Note the localization of the preotic and occipital myotomes and the condensation of mesenchyme at the base of the limb bud **B**, Transverse section through the region of attachment of the limb bud. Note the dorsal (extensor) and ventral (flexor) muscular components of the limb.



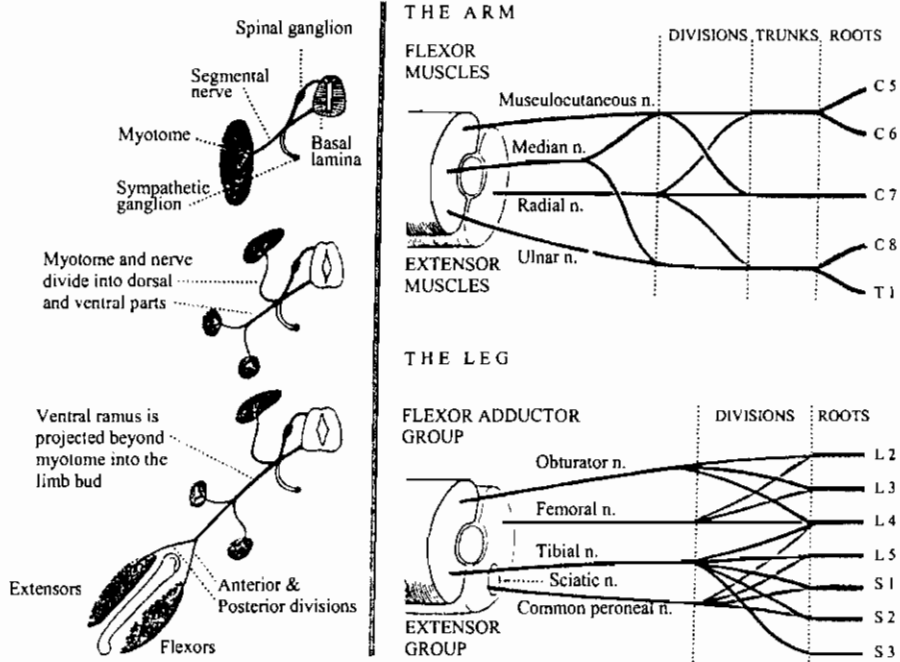
Formation of bones of the limbs and appendicular girdles

هيكل الطرف الأمامي الأولى

Early Fore-limb Skeleton

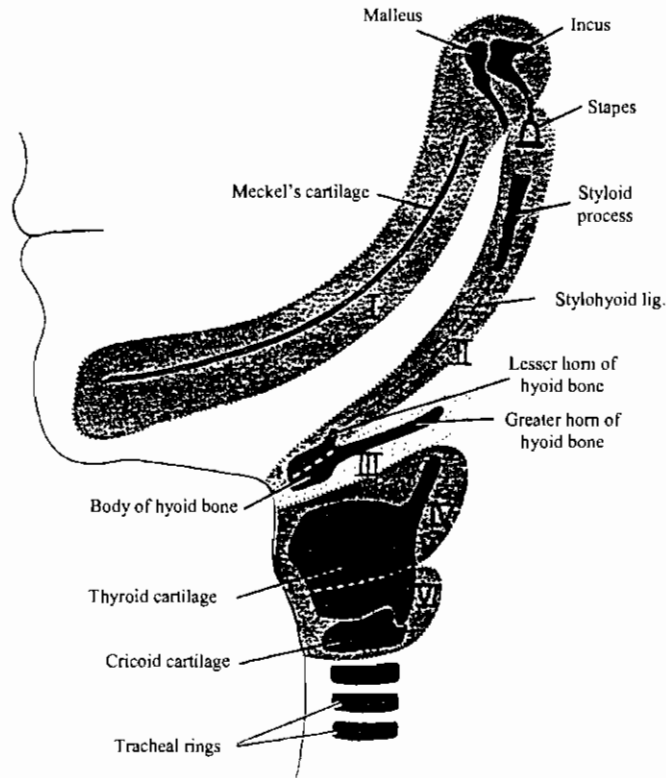
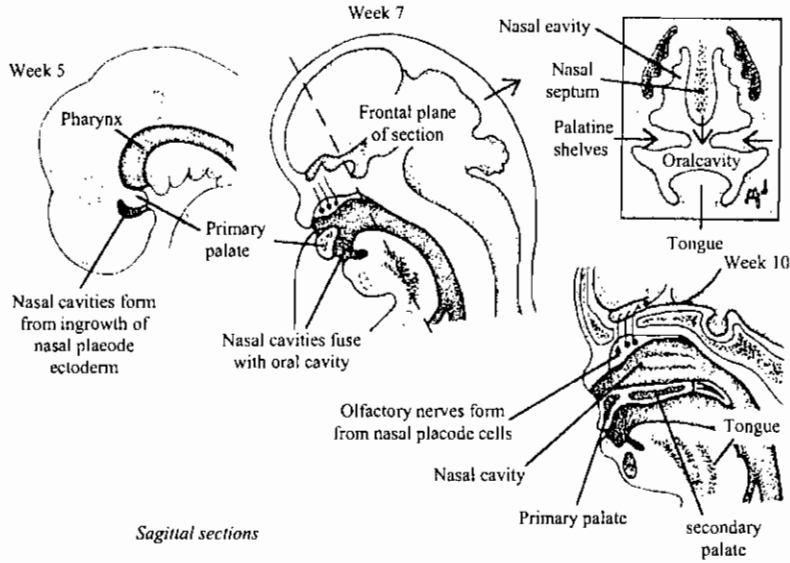


Plexuses and Muscle Innervation



تكوين عضو الشم والغضاريف الحشوية في الإنسان

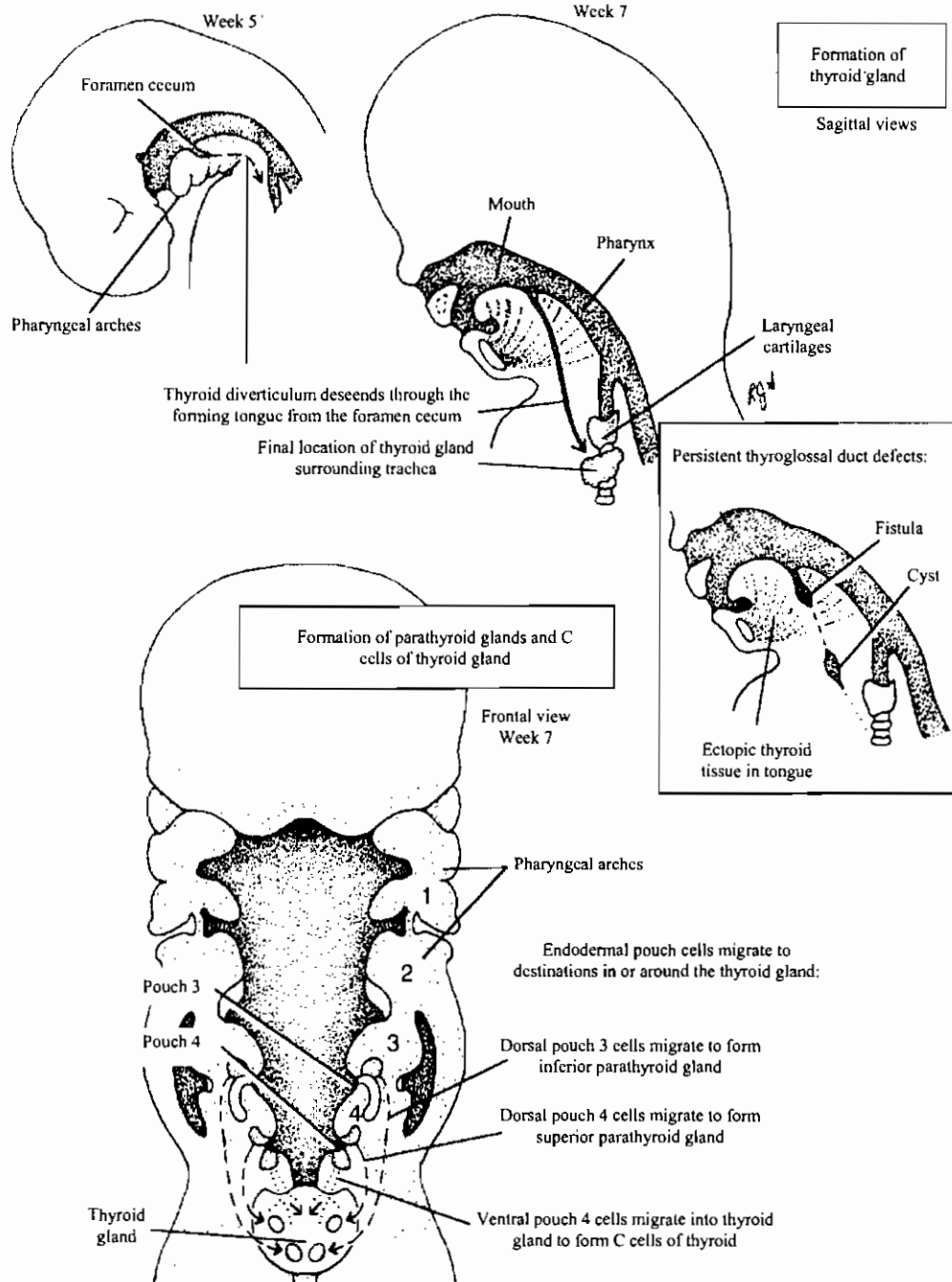
NASAL DEVELOPMENT



Drawing showing the definitive structures formed by the cartilaginous components of the various pharyngeal arches.

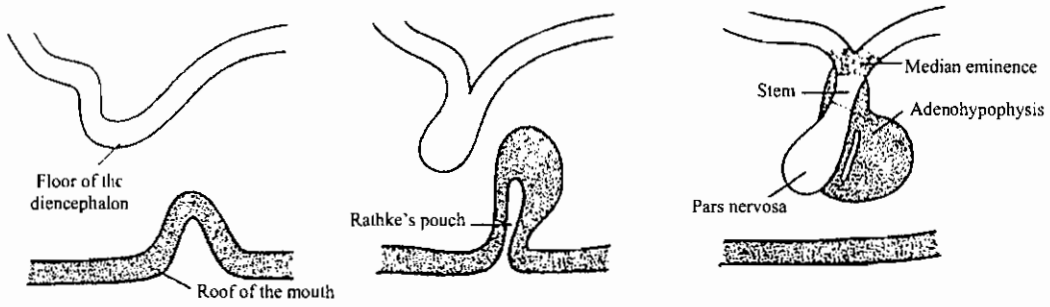
تكوين الغدة الدرقية والجار درقية في الإنسان

Thyroid and parathyroid gland embryogenesis



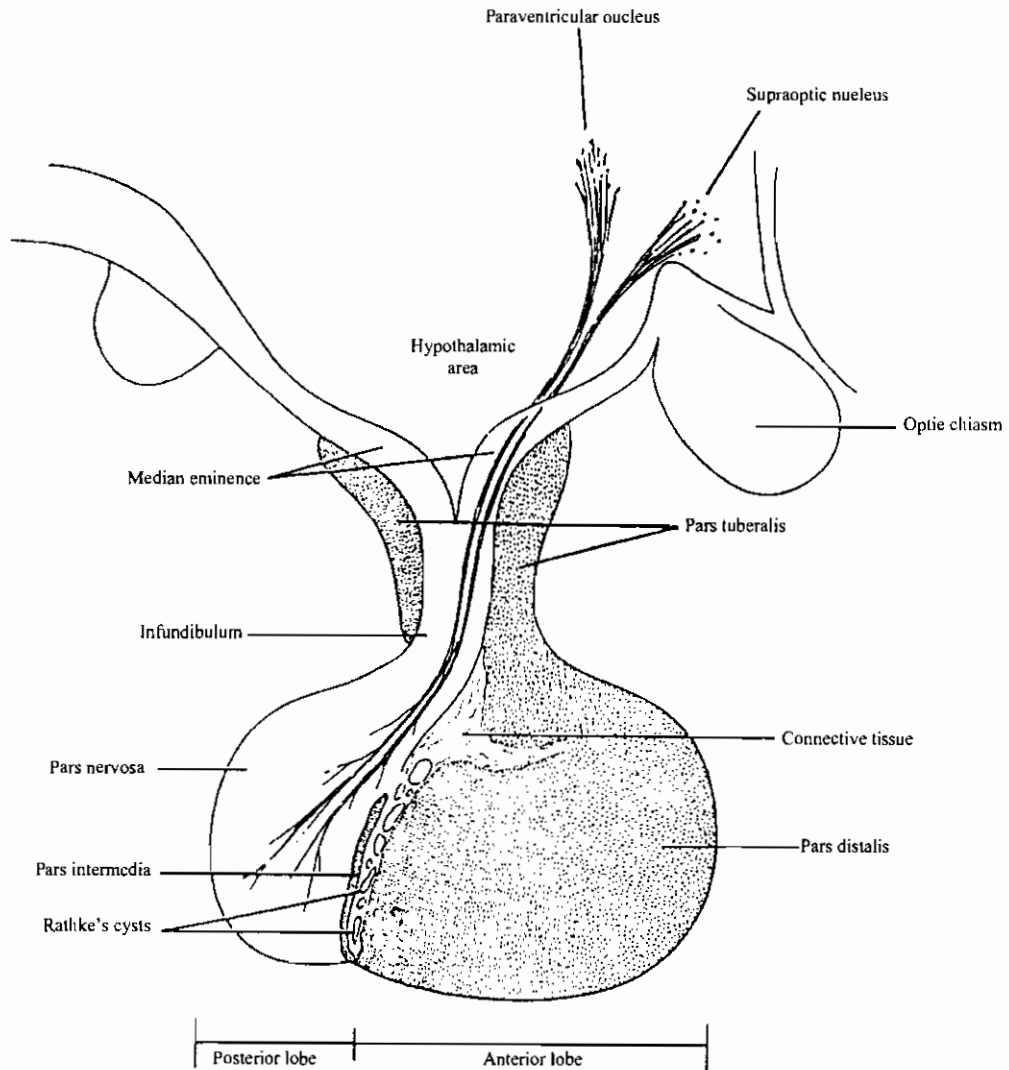
تكوين الغدة النخامية

Development of the pituitary gland



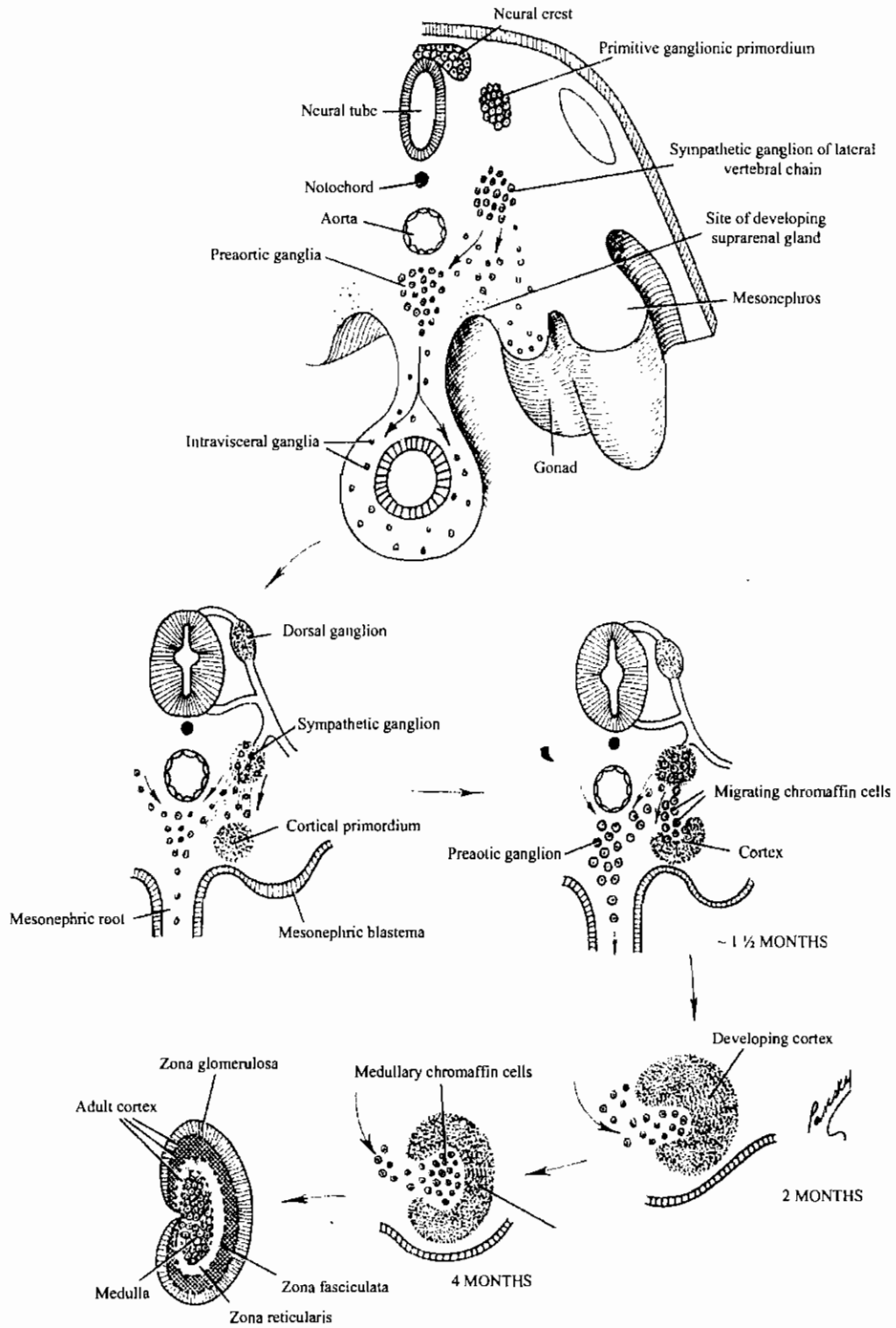
تركيب الغدة النخامية وعلاقتها بتحت المهاد

Structure of the pituitary and its relation to the hypothalamus

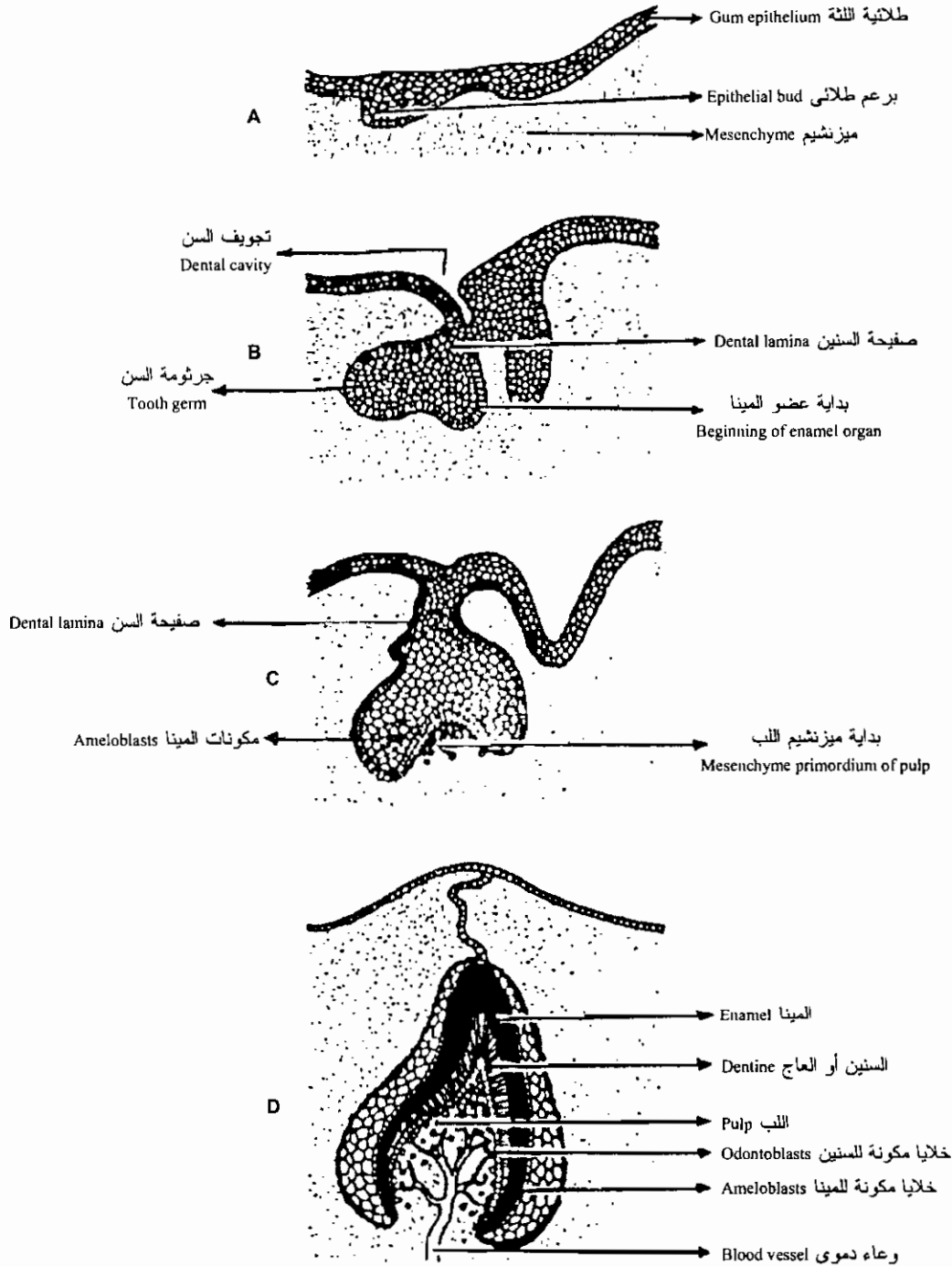


تكوين الغدة الجار كلوية في الإنسان

Developing suprarenal (adrenal) Gland



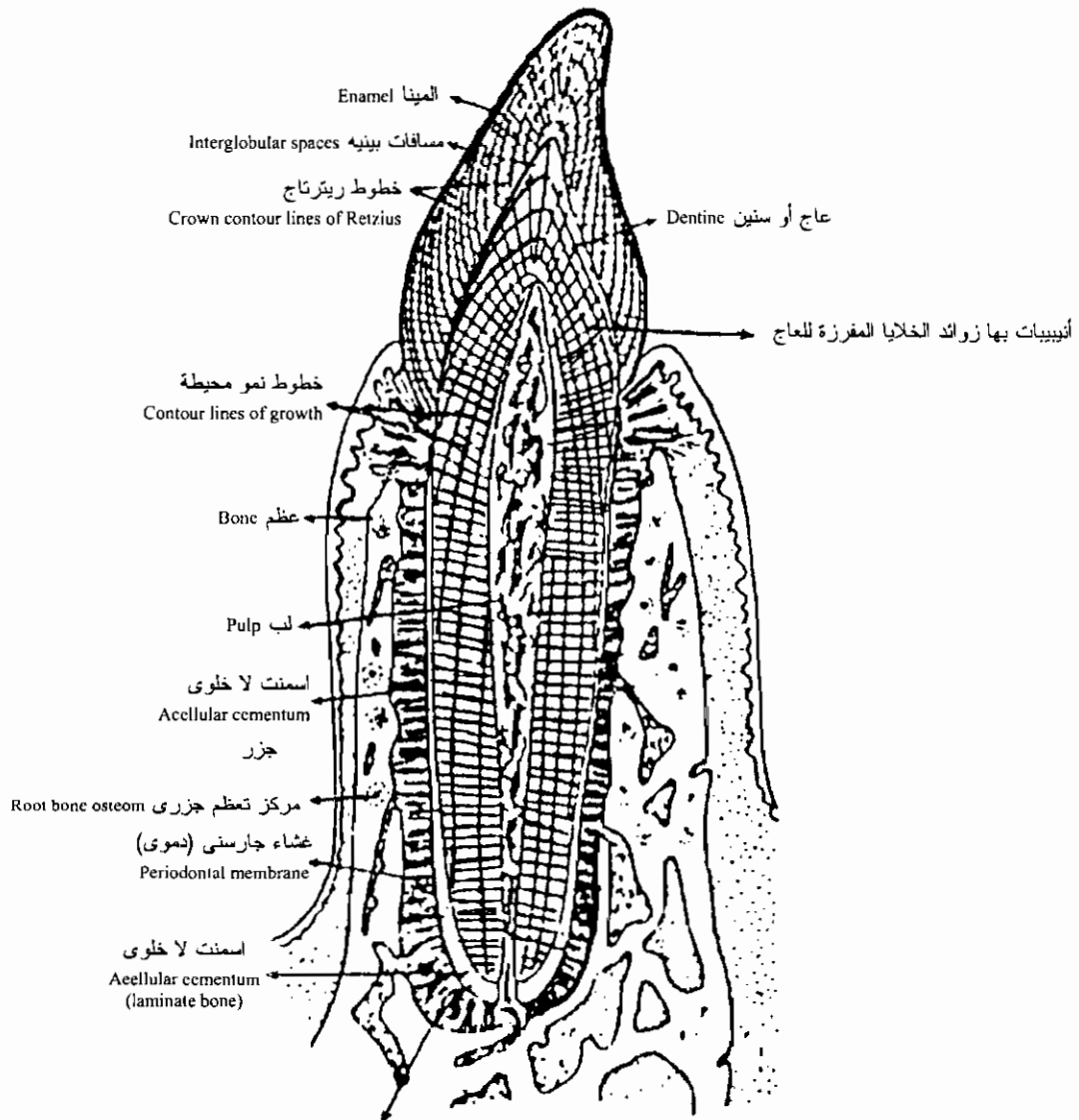
تكوين السن في الثدييات



Development of tooth. Epithelial bud, A, develops into a cup-shaped structure, the enamel organ, which gives rise to the crown of the tooth. Blood vessels in the pulp supply materials to the odontoblasts which is deposited on the inner surface of the enamel organ.

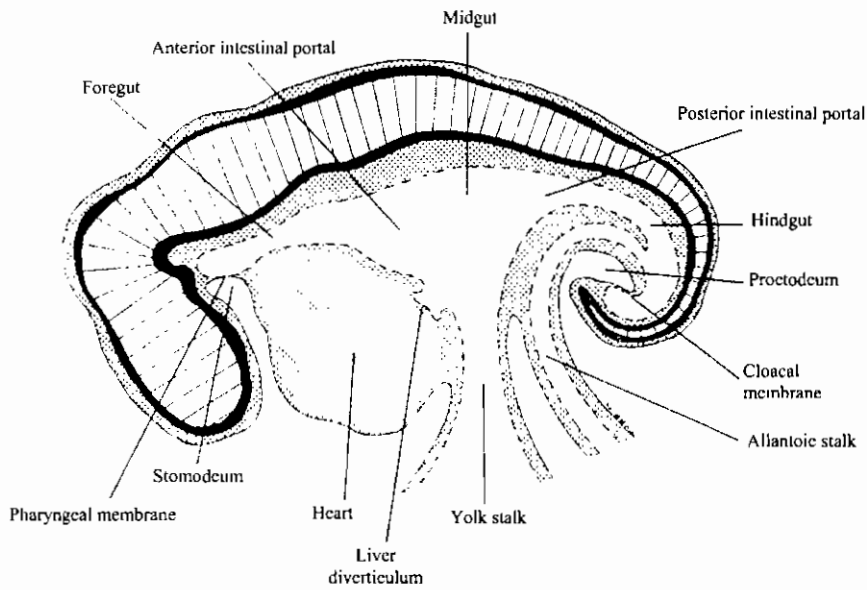
ق. ط. فى سن حيوان ثديى ماراً باللثة يظهر تركيب السن الكامل

Section of mammalian tooth set in the jaw (after Hom. 1957)

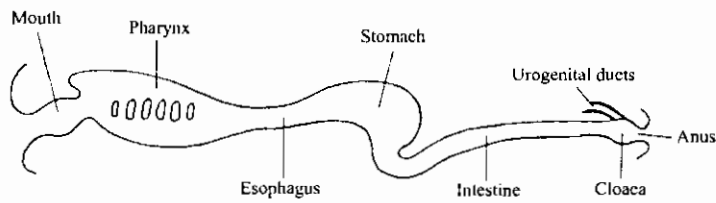


الياف كولاجين ممتدة داخل العظم
Collogenus fibers which continue
into bone as Sharpey's fibers

بداية تكوين المعى فى جنين الثدييات



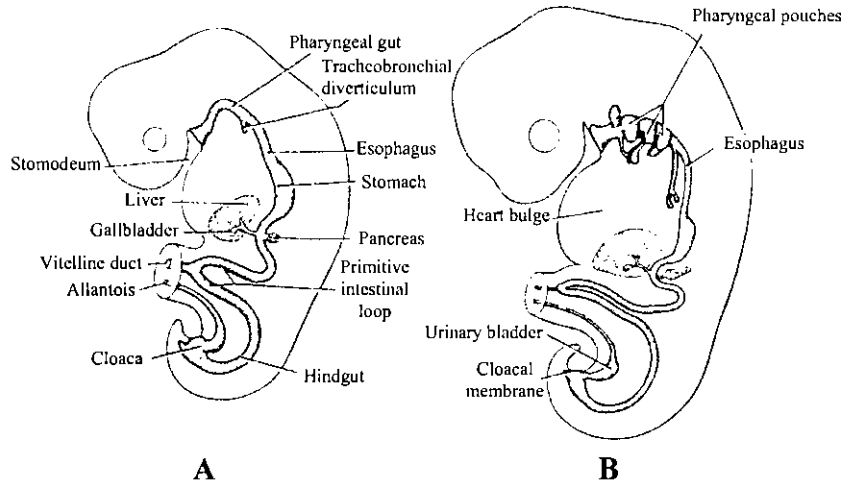
Schematic longitudinal section of an amniote embryo, showing the architecture of the embryonic gut.



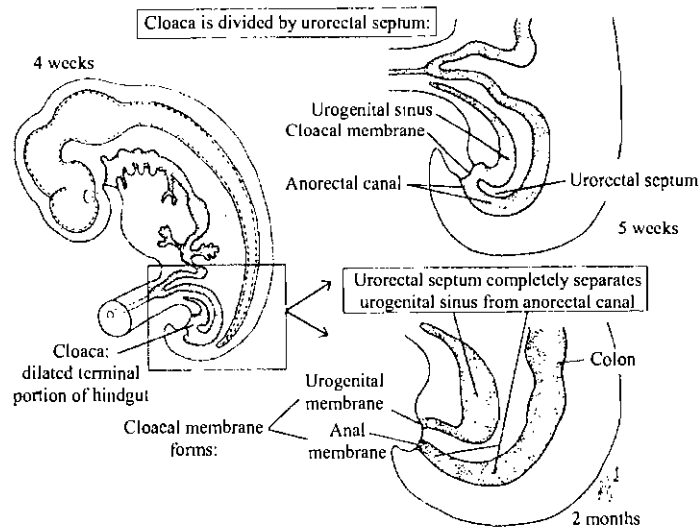
Schematic representation of the subdivisions of the alimentary canal. (All accessory parts and derivatives omitted.)

الأجزاء الأساسية للمعى وتميز المعى الخلفى

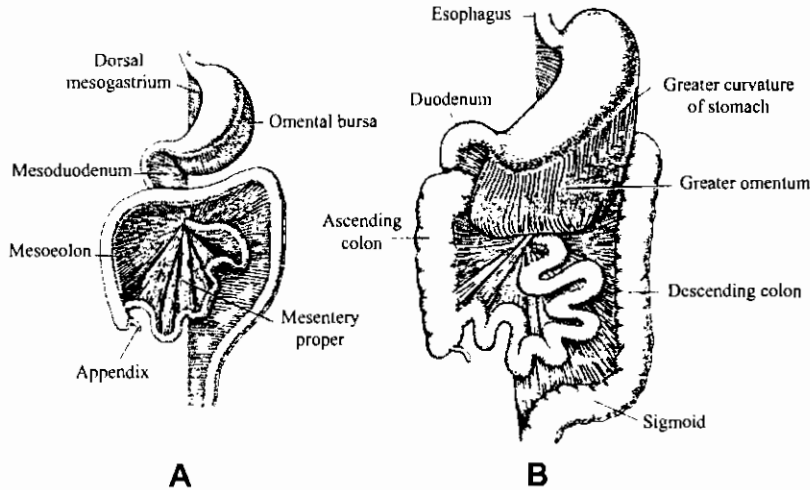
Development of the rectum and anal canal



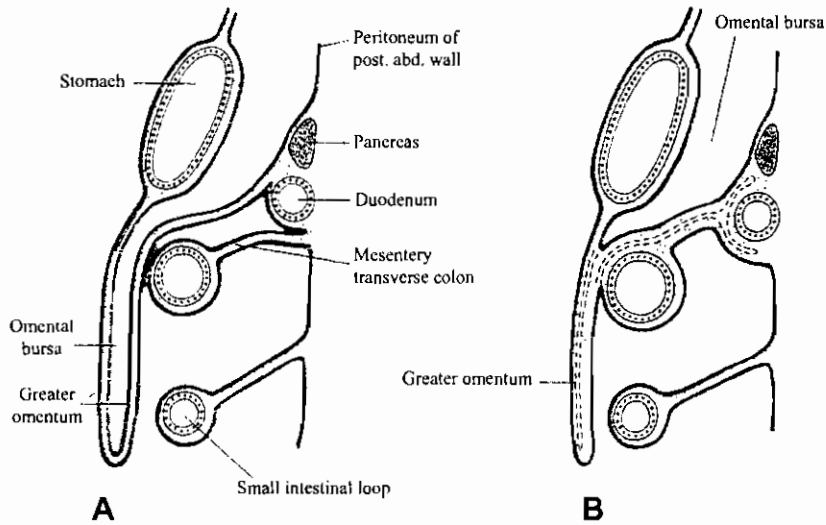
Schematic drawings of embryos during the 4th and 5th weeks of development to show the formation of the gastrointestinal tract and the various derivatives originating from the endodermal germ layer.



تكوين مساريقا الأمعاء

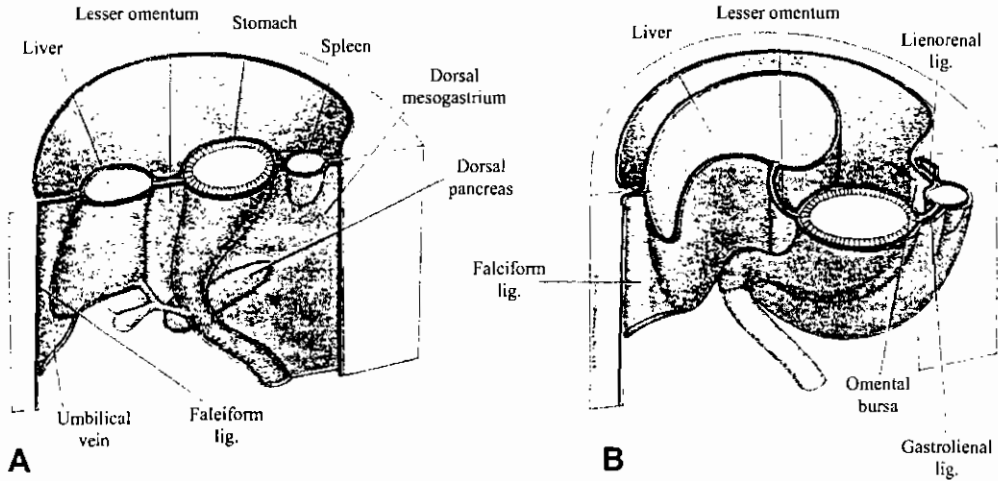


A, Schematic drawing of the dorsal mesentery at the end of the 3rd month. The dorsal mesogastrium bulges out on the left side of the stomach, where it forms the omental bursa. B, The greater omentum hangs down from the greater curvature of the stomach in front of the transverse colon.

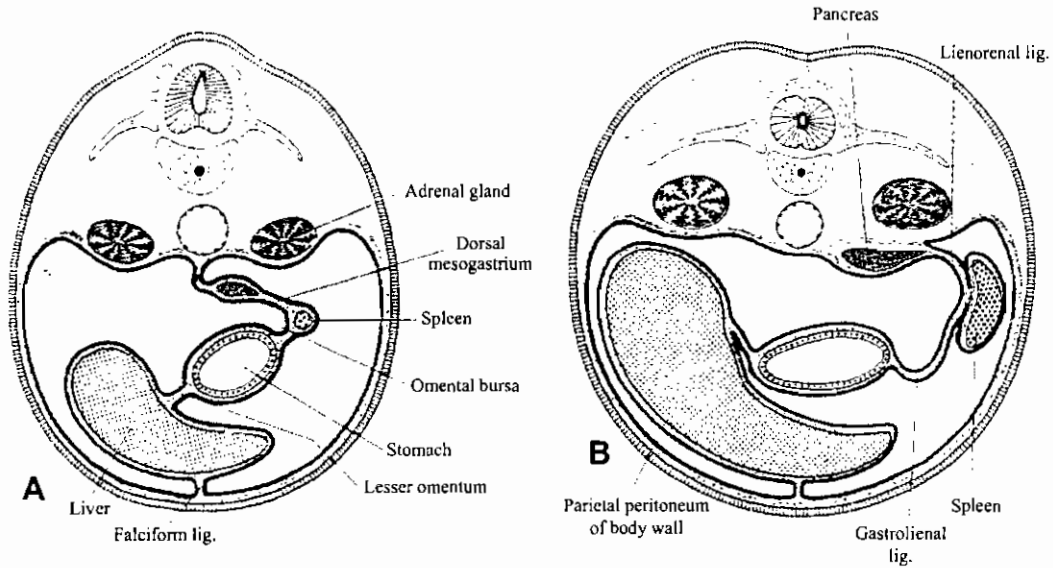


A, Schematic sagittal section showing the relationship between the greater omentum, stomach, transverse colon, and small intestinal loops at 4 months. The pancreas and duodenum have already acquired a retroperitoneal position. B, Similar section as in A, in the newborn. The leaves of the greater omentum have fused with each other and with the transverse mesocolon. The transverse mesocolon covers the retroperitoneally located duodenum.

قطاعات عرضية في منطقة المعدة في مراحل جنينية مختلفة توضح الغشاء البريتوني

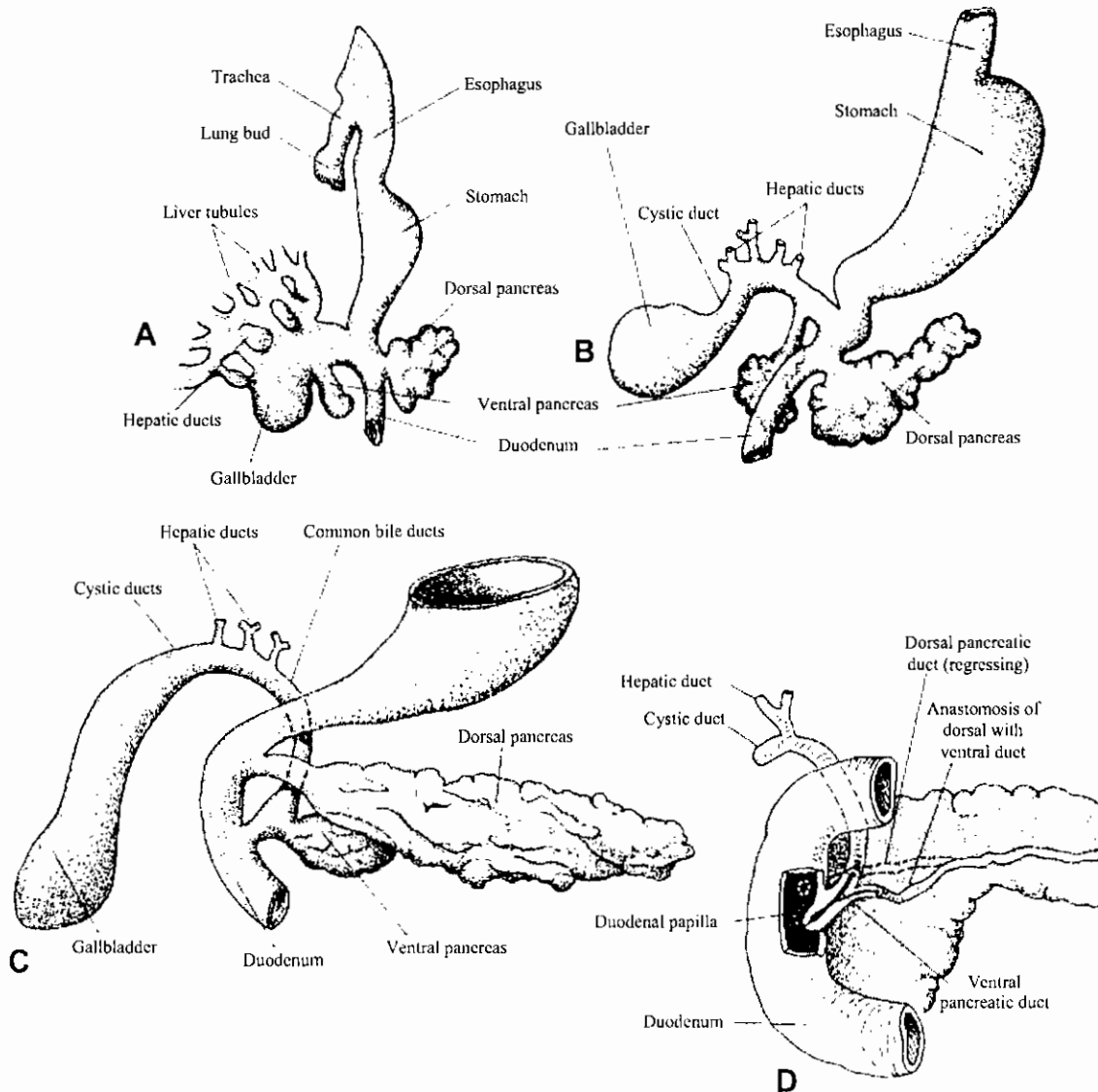


A, Drawing of the positions of the spleen, stomach, and pancreas at the end of the 5th week. Note the position of the spleen and pancreas in the dorsal mesogastrium. B, Position of spleen and stomach at the 11th week: Note the formation of the omental bursa or lesser peritoneal sac.



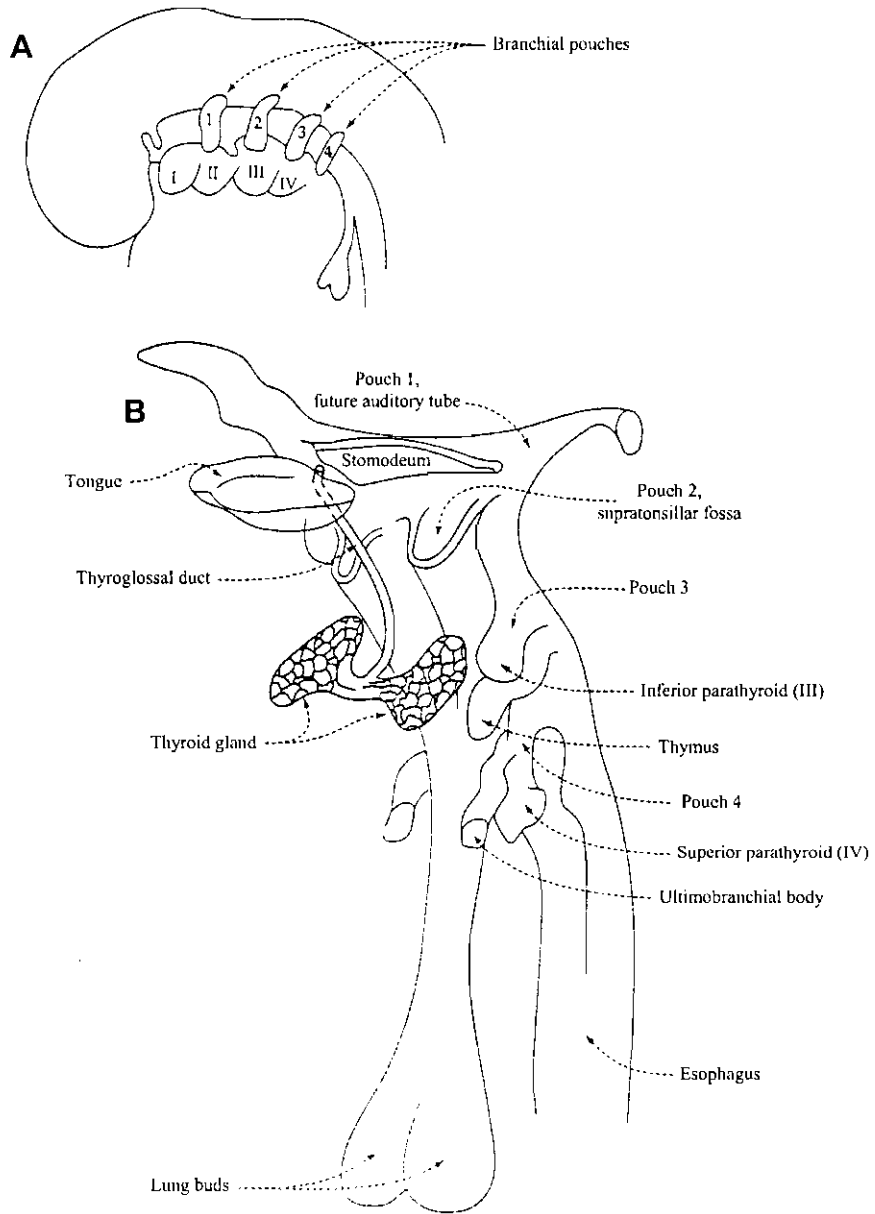
Diagrammatic transverse sections through the region of the stomach, liver, and spleen, showing the formation of the lesser peritoneal sac, the rotation of the stomach, and the position of the spleen and tail of the pancreas between the two leaves of the dorsal mesogastrium. With further development, the pancreas obtains a retroperitoneal position.

تكوين الكبد والبنكرياس في الإنسان



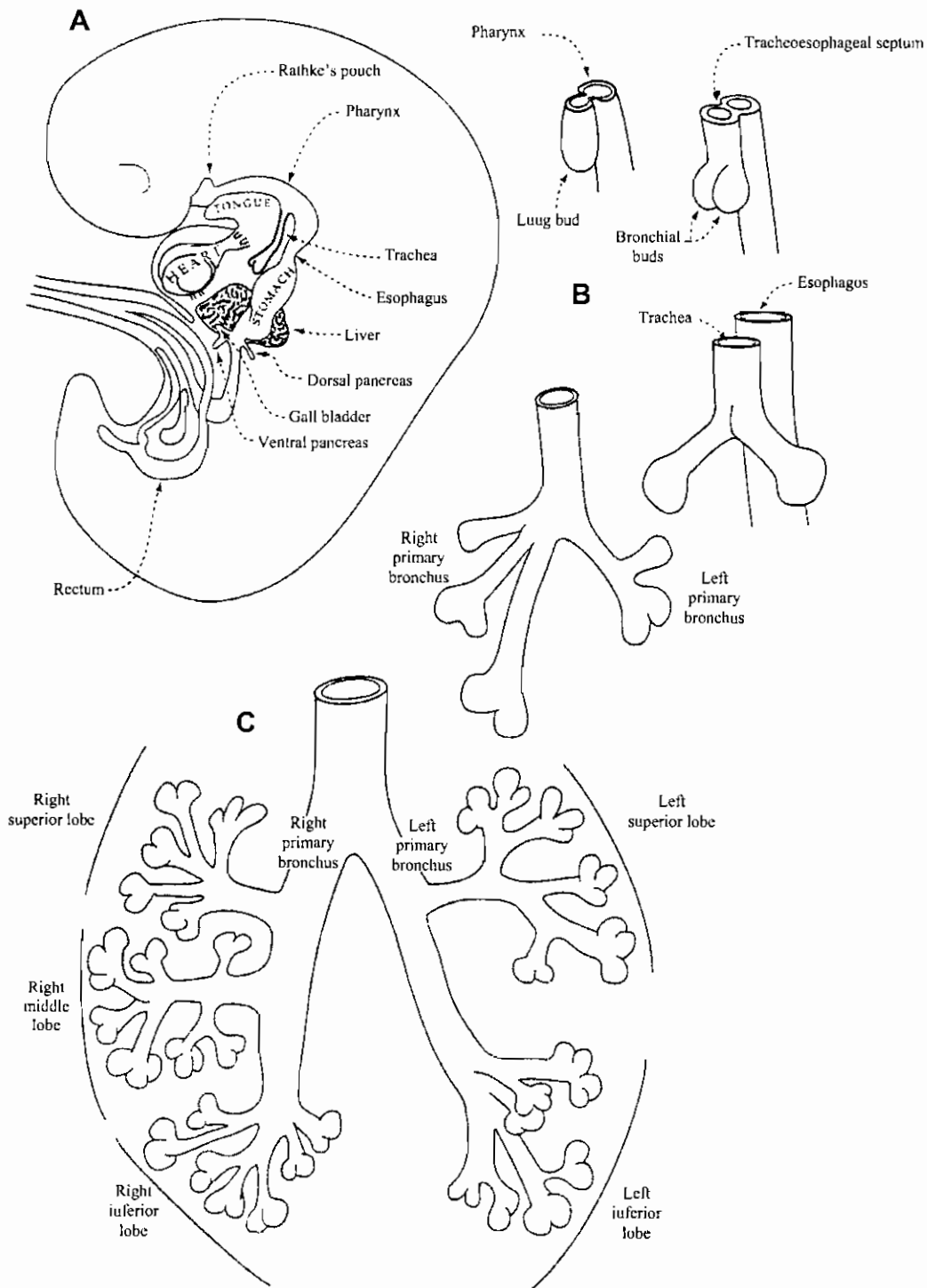
Development of hepatic and pancreatic primordia. All diagrams are viewed from the ventral aspect. (A) Semischematic diagram based in part on Thyng's reconstructions of a 5.5-mm pig embryo. This is comparable to a human embryo early in the fifth week. (B) Reconstruction from a 9.4-mm pig embryo. This is comparable to a human embryo of 7 weeks. (C) Schematized drawing equivalent to a 20-mm pig embryo or a human embryo of 7 weeks. (D) Manner in which common bile duct and pancreatic duct become confluent and discharge through the duodenal papilla.

بداية تكوين الجهاز التنفسي
The Respiratory System

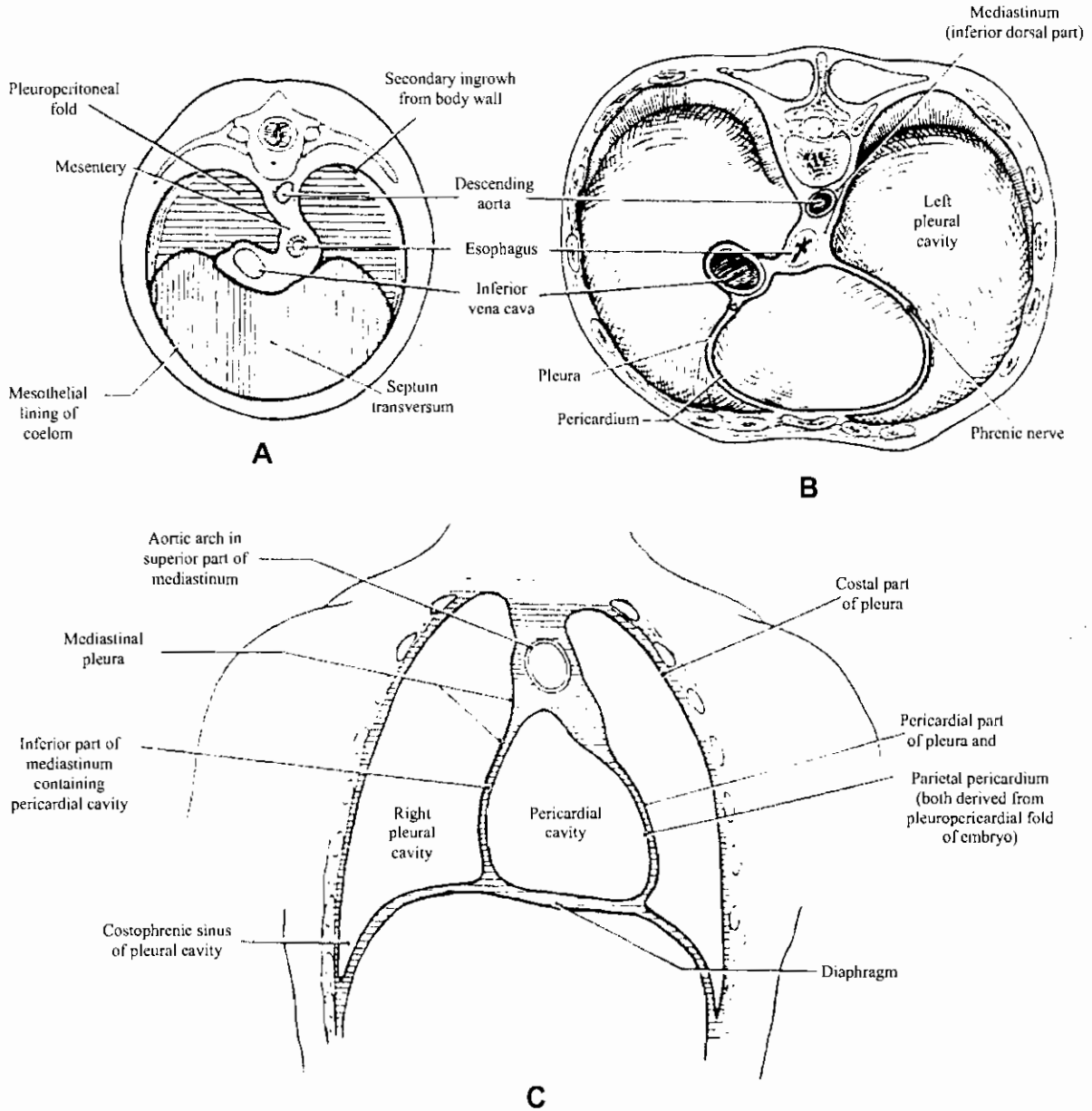


مناظر بطنية توضح تكوين الجهاز التنفسي في مراحل مختلفة من أجنة خنزير

Development of the respiratory system of pig embryo

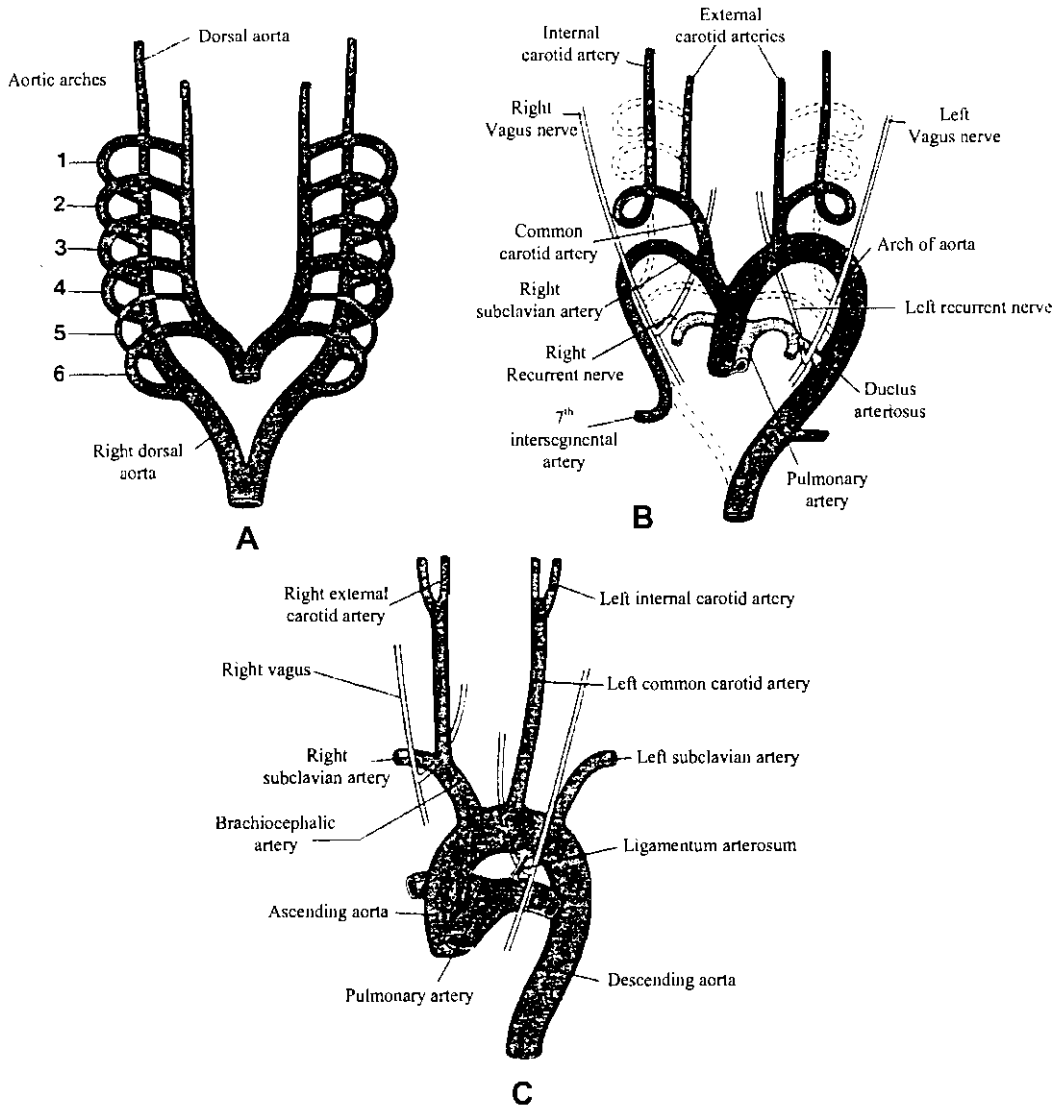


قطاعات عرضية ومنظر أمامي لمنطقة الحجاب الحاجز



Diaphragm in embryo and in adult. (A) Diagram indicating embryological origin of various regions of diaphragm. (Modified from Broman.) (B) Thoracic face of adult diaphragm. (Modified from Rauber-Kopsch.) (C) Relations of diaphragm as seen in a frontal section of adult body. (Modified from Rauber-Kopsch.)

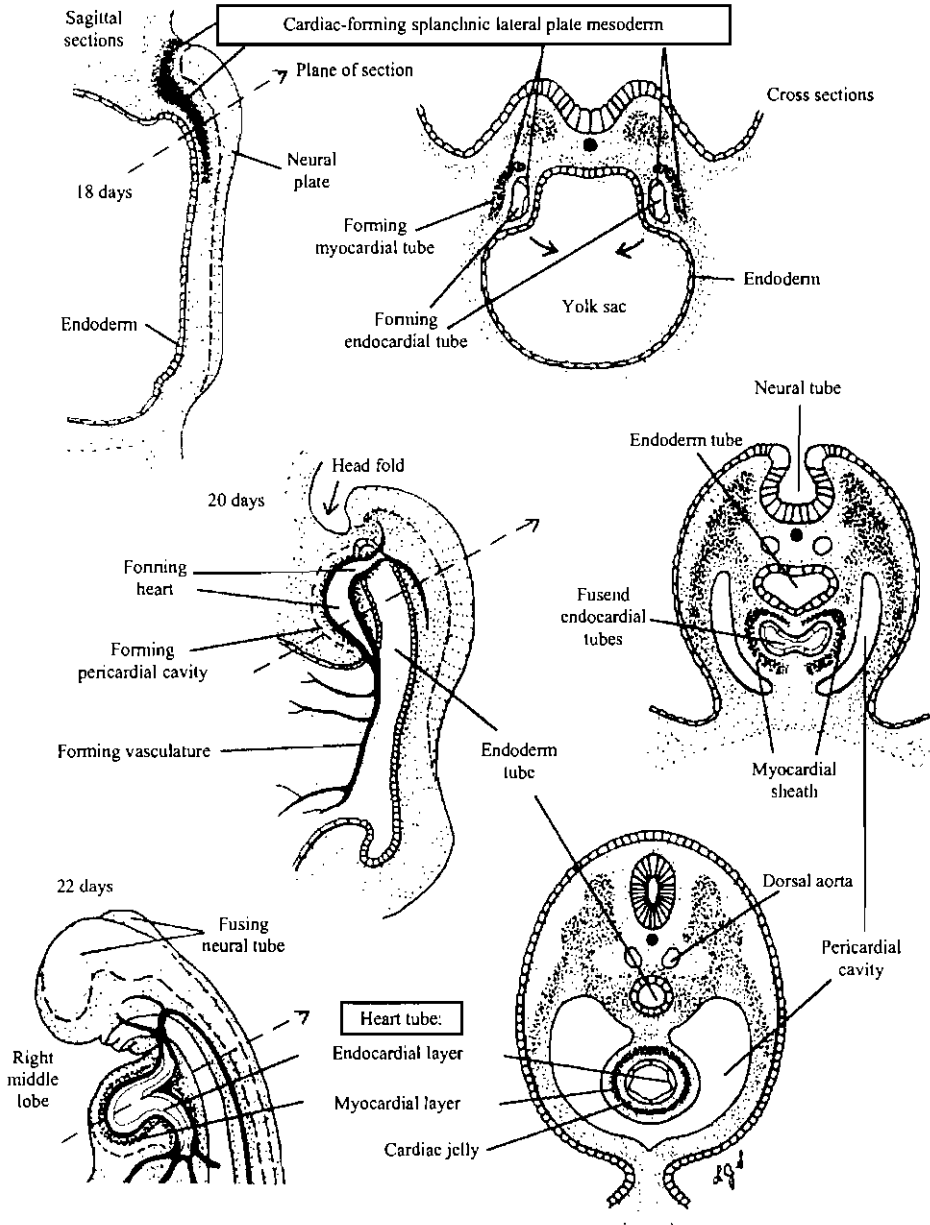
الأقواس الأورطية وتطورها إلى الشرايين الرئيسية المحيطة بالقلب في الثدييات



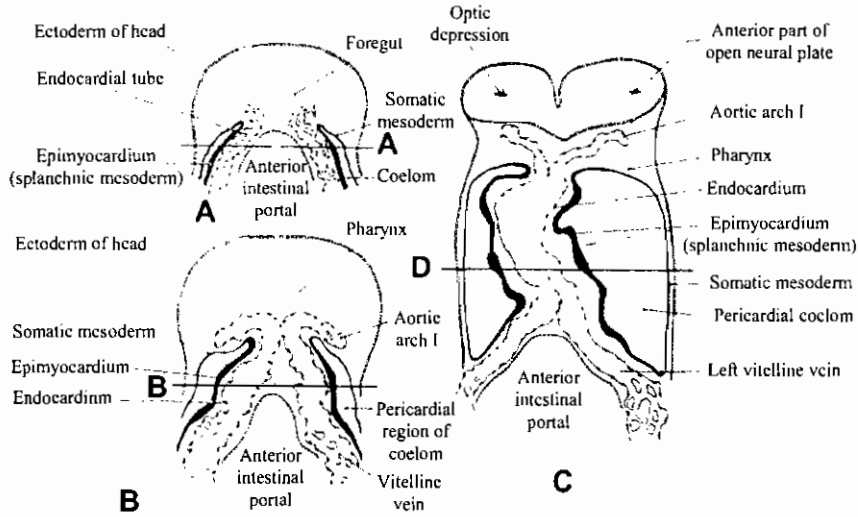
A, Diagram of the aortic arches and dorsal aortas before transformation into the definitive vascular pattern. B, Diagram of the aortic arches and dorsal aortas after the transformation. The obliterated components are indicated by broken lines. Note the patent ductus arteriosus and the position of the seventh intersegmental artery on the left. C, The great arteries in the adult. Compare the distance between the place of origin of the left common carotid artery and the left subclavian in B and C. After disappearance of the distal part of the sixth aortic arch and the fifth arch on the right, the right recurrent laryngeal nerve hooks around the right subclavian artery. On the left the nerve remains in place and hooks around the ligamentum arteriosum.

المراحل الأولية لتكوين أنابيب القلب في الإنسان

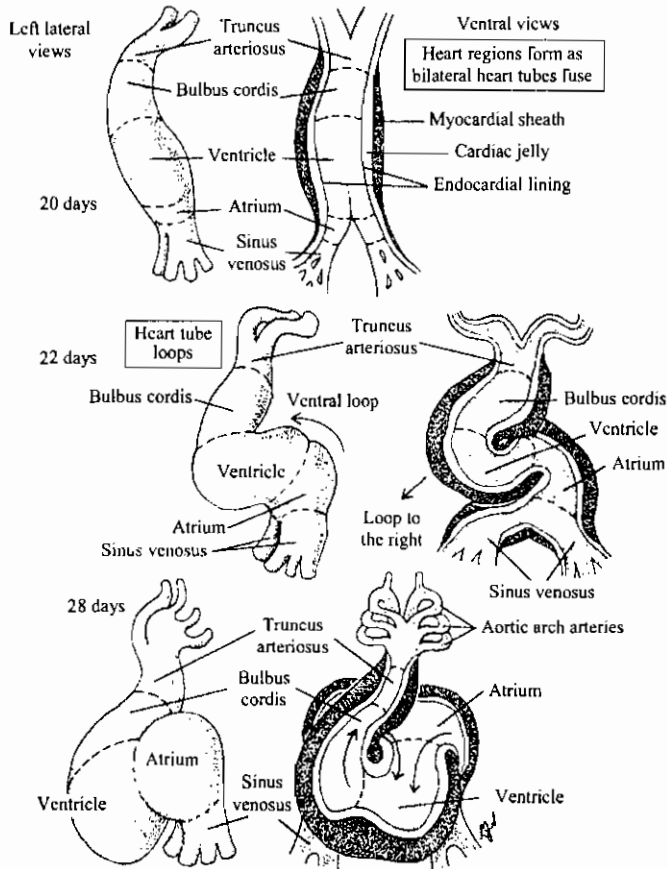
Formation and fusion of bilateral heart tubes



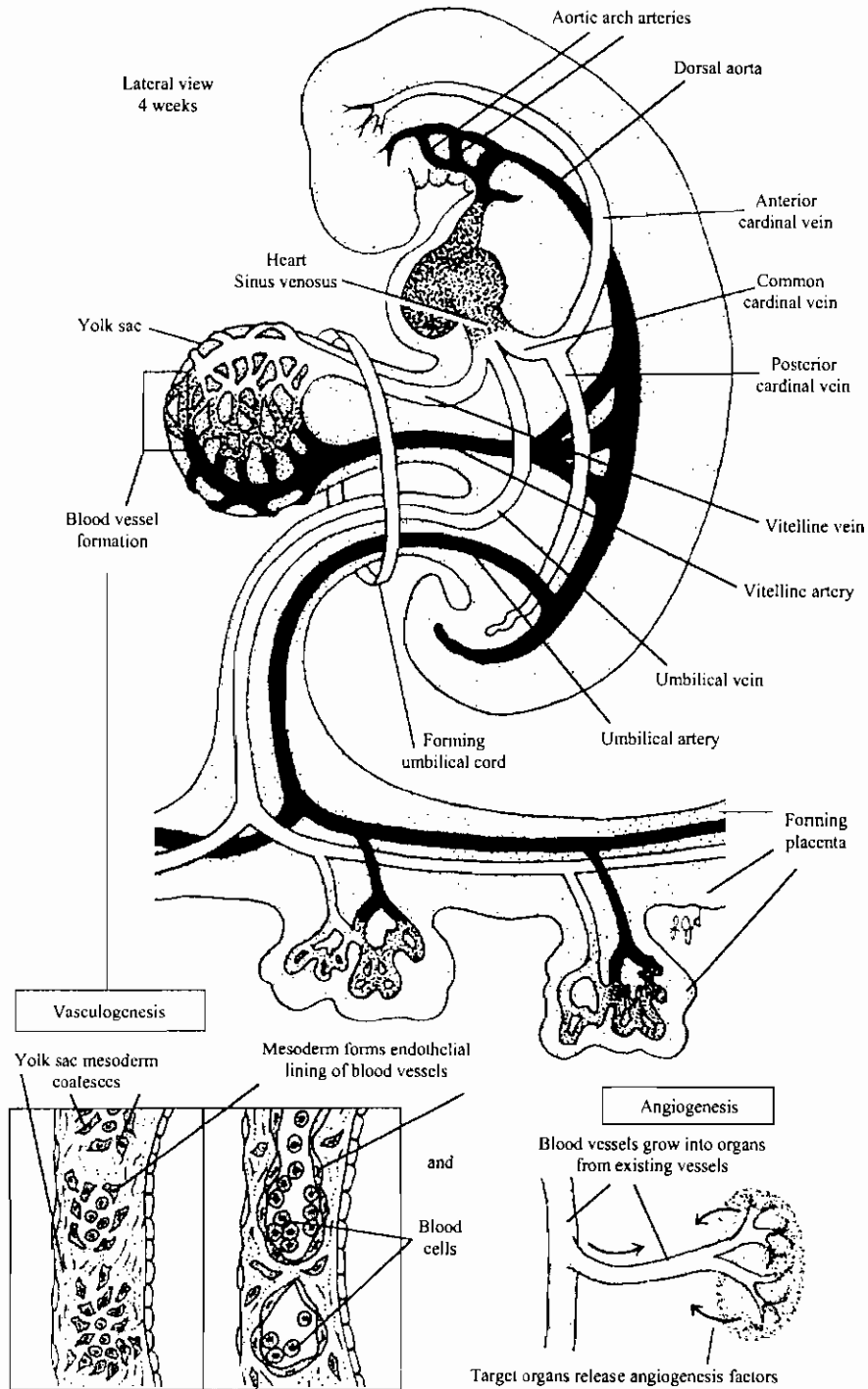
تكوين القلب وتميز حجراته المختلفة في الإنسان
 Heart tube looping and development of regions



Diagrams showing progress of fusion of cardiac primordia in the pig as seen in ventral views. (A) 5-somite embryo; (B) 7-somite embryo; (C) 13-somite embryo. The embryos are supposed to be viewed as transparent objects with the outlines of the cardiac primordia showing through. The lines A, B, and D indicate the levels of sections A, B, and D in Figure 9-12.



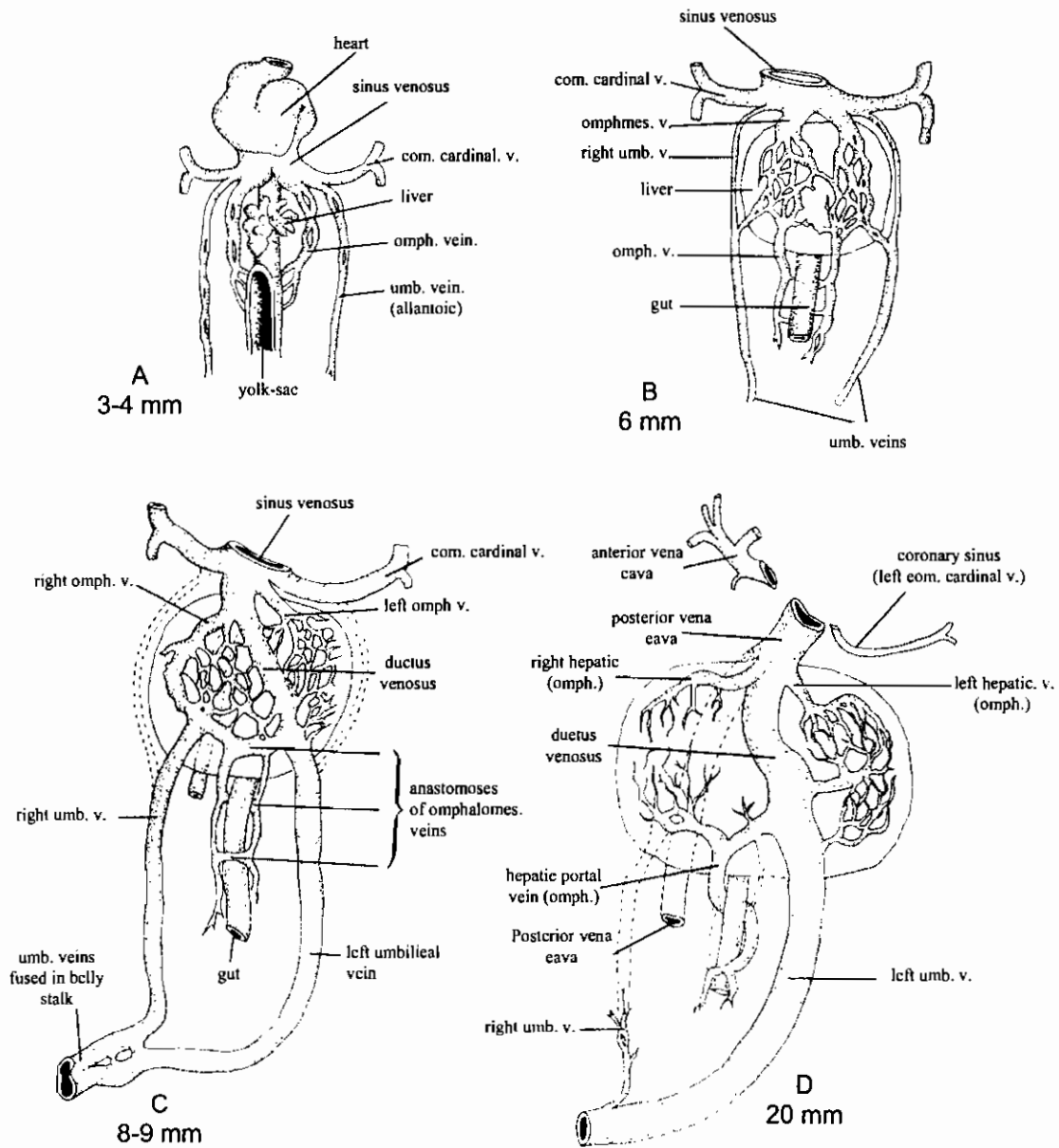
الأوعية الدموية الأولية في أجنة الإنسان



تكوين الدم والأوعية الدموية في أجنة الإنسان

Overview of the formation of the earliest arteries and veins

مناظر بطنية توضح تكوين الدورة البابية الكبدية في أجنة الخنزير

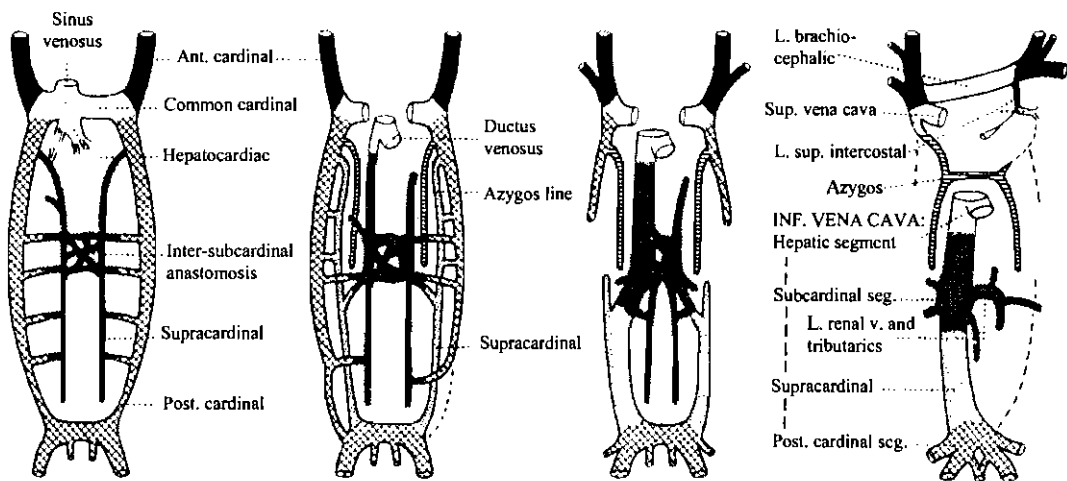
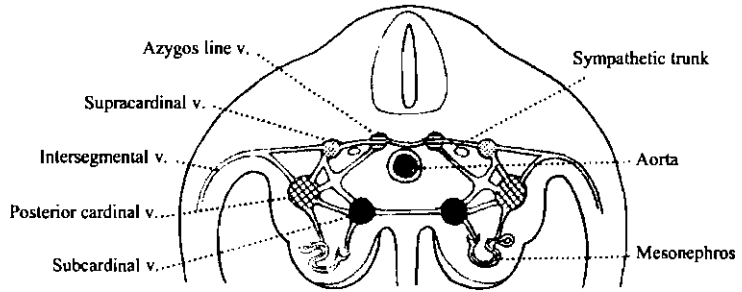


Development of the hepatic portal circulation and the umbilical veins in the pig embryo. Compare 10mm pig section to C (8-9mm). (From B. M. Patten, Embryology of the Pig. Copyright 1948 by the McGraw-Hill Book Co. Copyright renewed 1959 by B. M. Patten. Used with permission of the McGraw-Hill Book Co.)

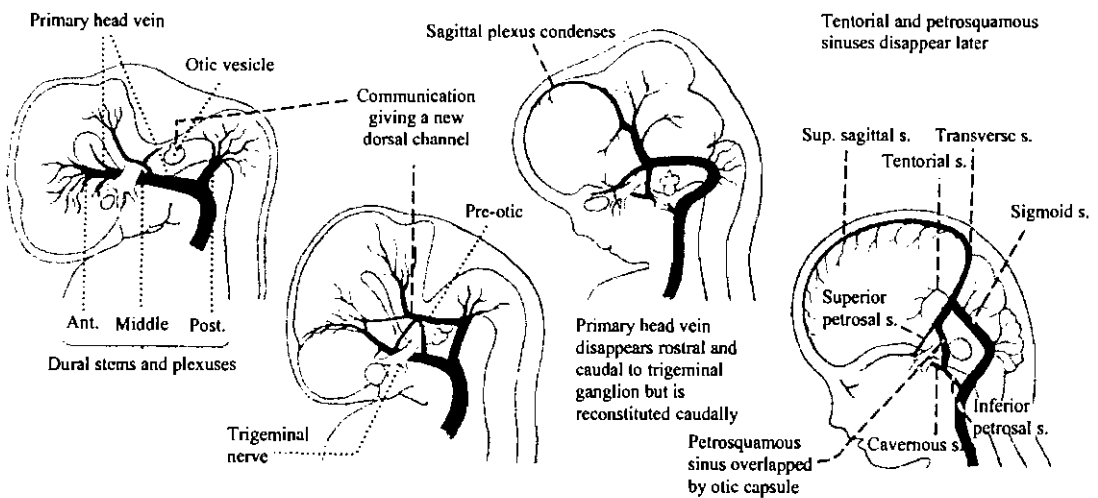
تطور الأوردة المختلفة في جنين الثدييات

The Somatic Veins

THE MAIN LONGITUDINAL VENOUS CHANNELS OF THE TRUNK AND THEIR ANASTOMOTIC CONNEXIONS



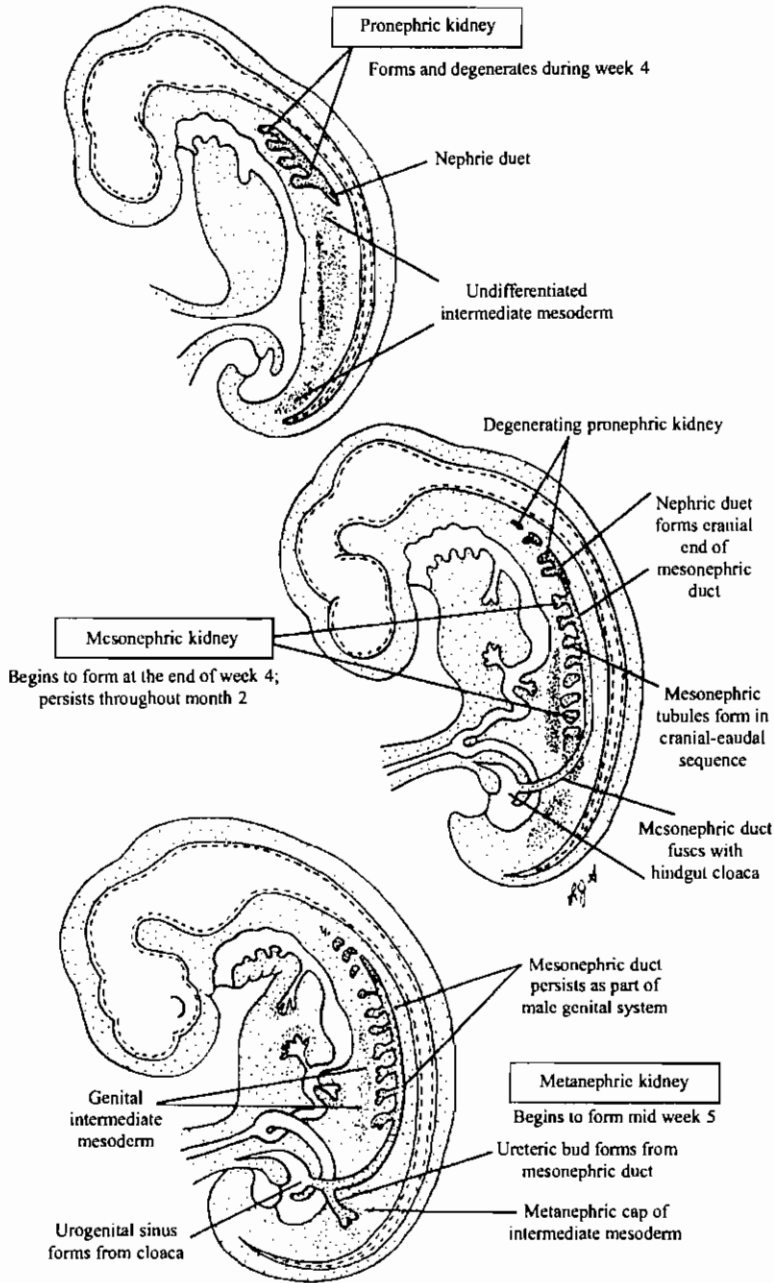
Dural Venous Sinuses



ثلاث مراحل في تكوين الكلى الخلفية في الإنسان

The three stages of kidney development

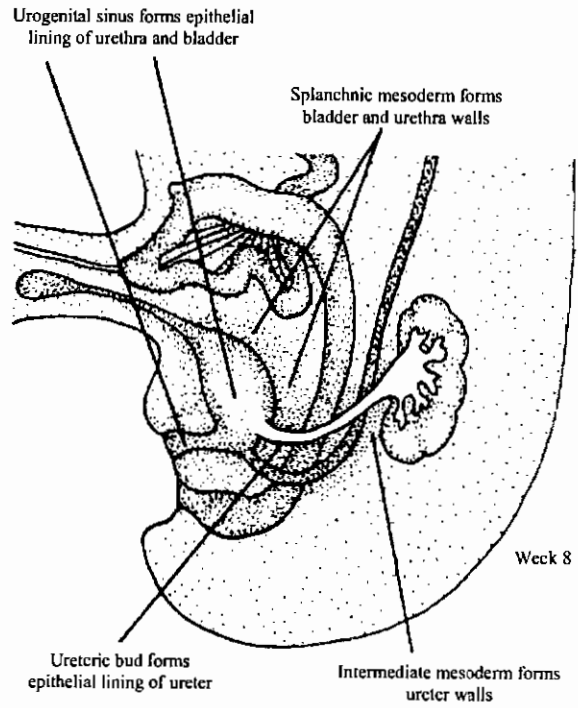
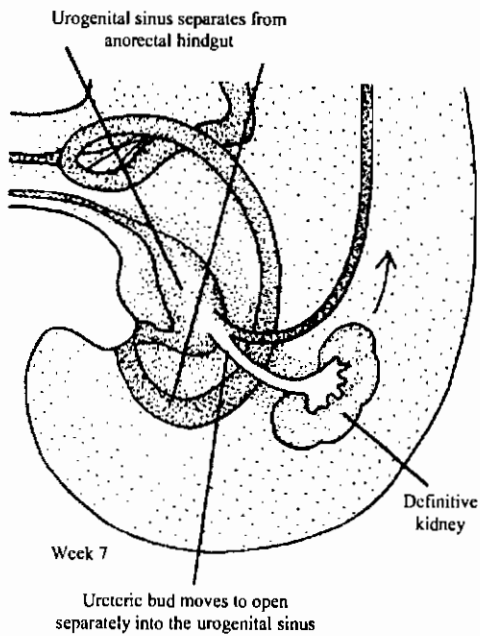
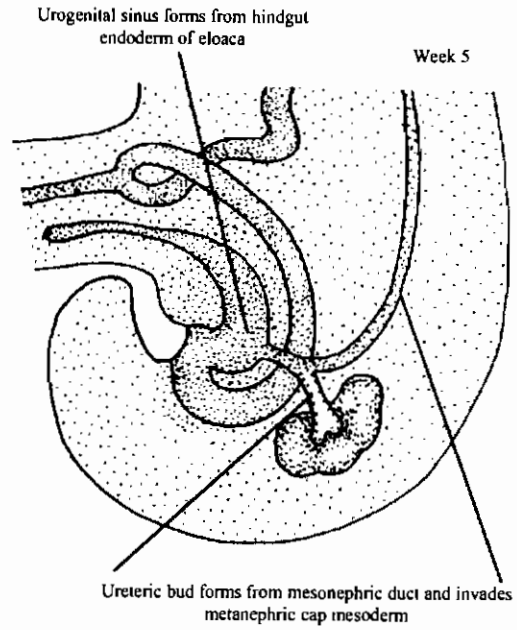
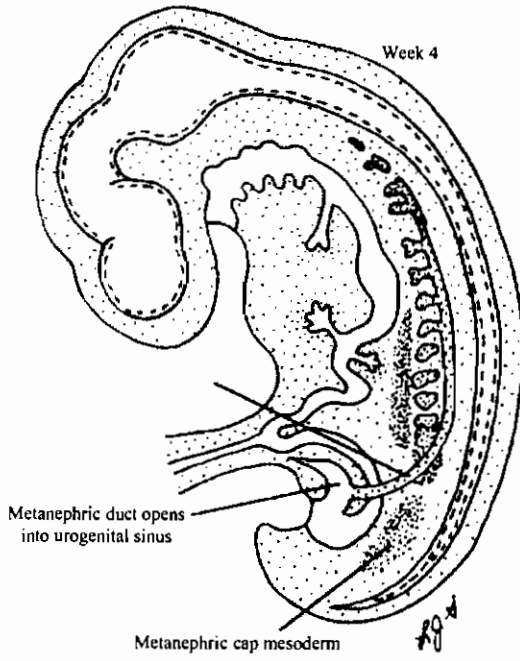
Urinary System



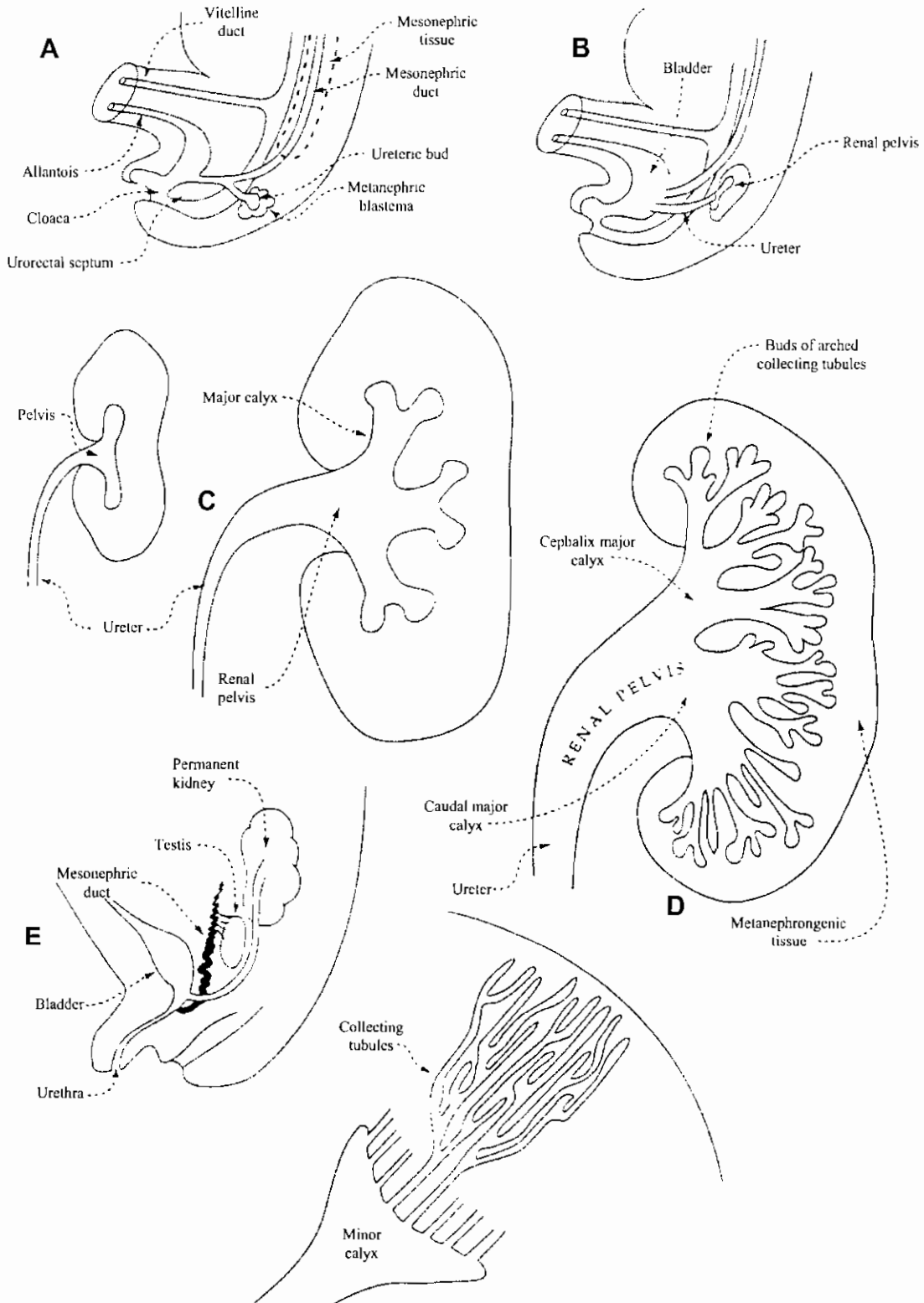
تكوين الحالب والمثانة البولية والقناة البولية التناسلية في الإنسان

Development of ureters, bladder, and urethra

Urinary System

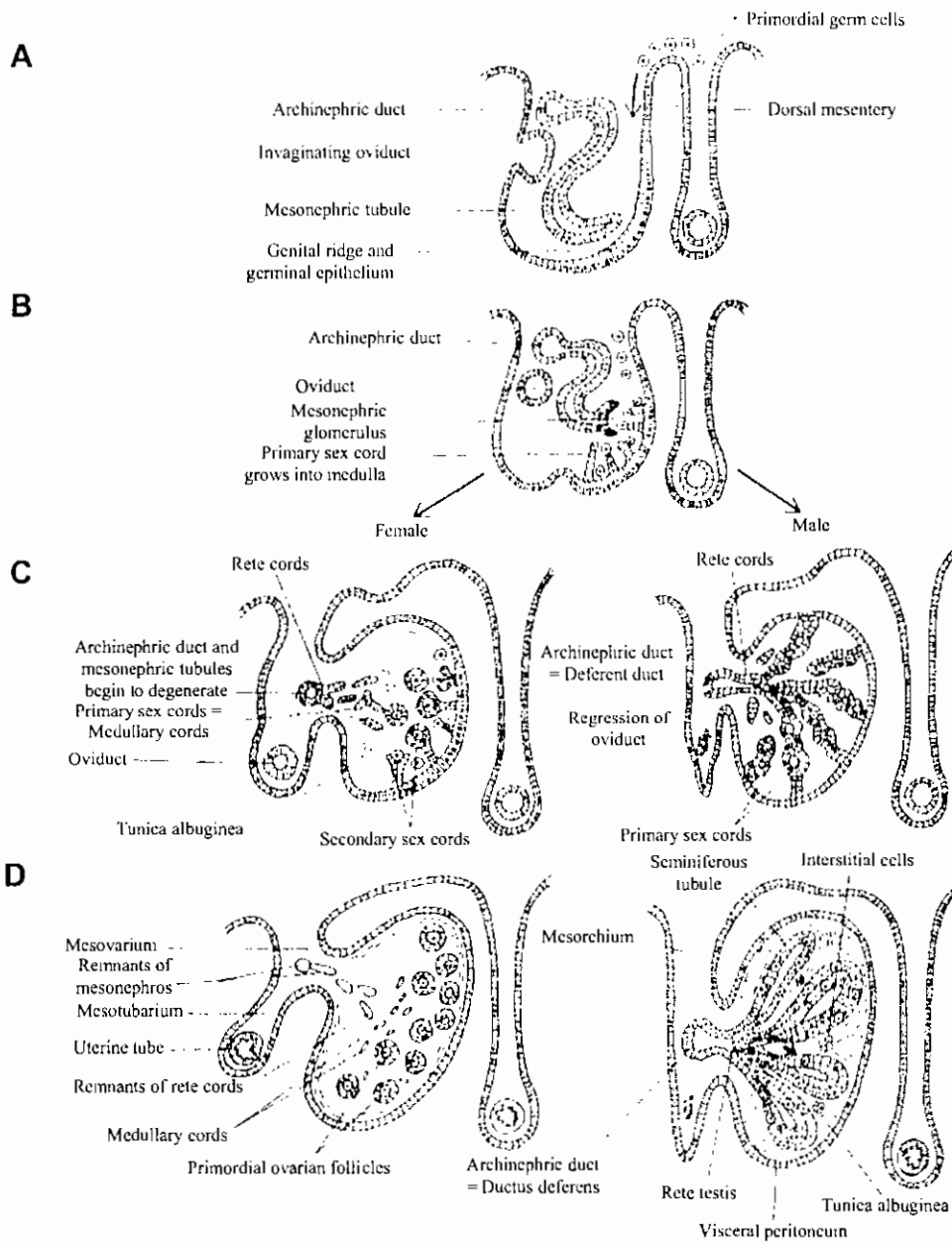


تكوين الكلية الخلفية وتميز أنسجتها



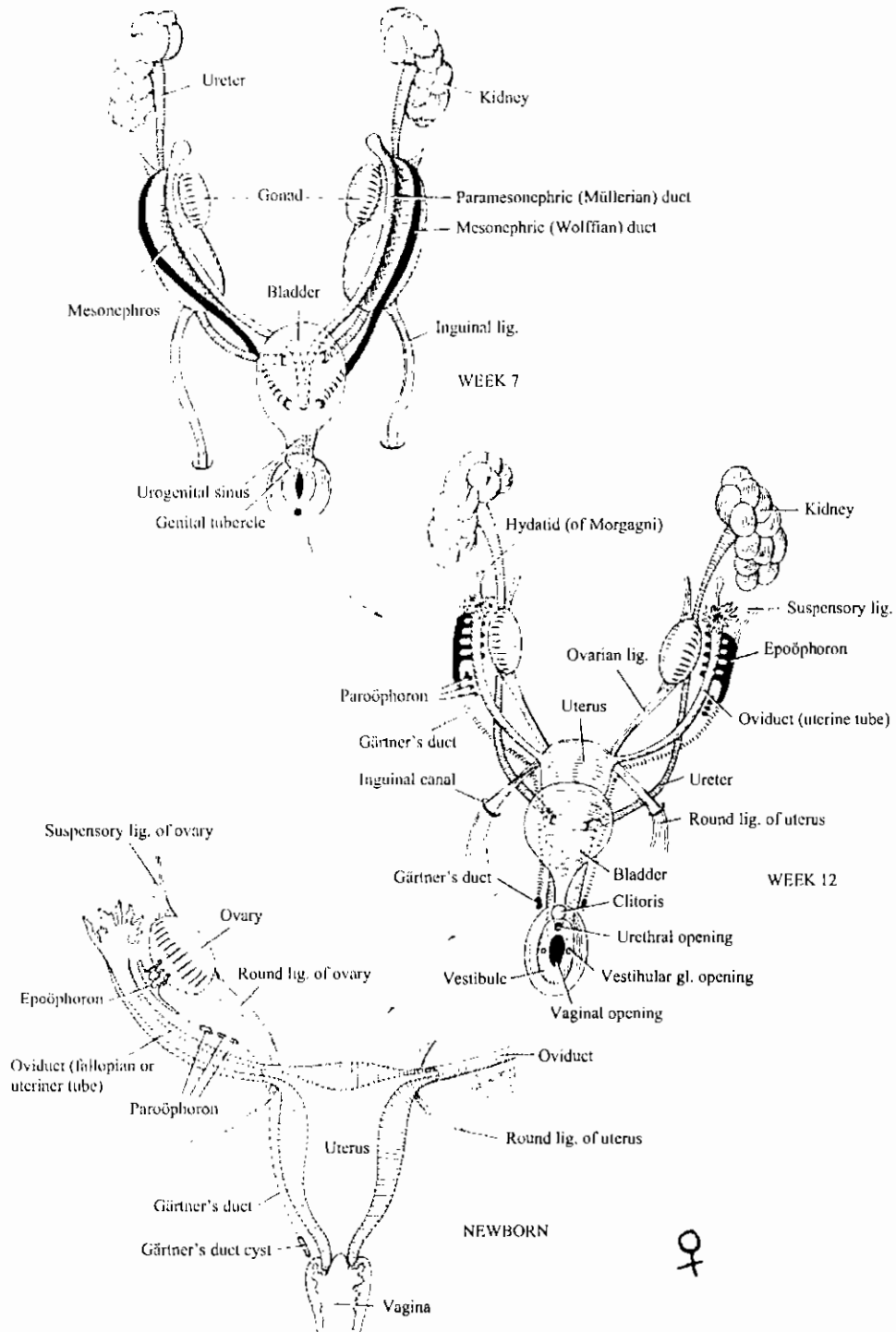
قطاعات عرضية توضح منشأ المنسل وتميزه في الجنسين

Transverse sections through the mesonephros and developing gonad of a mammal: *A* and *B*, The development of the sexually indifferent gonad. *C*, An early stage in the differentiation of an ovary (left) and testis (right). *D*, A later stage in the differentiation of the ovary and testis. (Slightly modified after Williams and Warwick.)

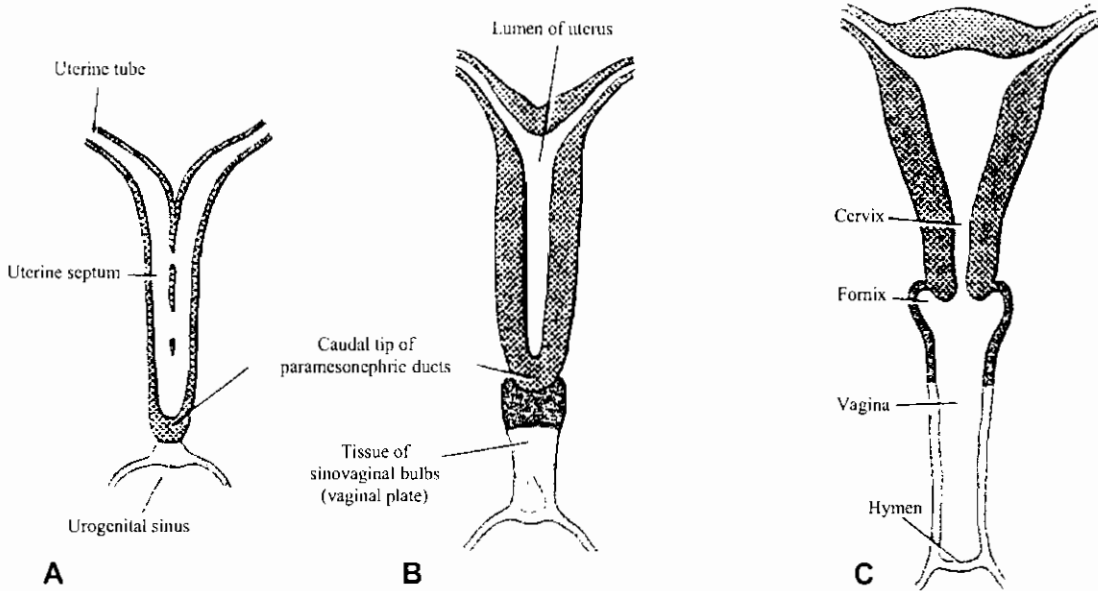


تكوين الجهاز البولي التناسلي للأنتى

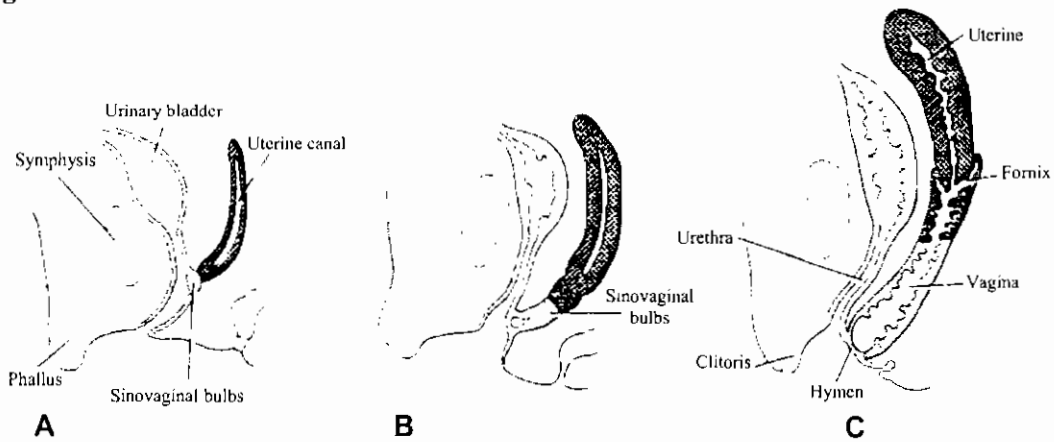
Undifferentiated Urogenital Excretory System



تكوين الرحم والمهبل



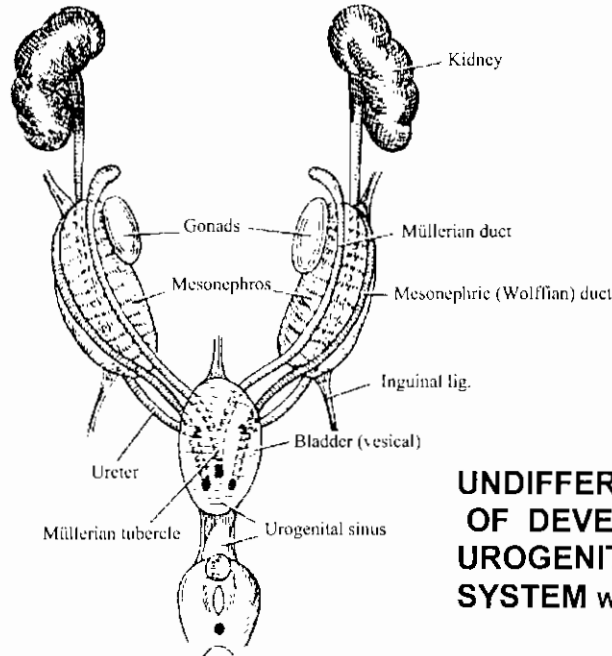
Schematic drawing showing the formation of the uterus and vagina. A, At 9 weeks. Note the disappearance of the uterine septum. B, At the end of the 3rd month. Note the tissue of the sinovaginal bulbs. C, Newborn. The upper portion of the vagina and the fornices are formed by vacuolization of the sinovaginal bulbs.



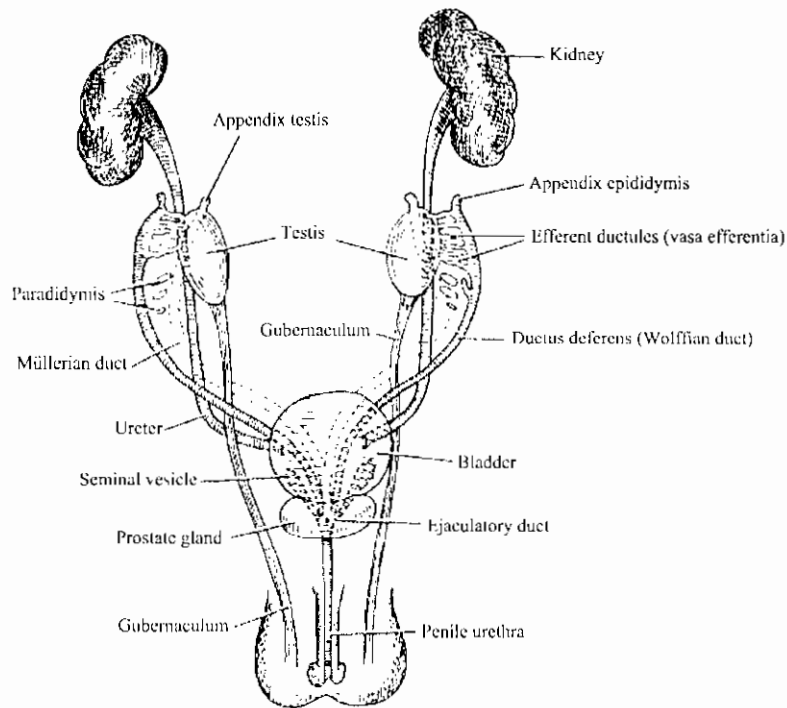
Schematic sagittal sections showing the formation of the uterus and vagina at various stages of development.

تكوين الجهاز البولي التناسلي الاخراجي في الذكر

Differentiation and development of the male excretory system



UNDIFFERENTIATED STAGE OF DEVELOPMENT OF UROGENITAL EXCRETORY SYSTEM WEEK 7

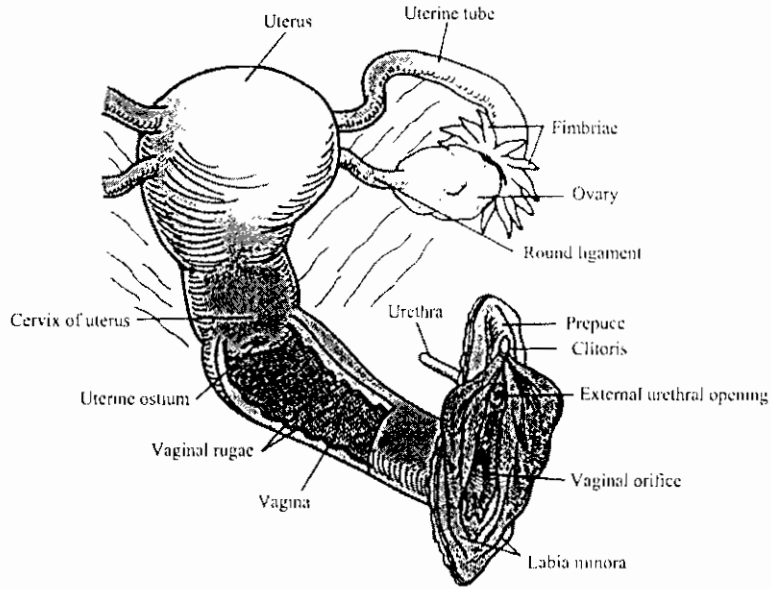


DIFFERENTIATED MALE UROGENITAL EXCRETORY SYSTEM, WEEK 11

الأحداث المواكبة للتبويض في الإنسان

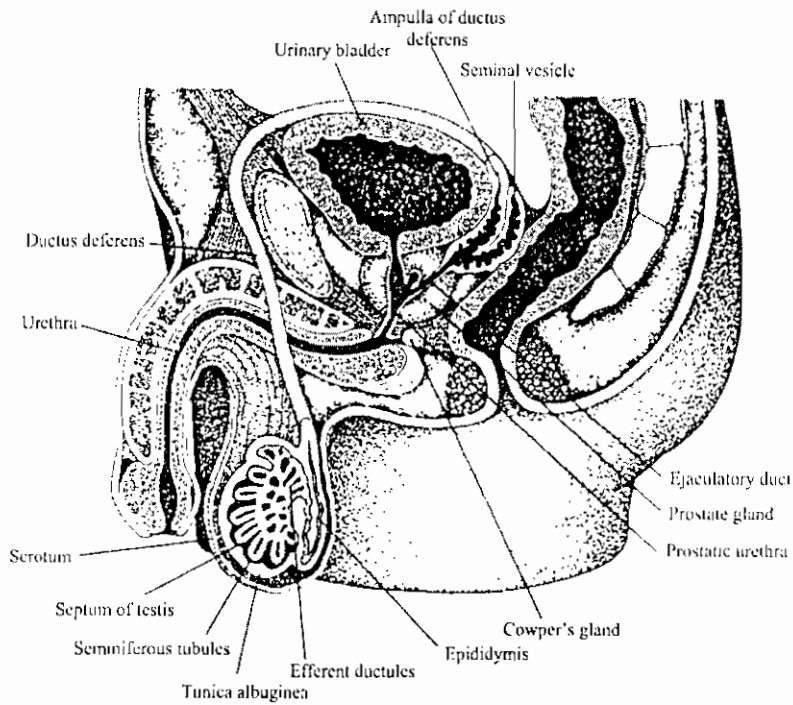
The major events in human oogenesis

Age	Follicular histology	Meiotic events in ovum	Chromosomal complement
Fetal period	No follicle	Oogonium <i>Mitosis</i>	2N,2C
Before or at birth	Primordial follicle	Primary oocyte <i>Meiosis in progress</i>	2N,4C
After birth	Primordial follicle	Primary oocyte <i>Arrested in diplotene stage of first meiotic division</i>	2N,4C
After puberty	Secondary follicle	Primary oocyte <i>First meiotic division completed, start of second meiotic division</i>	2N,4C
	Tertiary follicle	Secondary oocyte + Polar body I <i>Ovulation</i>	1N,2C
	Ovulated ovum	Secondary oocyte + Polar body I <i>Arrested at metaphase I</i>	1N,2C
	Fertilized ovum	Fertilized ovum + Polar body II <i>Fertilization - second meiotic division completed</i>	1N,1C - sperm



الجهاز التناسلي للأنثى

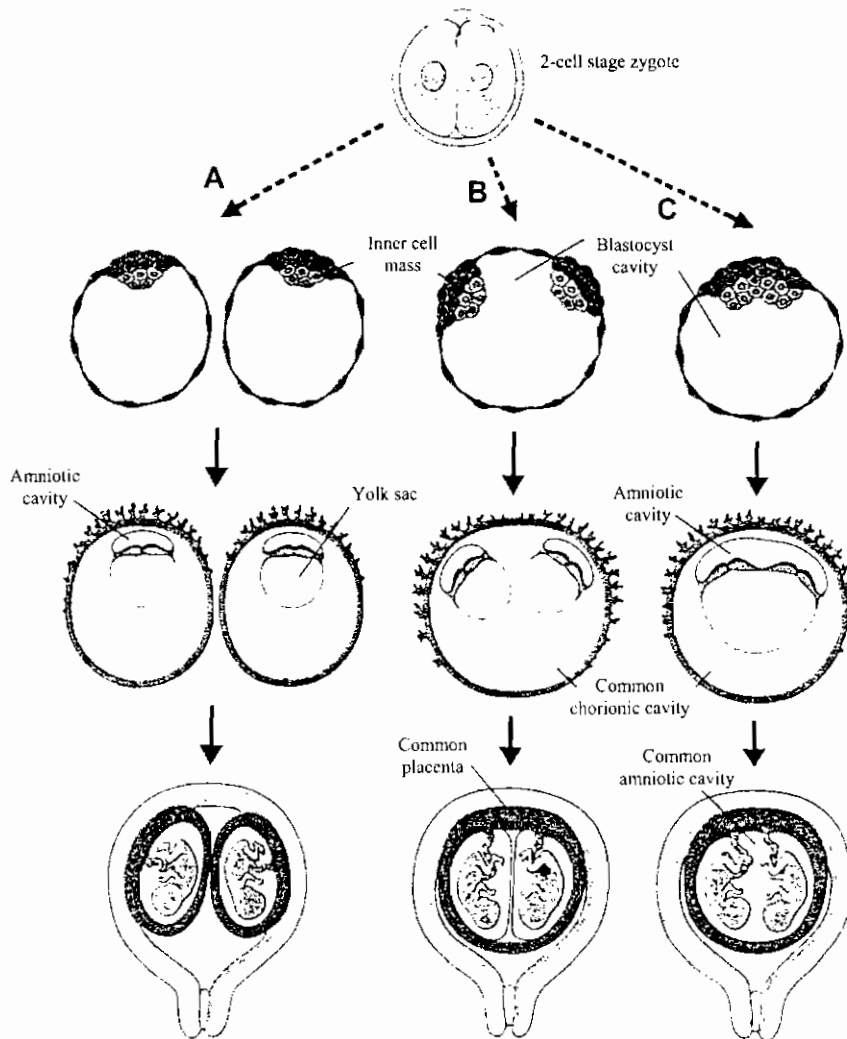
The female genital system



الجهاز التناسلي في الذكر

Male reproductive system

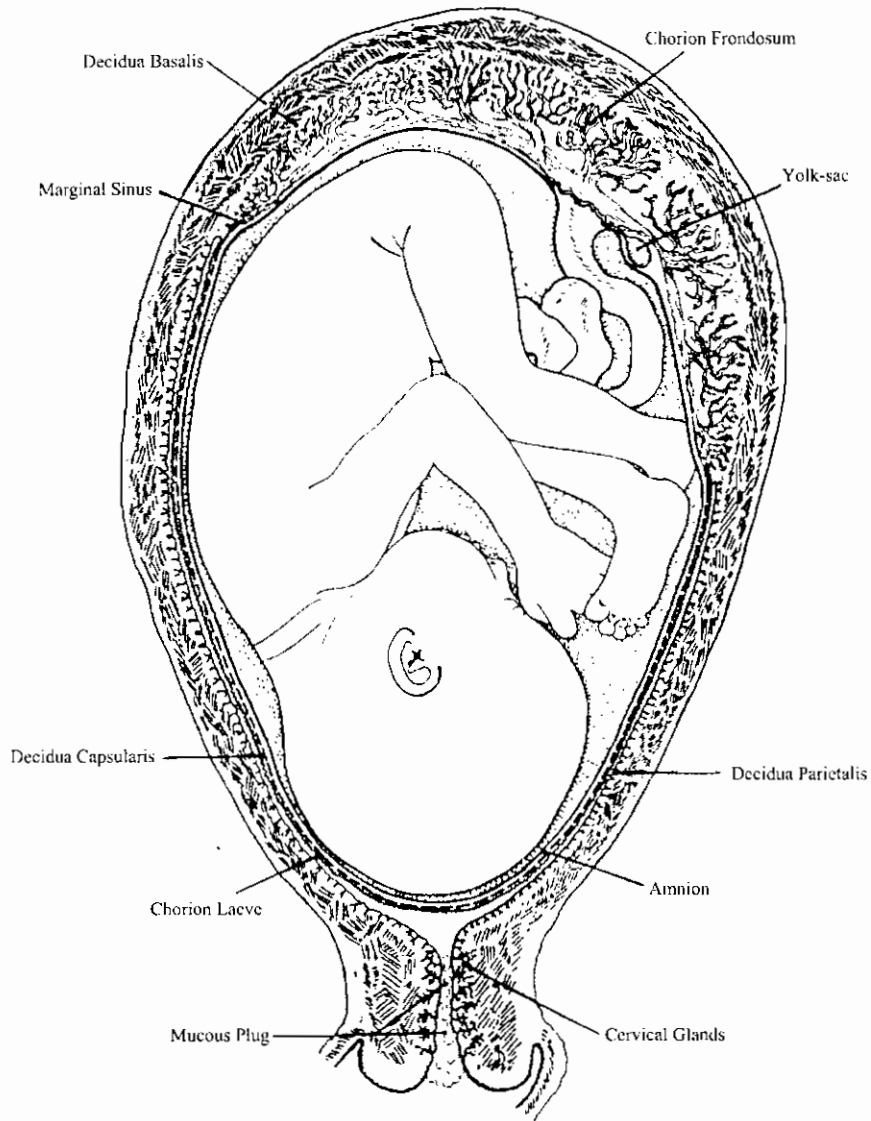
تكوين التوائم المتشابهة



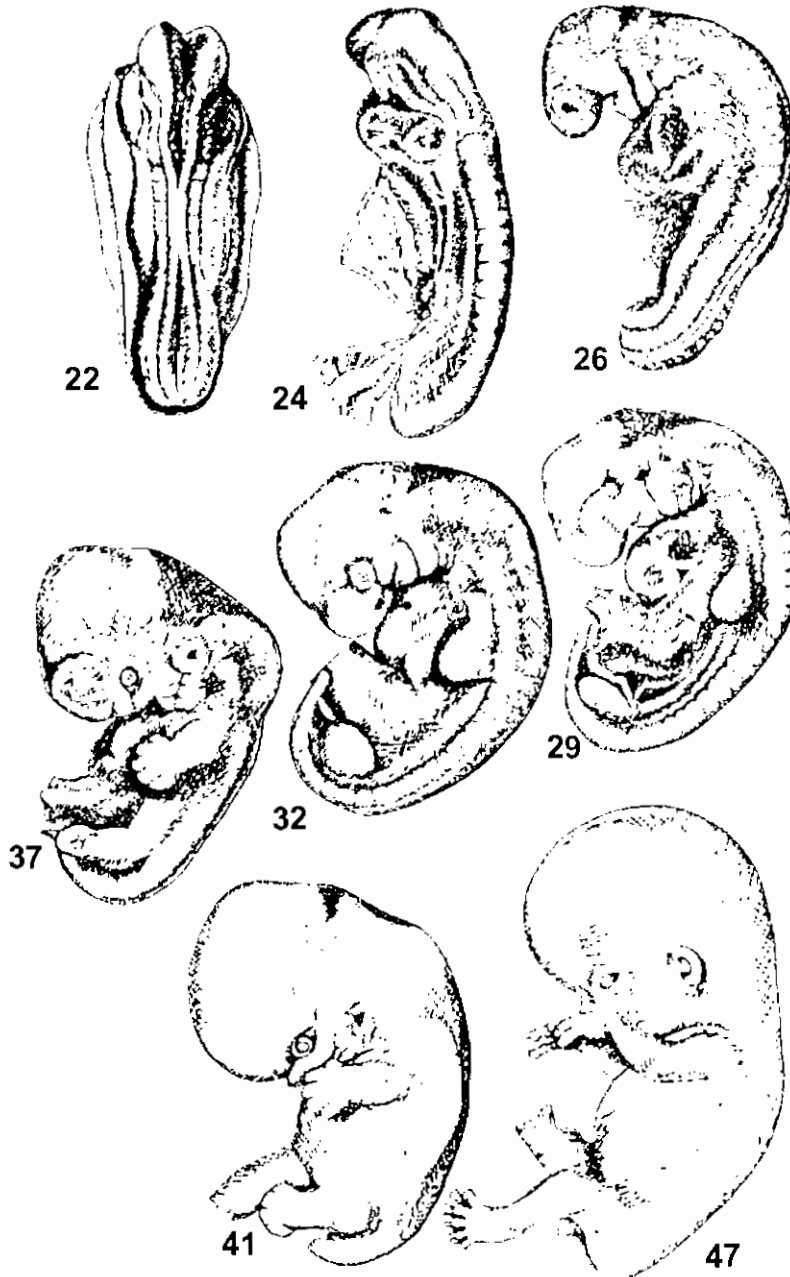
Schematic diagrams showing the possible relations of the fetal membranes in monozygotic twins. A, Splitting occurs at the two-cell stage and each embryo has its own placenta, amniotic cavity, and chorionic cavity. B, Splitting of the inner cell mass into two completely separated groups. The two embryos have a common placenta and a common chorionic sac, but separate amniotic cavities. C, Splitting of the inner cell mass at a late stage of development. The embryos have a common placenta, a common amniotic cavity, and a common chorionic cavity.

جنين الإنسان في عمر خمسة أشهر

5- Month human fetus

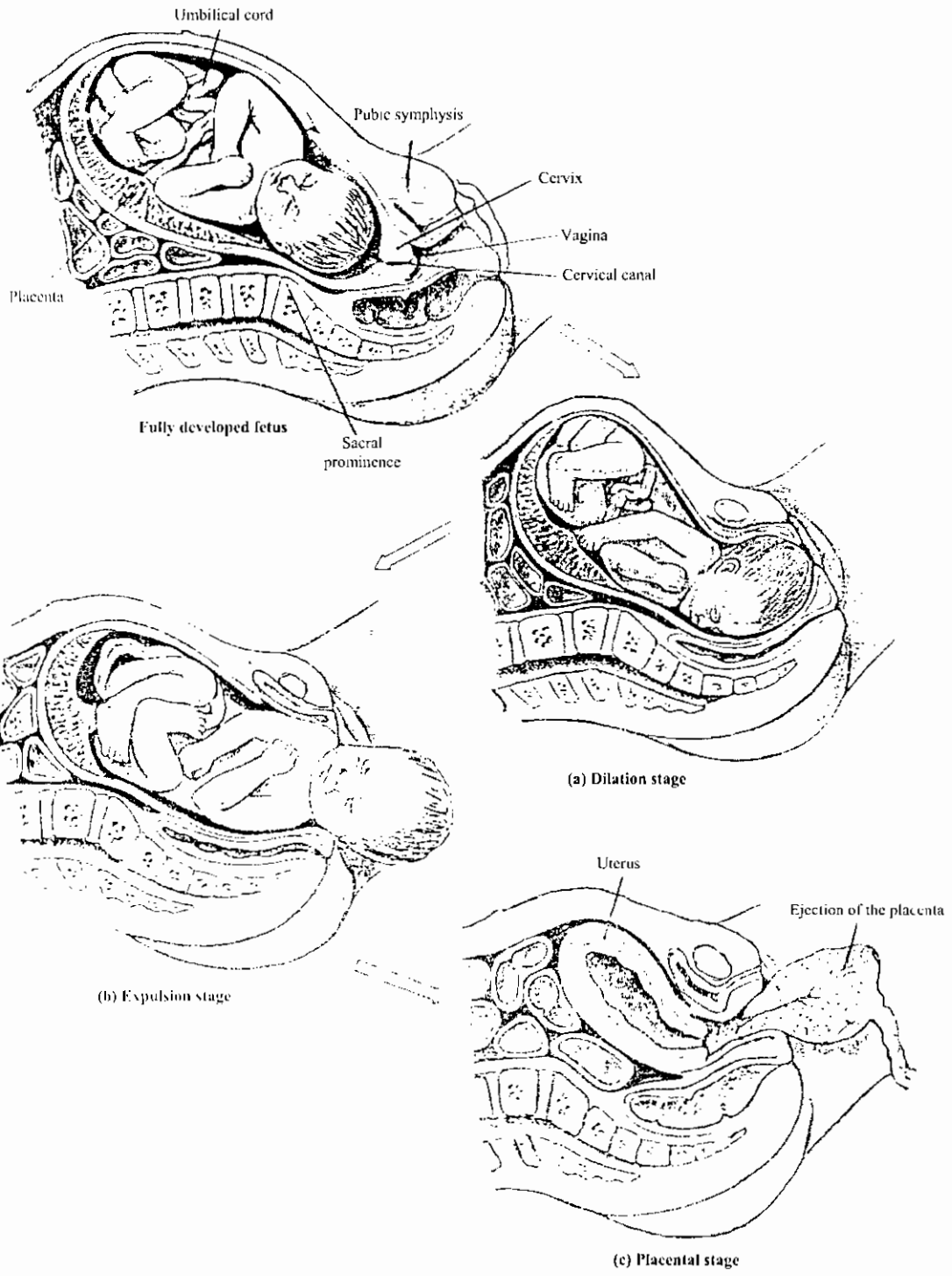


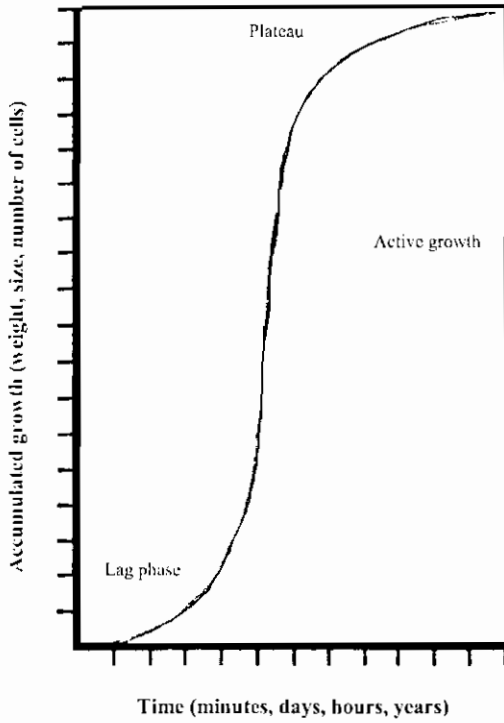
الشكل الخارجى لجنين إنسان فى مراحل مختلفة من النمو



Stages of development of the human embryo. Figures show approximate age in days. (22-day-old embryo, after Arey: *Developmental Anatomy*; 37-day-old embryo redrawn from Hamilton, Boyd, and Mossman, 1947; the rest after Streeter, 1942 – 1951.)

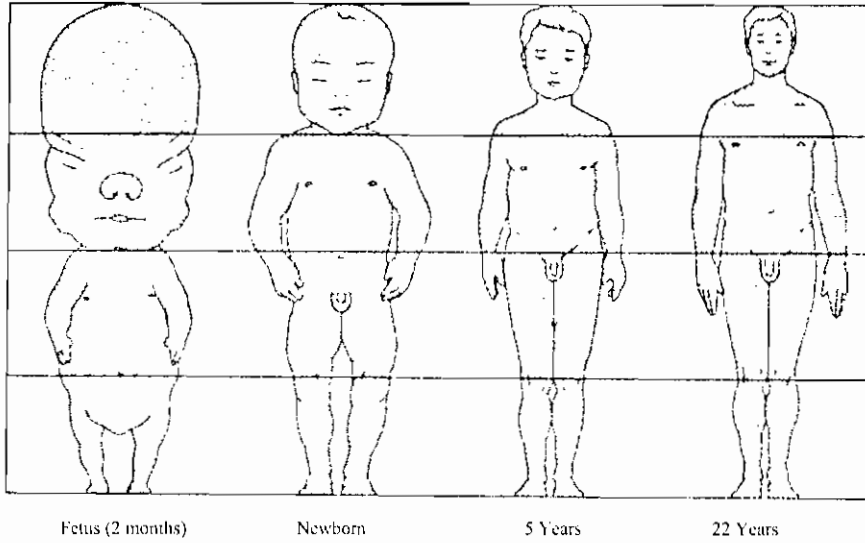
مراحل الولادة
The Stages of Labor





منحنى النمو في الخلايا المزروعة أو في عدد الأفراد
أو المجاميع بمرور الوقت

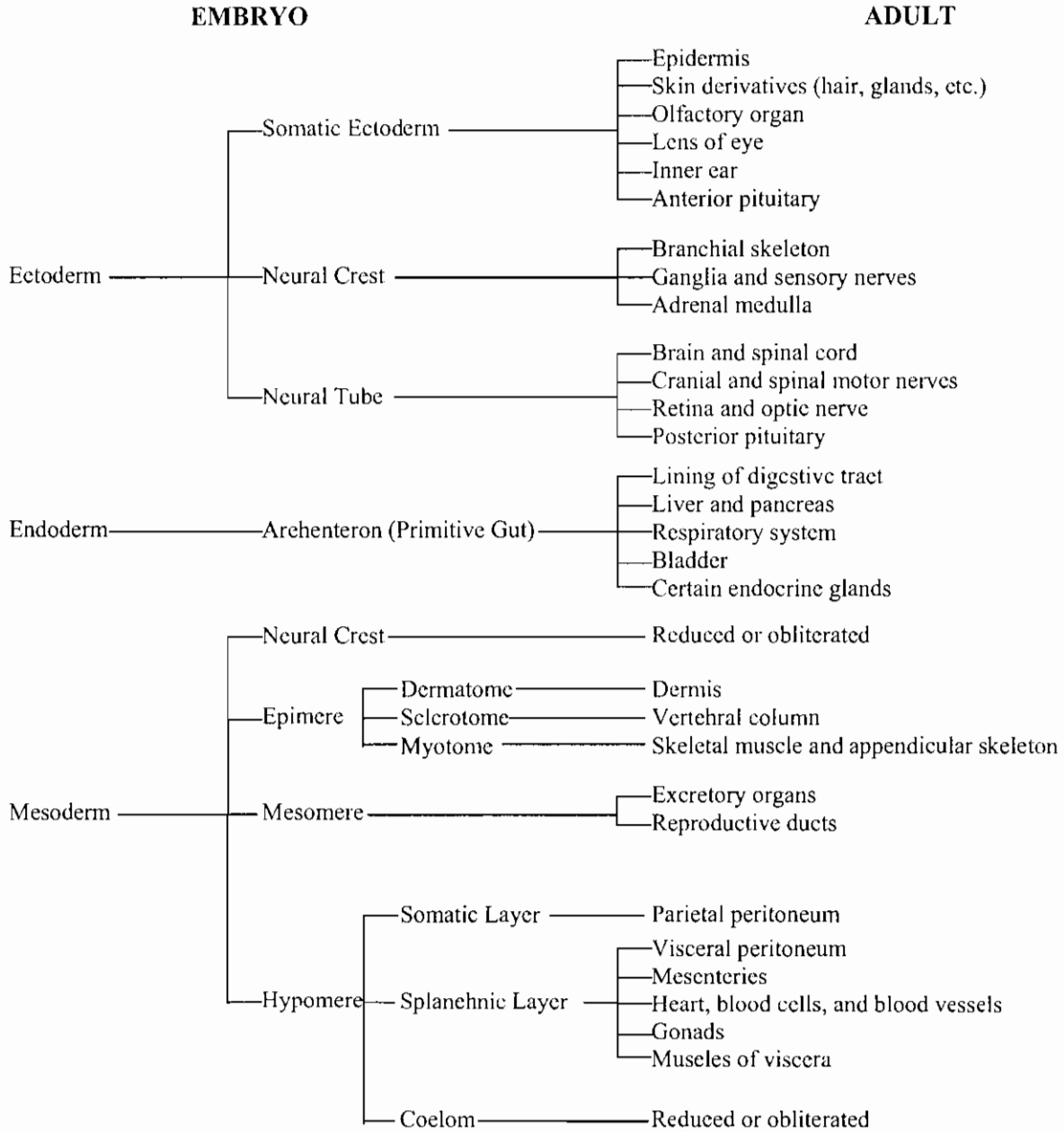
Growth curve of cells, organisms, or populations is shaped. The abscissa is an expression of time, and the ordinate is some measurement of growth. Growth starts out slowly, enters a period of rapid increase, and then reaches a plateau.



التغير في شكل جسم الإنسان أثناء نموه من جنين إلى فرد بالغ
Alterations in form of human body as it develops from embryo to adult.

الأعضاء المتكونة من الثلاث طبقات الجنينية الأساسية

Chart showing the embryonic derivation of the principal parts of the adult body.



References

Alexander Sandra and William J. Coons, 1997

Core concepts in embryology
Lippincott – Raven; Philadelphia. New York

Ben Pansky, 1982

Review of medical embryology
Macmillan Pub. Co., Inc.; New York

Bruce M. Carlson, 1994

Human embryology and development biology
Mosby; St louis, Baltimore, Chicago, Madrid, Phil. Sydney, Toronto

George Matsunura and Marjorie A. England, 1992

Embryology colouring book
Wolfe

Farid, M. A., 1999

Atlas of histology
International house for cultural investments, Cairo – Egypt

Freeman, W. H., and Brian Bracegirdle, 1967

Atlas of Embryology
Heinemann Educational books Ltd. London

Fitzgerald, M. J. T. & Fitzgerald, M., 1994

Human Embryology
Baillier Tindall, London Philadelphia Toronto Sydney Tokyo

Jonathan Bard, 1994

Embryos; Color atlas of development
M Wolfe

Junqueira, L. C. & Carneira, J., 1980

Basic histology
Lib. Du Liban, P. O. Box 945 Beirut, Lebanon

Klaus Kalthoff, 2001

Analysis of biological development, second edition
McGraw-Hill INC

Patten, B. M., 1964 & 1996

Foundations of embryology

McGraw-Hill INC

Sadler, T. W., 1993

Langman's medical embryology
Williams & Wilkins

Scott F. Gilbert, 1997

Developmental biology
Sinauer Associates, Inc.

Sweeney, L. J., 1998

Basic concepts in Embryology
McGraw-Hill Companies

Williams and Wendell-Smith, 1969

Basic human embryology
Morrison & Gibb Ltd. London

Willis W. Mathews, 1986

Atlas of descriptive embryology
Macmillan Pub. Co.; New York

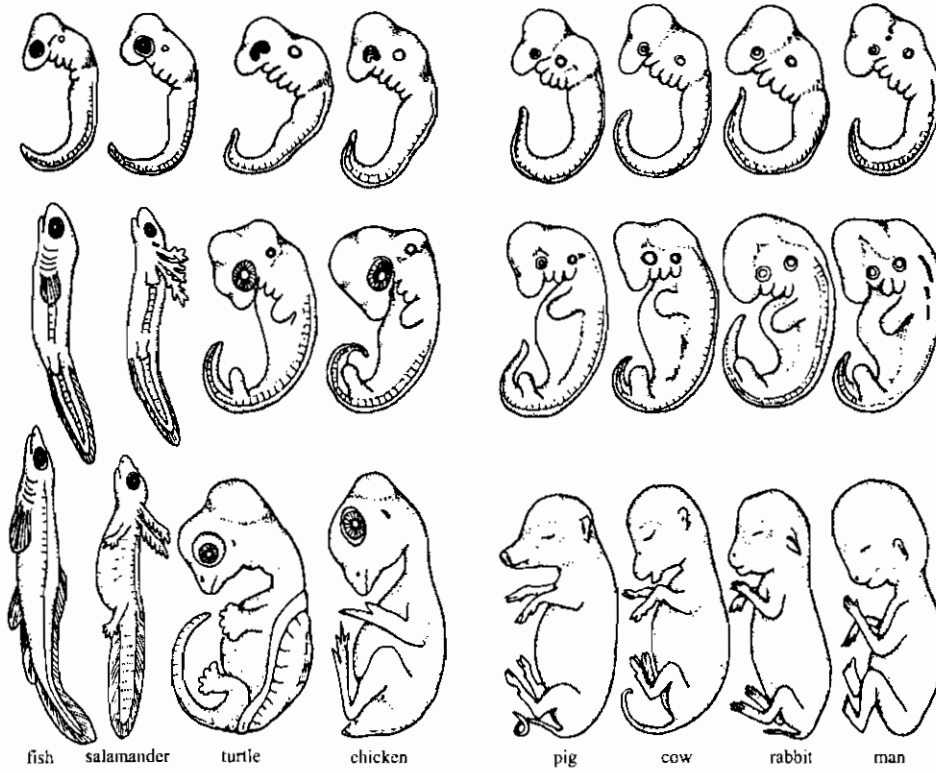
رقم الإيداع : ٢٠٠٣/١٩٧١٥

ISBN : 977-281-231-2

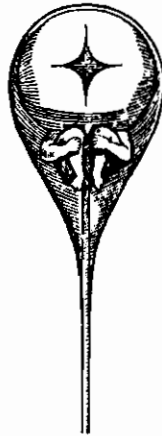
مطابع الازار الهندسية/القاهرة

تليفون/فاكس : (٢٠٢) ٥٤٠٢٥٩٨

مقارنة بين أجنة بعض الحيوانات الفقارية



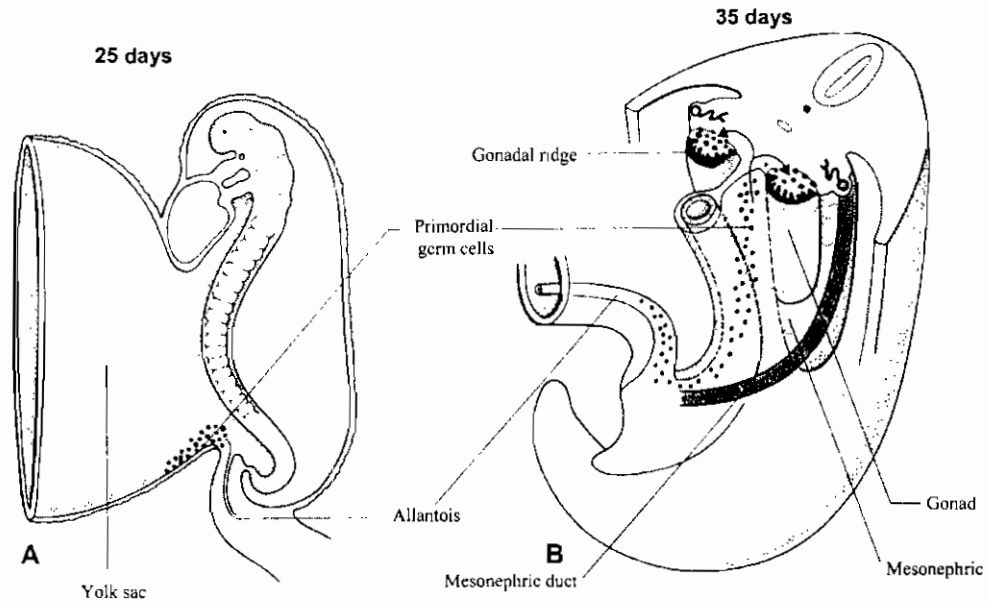
Series of vertebrate embryos in three successive and comparable stages of development. *Top*. All are much alike in the earliest stage. *Middle*. Differentiation is evident, but the four mammals (at right) are quite similar. *Bottom*. Later the distinctive characteristics of each become evident. (After Haeckel, 1891).



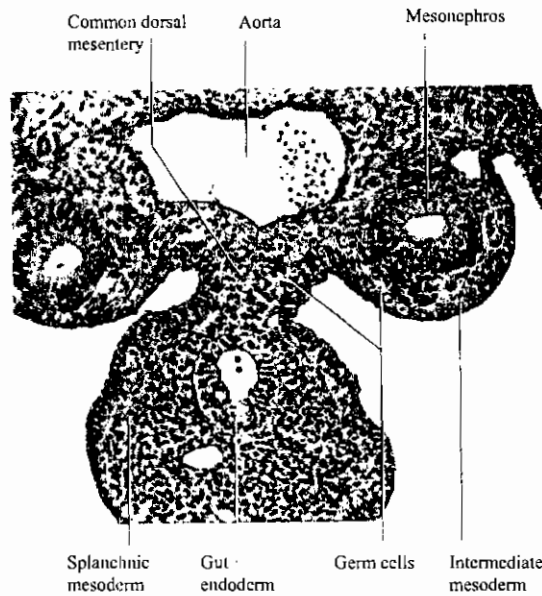
نظرية التكوين الأزلي التي عرفت في القرن السابع عشر وتفترض وجود جنين دقيق داخل الحيوان المنوى

Preformation. 17th Century idea of a human spermatozoan which was supposed to contain a minute embryo. (from Needham, 1959.)

هجرة الخلايا التناسلية الأولية من الاندودرم الى داخل المنسل الميزودرمي
 في جنين الانسان في الأسبوع الرابع والخامس من الحمل

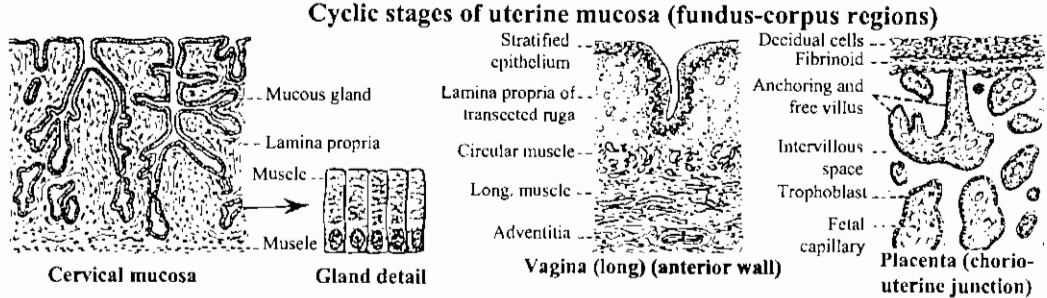
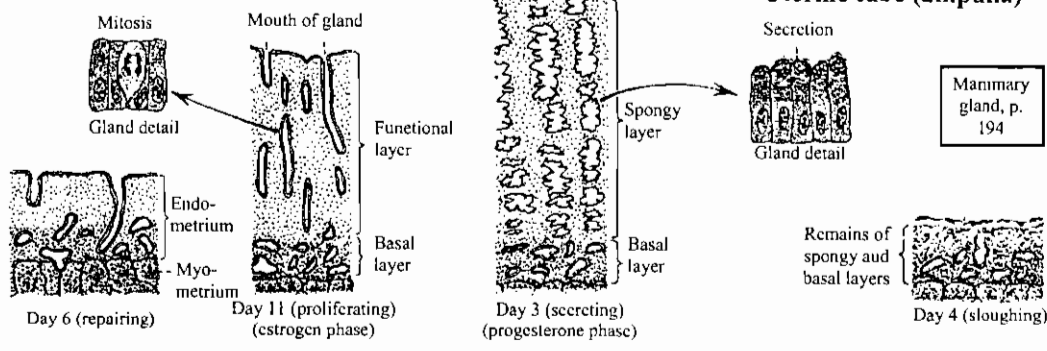
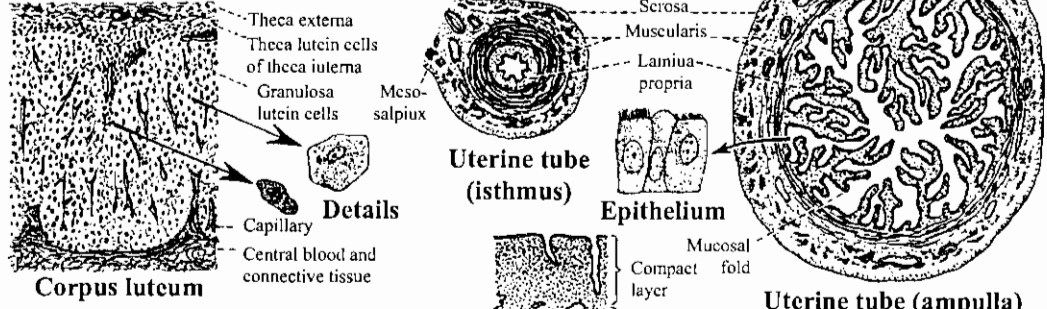
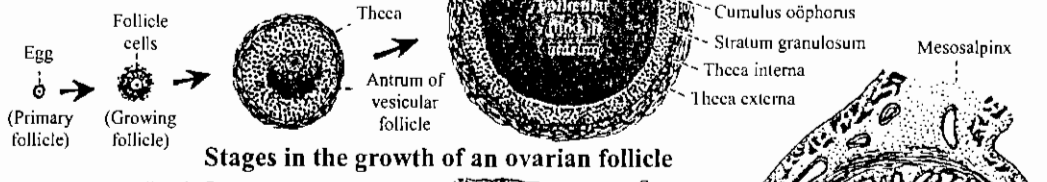
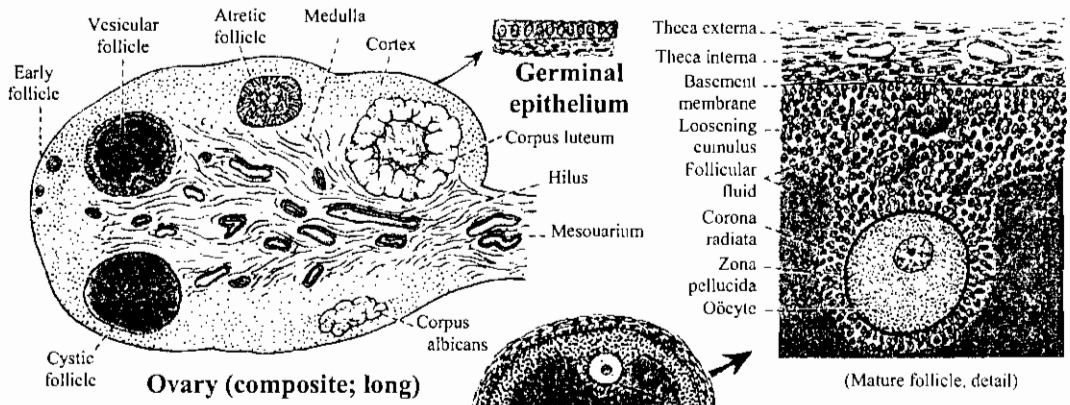


Migration of primordial germ cells during the 4th and 5th weeks. Arrows in (B) denote entry into gonads.



ق.ع. في جنين إنسان عمره خمسة أسابيع يظهر هجرة الخلايا التناسلية إلى المجرى البولي التناسلي

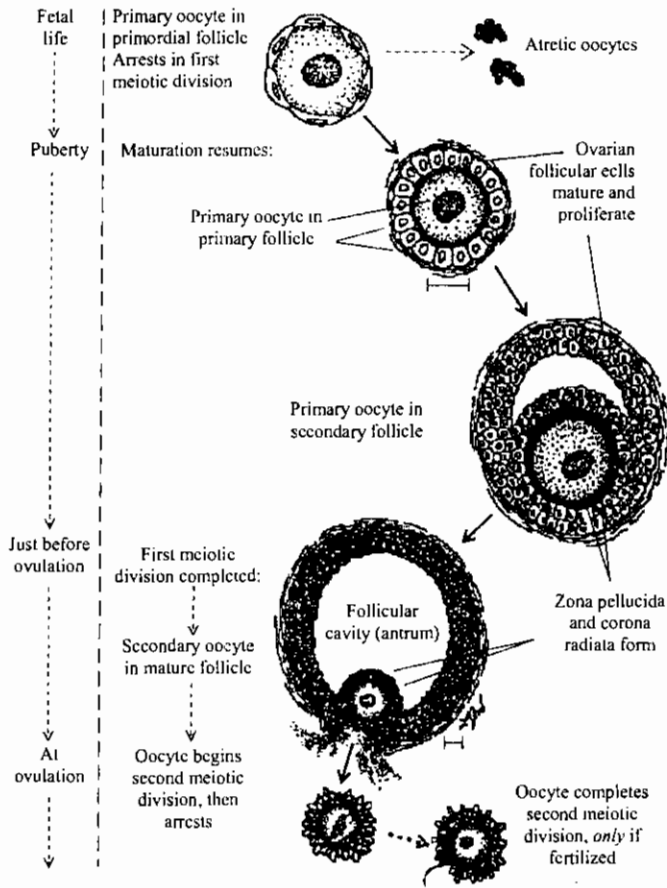
Transverse section of an early 5th - week embryo, showing germ cells traveling to the urogenital ridge.
 (Carnegie Collection, courtesy of Dr E. Witschi.)



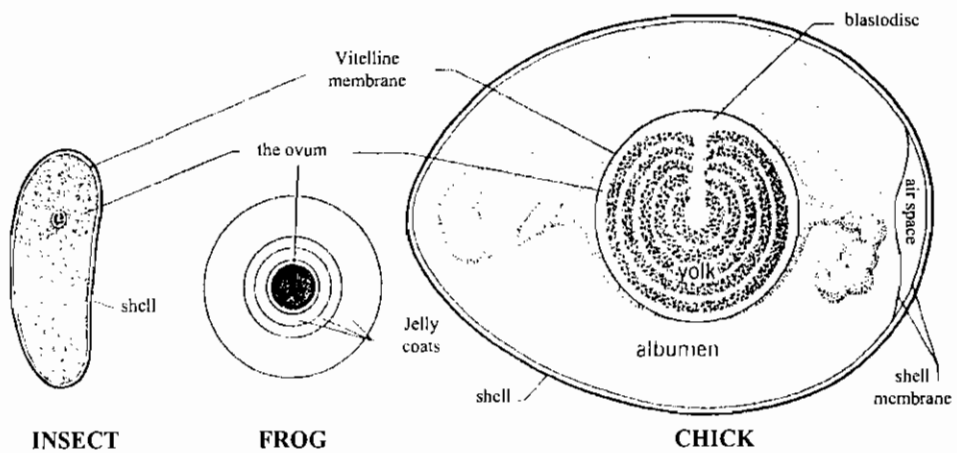
الأعضاء التناسلية الأنثوية

THE FEMALE REPRODUCTIVE ORGANS

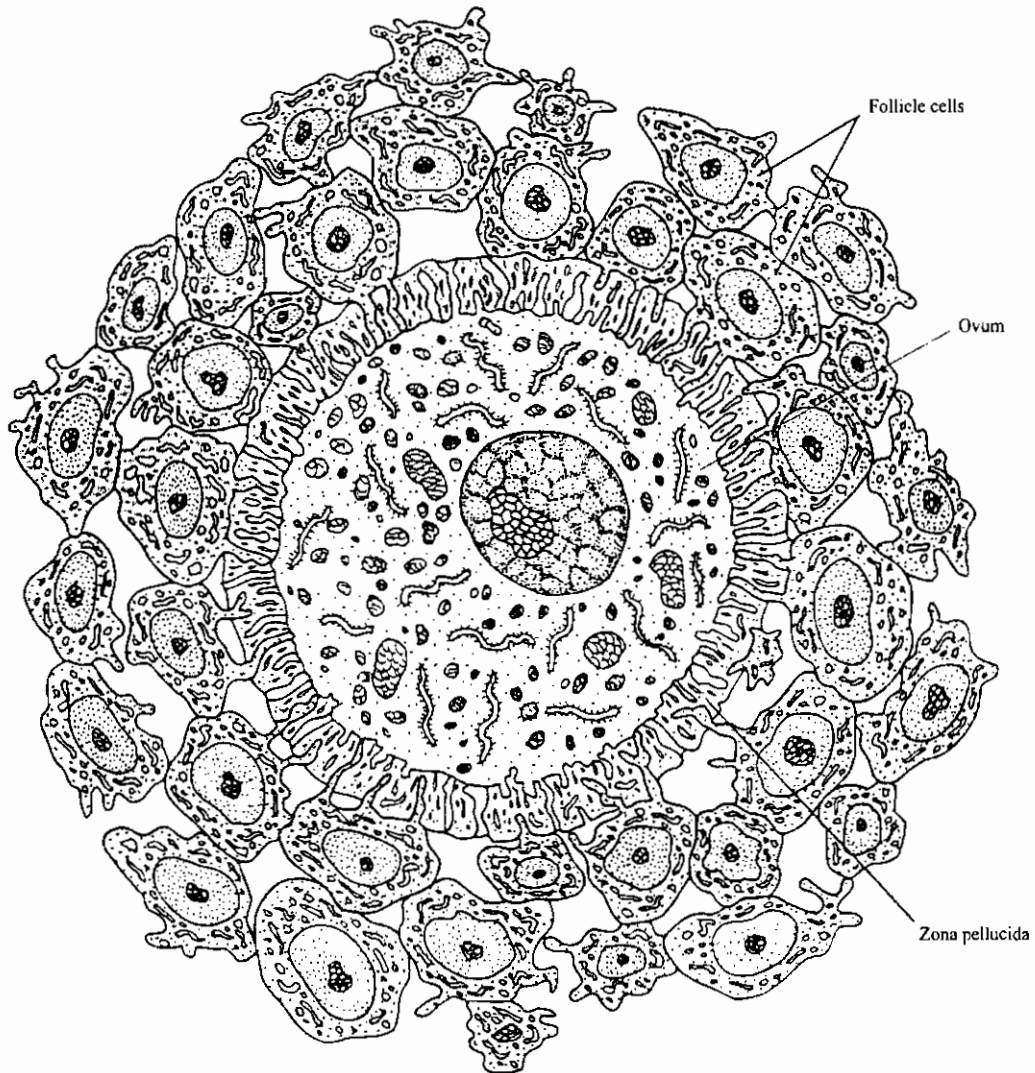
نضج البويضة والحوصلة البيضية في الثدييات



Maturation of the oocyte and its ovarian follicle.



الأغلفة المحيطة ببعض البويضات الحيوانية
Protective coverings of some animal eggs.



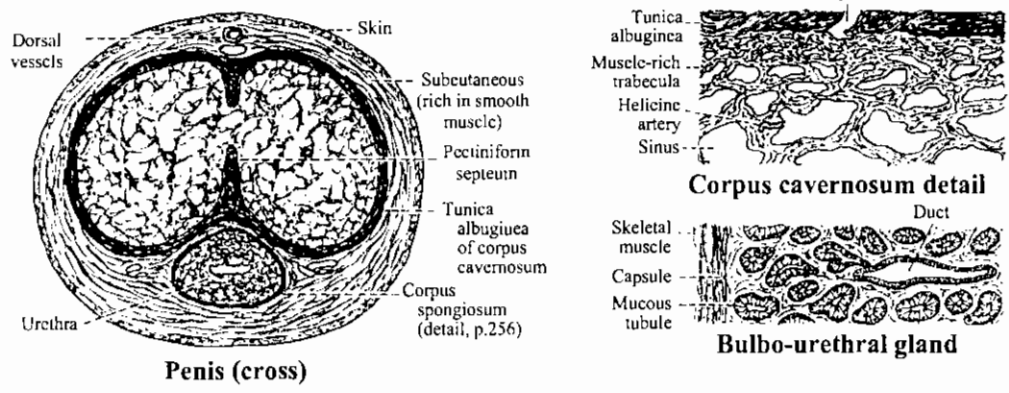
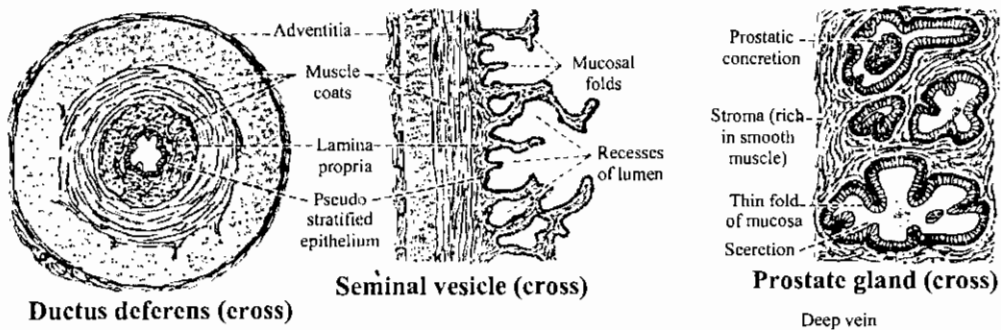
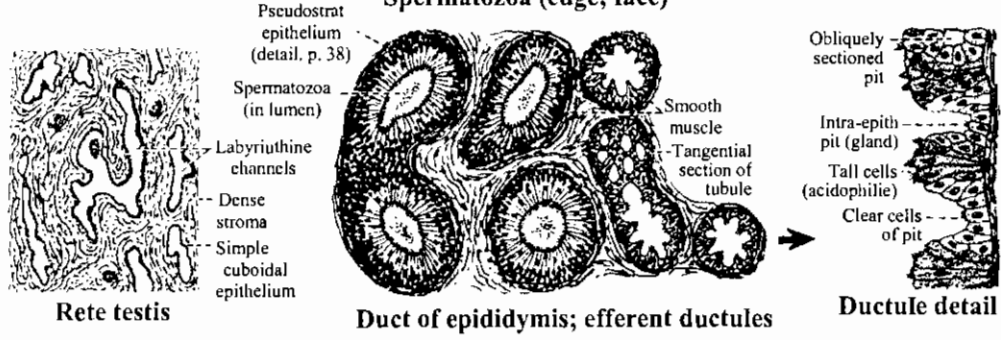
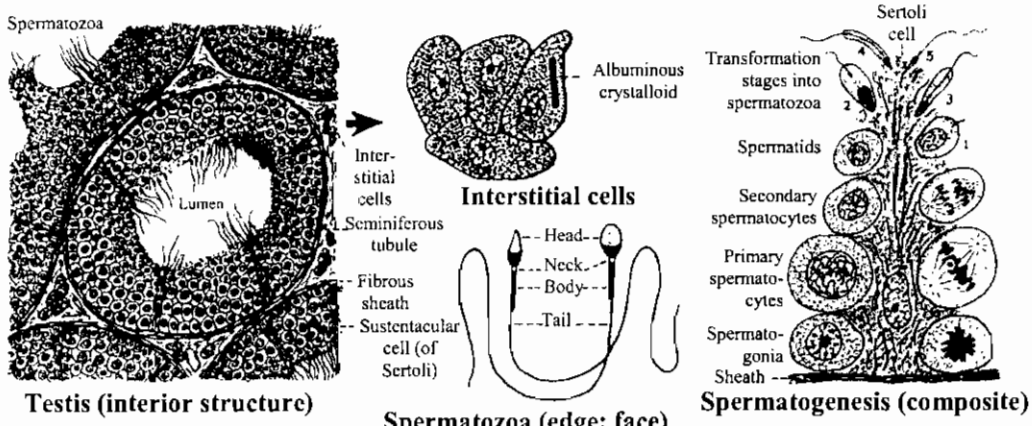
Ovum of a placental mammal. The ovum is a large cell with organelles. The plasma membrane projects as microvilli into the surrounding protein membrane, the zona pellucida. Follicle cells arise from the ovary in which the ovum initially resides

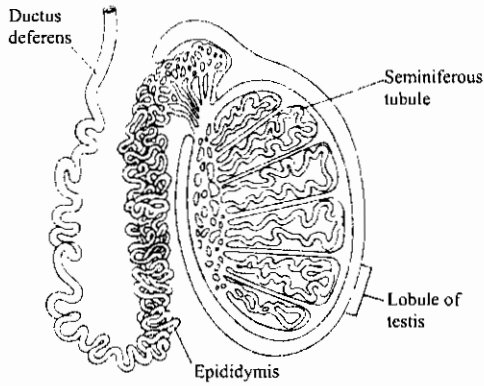
and, depending on the species, they may or may not accompany the ovum at ovulation. Processes of the follicle cells project to the surface of the ovum through the zona pellucida.

التركيب الدقيق للبيضة والمنطقة الشفافة وخلايا الحوصلة

Ultrastructure of the oocyte, zona pellucida and follicular cells

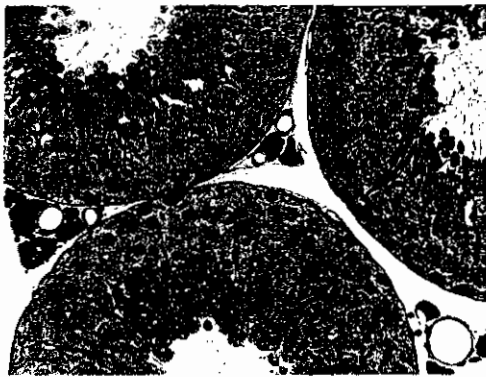
الأعضاء التناسلية الذكورية
The male reproductive organs





(a)

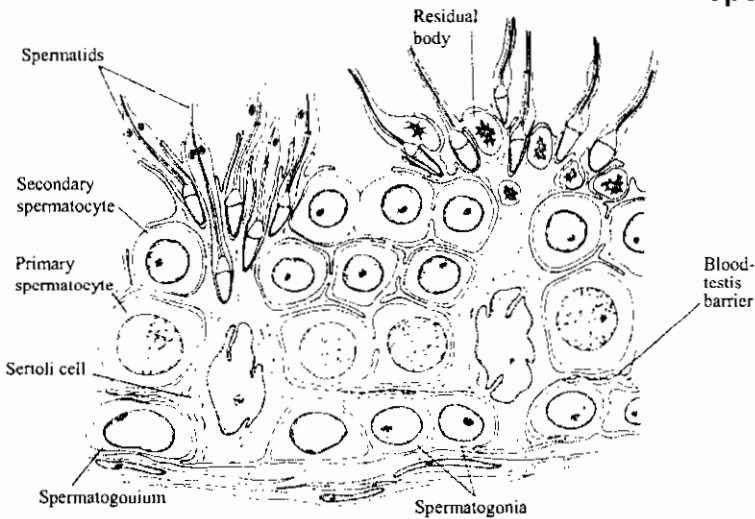
رسم تخطيطي للتركيب الطولي للخصية
Diagram showing a longitudinal structure of the testis



(b)

جزء من ق.ع. في الخصية
Part of a T.S. of the testis of man

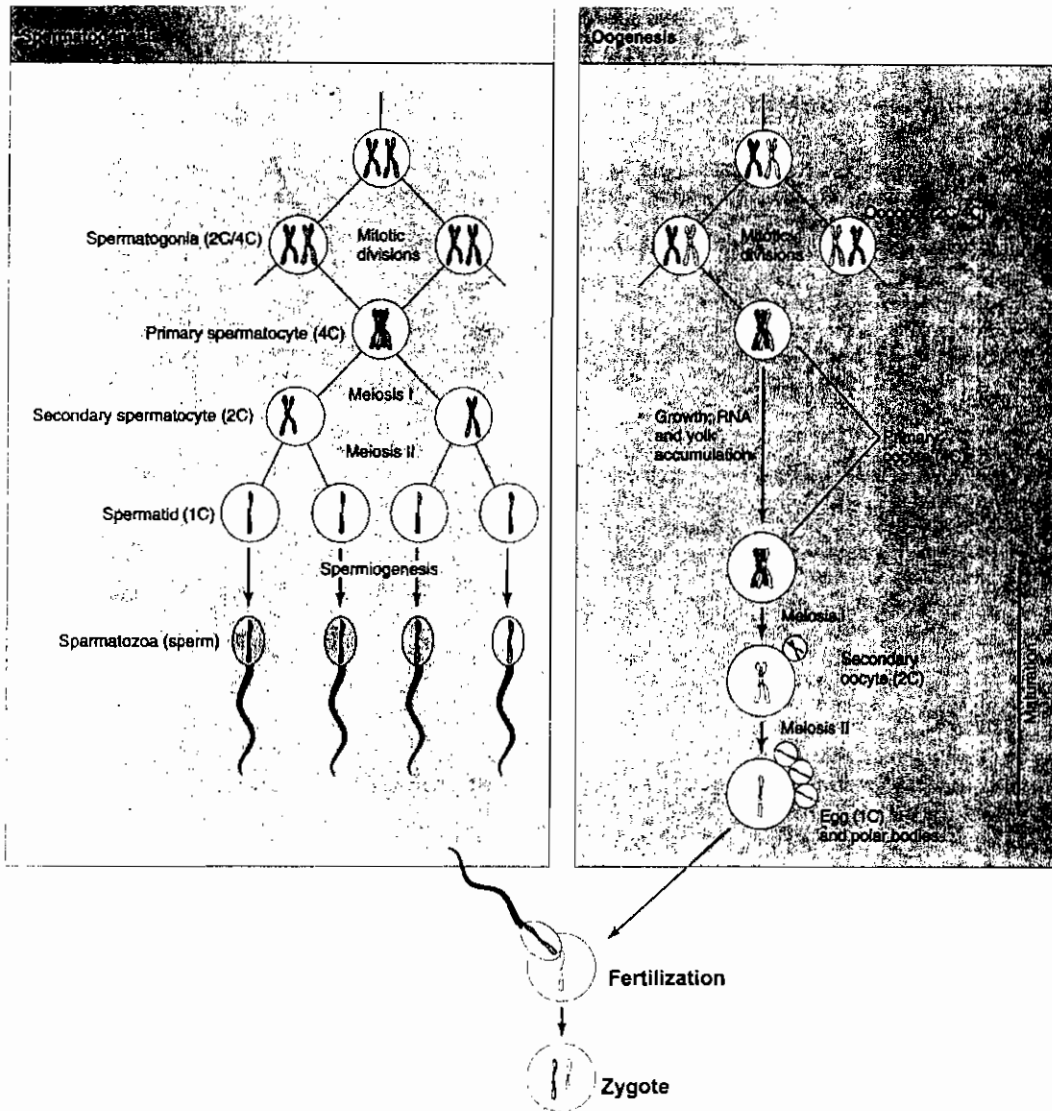
تكوين الحيوانات المنوية Spermatogenesis



(c)

Seminiferous tubules in the mammalian testis. (a) Schematic diagram of a testis. Each testis is divided into lobules containing seminiferous tubules. These tubules are connected via a network of collecting ducts and the epididymis to the ductus deferens, which joins the urethra. (b) Light micrograph showing partial cross sections of tubules and clusters of interstitial cells in the spaces between them. (c) Drawing of a section of a seminiferous tubule, showing Sertoli cells and germ cells at different stages of spermatogenesis.

تكوين الجاميتات
Gametogenesis

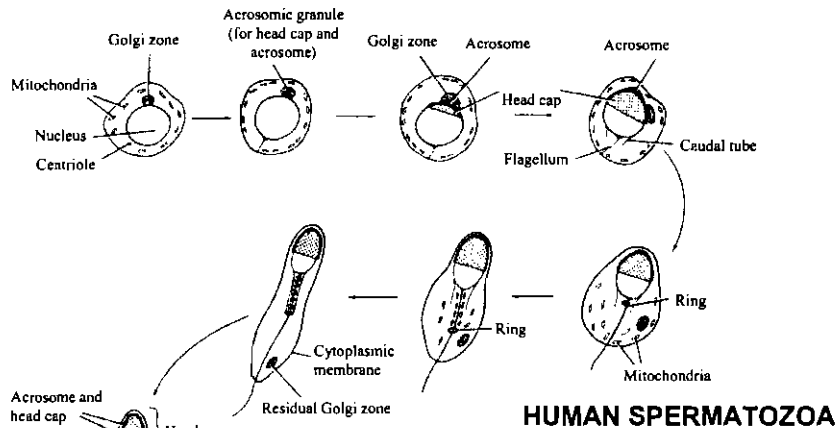


Comparison of spermatogenesis and oogenesis. Primordial germ cells divide mitotically, producing spermatogonia in males and oogonia in females. These cells are diploid, containing two or four genomes (2C or 4C), depending on their stage in the mitotic cycle. Before the gonia enter meiosis, their DNA replicates. They are then called primary spermatocytes or oocytes. After the first meiotic division, they contain two genomes (2C) and are called secondary spermatocytes or oocytes. After the second meiotic division, they are haploid (1C) spermatids or eggs. Note that the two rounds of meiosis produce four haploid spermatids, each of which develops into a spermatozoon, but only one egg results from meiosis of a diploid oogonium; the small polar bodies attached to the egg have no known function.

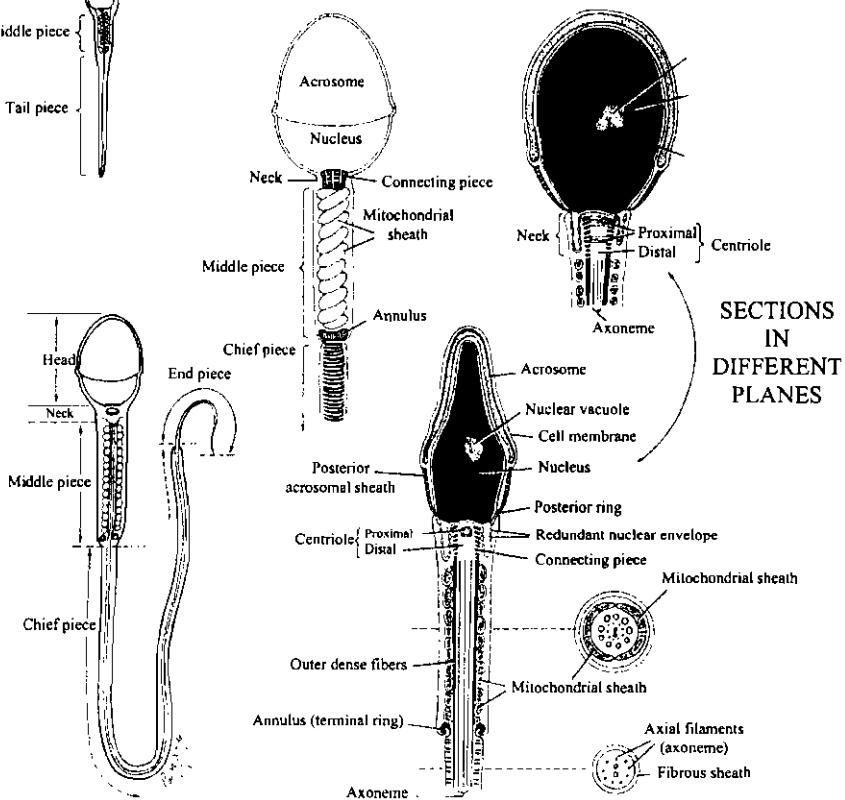
تكوين الحيوانات المنوية في الإنسان

Human Spermatozoa and spermiogenesis

SPERMIOGENESIS



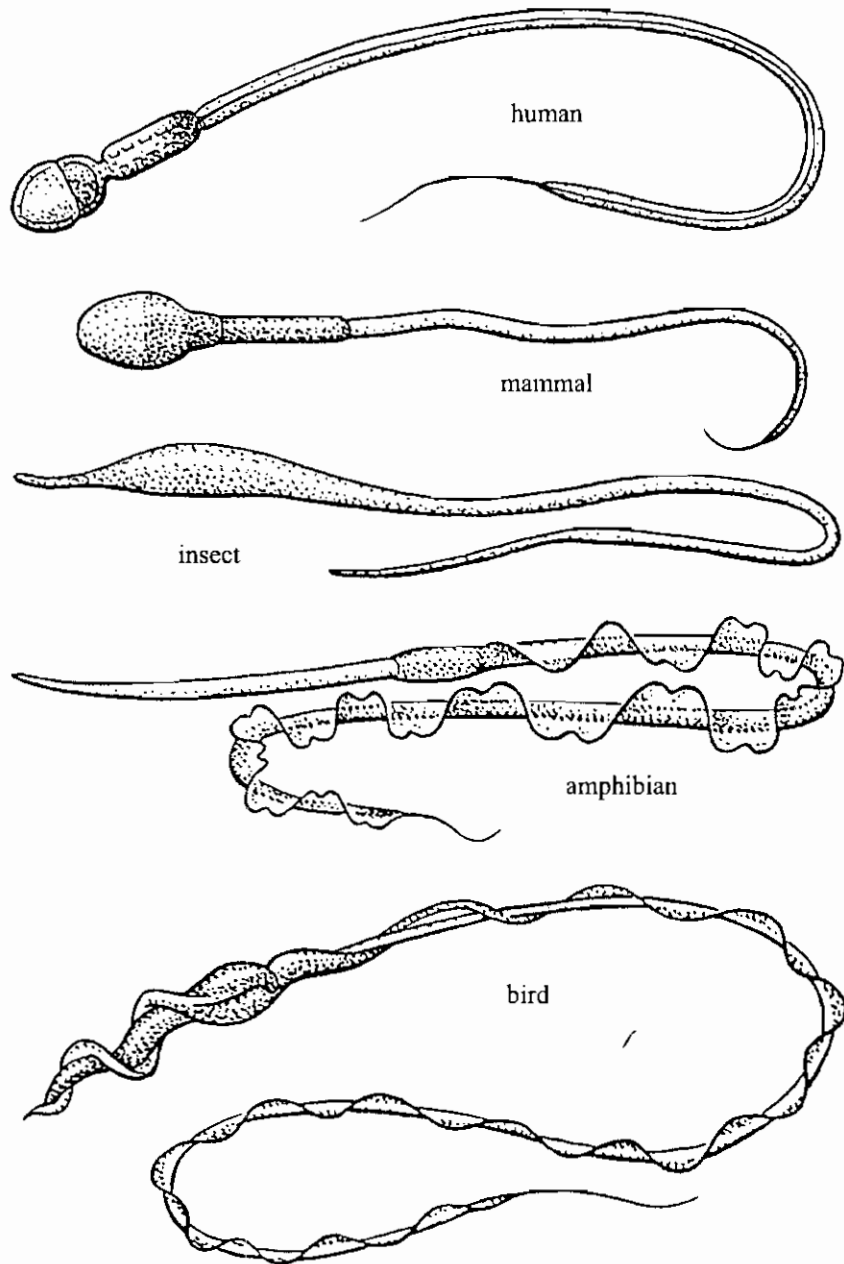
HUMAN SPERMATOZOA



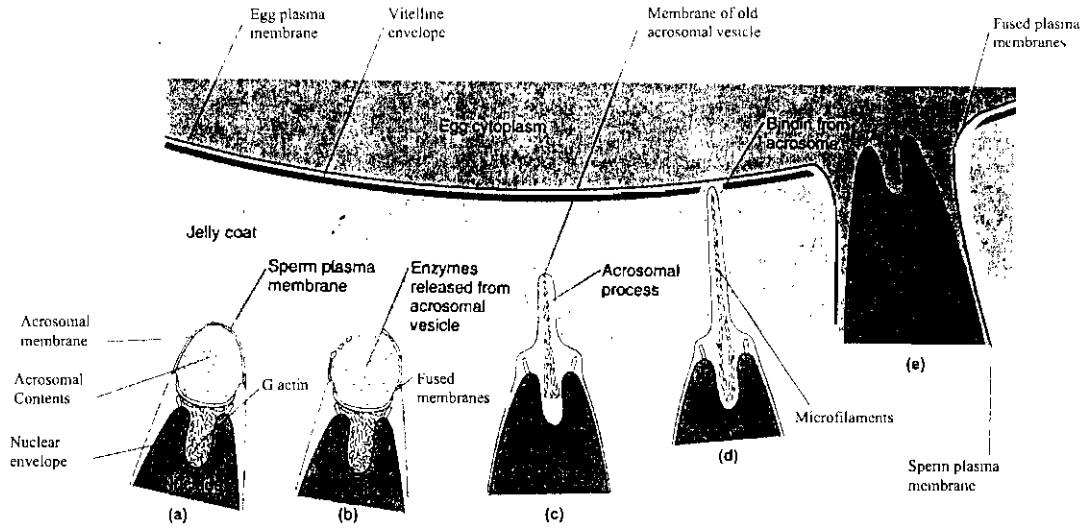
تركيب الحيوان المنوي الناضج

Structure of the mature spermatozoon

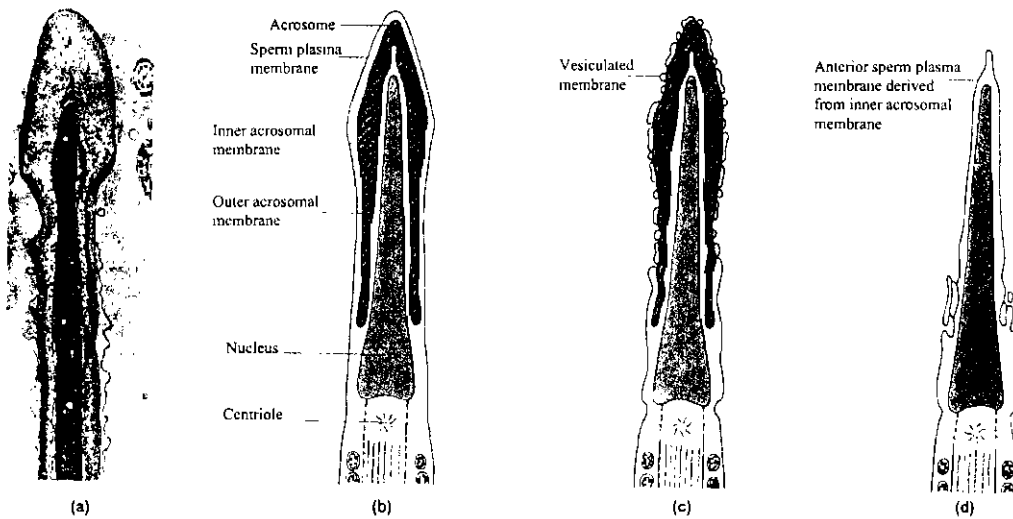
الاشكال المختلفة للحيوانات المنوية
VARIOUS SPERM



تفاعل الجسم القمي مع جدار البويضة أثناء الإخصاب

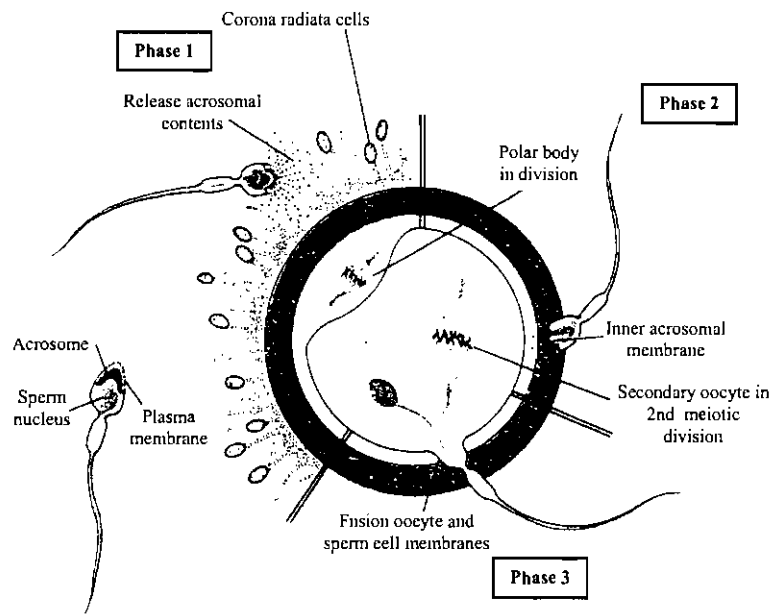


Acrosome reaction in sea urchin sperm. (a) Drawing of the head of an unreacted sperm, showing the nucleus surrounded by the nuclear envelope, the acrosomal material surrounded by the acrosomal membrane, and a subacrosomal space filled with G actin (short lines). The entire sperm is surrounded by the plasma membrane. (b) When the sperm contacts the jelly coat of the egg, the acrosomal vesicle (acrosome) undergoes exocytosis. Proteins (small dots) released from the acrosomal vesicle dissolve the jelly coat. (c) The acrosomal process extends and remains covered with acrosomal material, which adheres to the vitelline envelope. (d) Sperm-egg plasma membrane contact after lysis of the vitelline membrane. Bindin is the substance that enables the sperm to adhere to the egg. (e) Plasma membrane fusion and beginning of sperm entry into the egg.


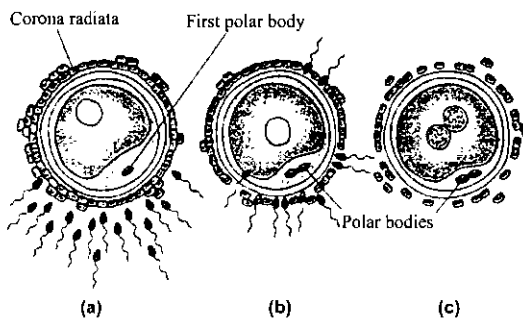


Acrosome reaction in mammals. (a) Transmission electron micrograph of a hamster sperm before the acrosome reaction. A = acrosome. (b) Drawing of sperm head before acrosome reaction, with sperm plasma and acrosomal vesicle intact. (c) During the acrosome reaction, the sperm plasma membrane and the outer acrosomal membrane fuse at many places, forming numerous vesicles. (d) The anterior sperm plasma membrane, visible after the acrosome reaction, is derived from part of the inner acrosomal membrane.

Fertilization الإخصاب



Schematic representation of the three phases of oocyte penetration. In phase 1 the spermatozoa break through the corona radiata barrier; in phase 2 one or more spermatozoa penetrate in the zona pellucida; in phase 3 one spermatozoon penetrates through the oocyte membrane, thereby losing its own plasma membrane.



(d)

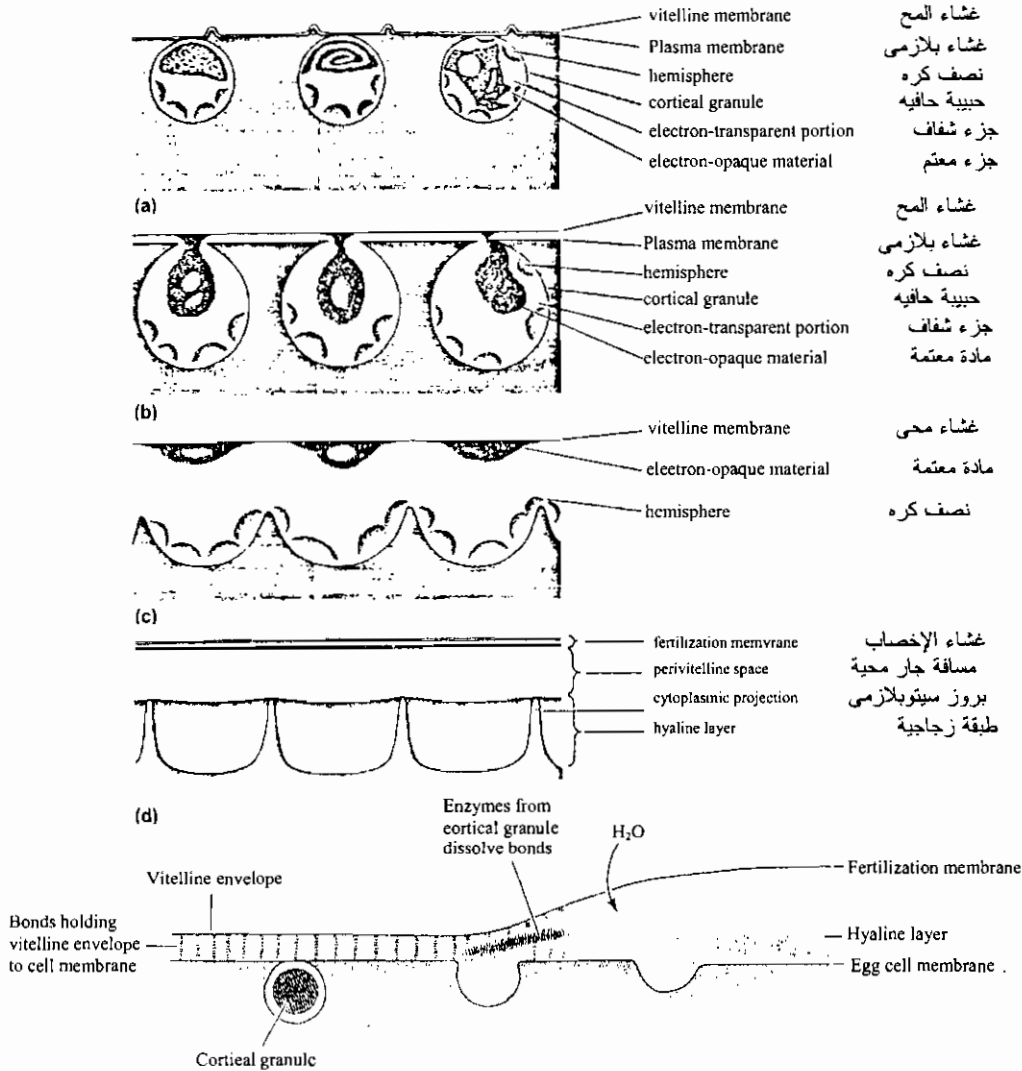
Fertilization. (a) Each sperm is thought to release a small amount of enzyme that helps to disperse the follicle cells surrounding the ovum. (b) After a sperm cell enters it, the oocyte completes its second meiotic division, producing an ovum and a polar body. (c) Pronuclei of sperm and ovum combine, producing a zygote with the diploid number of chromosomes. (d) A scanning electron micrograph of a sperm cell fertilizing a hamster ovum. (d, David Phillips/Visuals Unlimited).

تكوين الحبيبات الحافية

Formation of the cortical granules

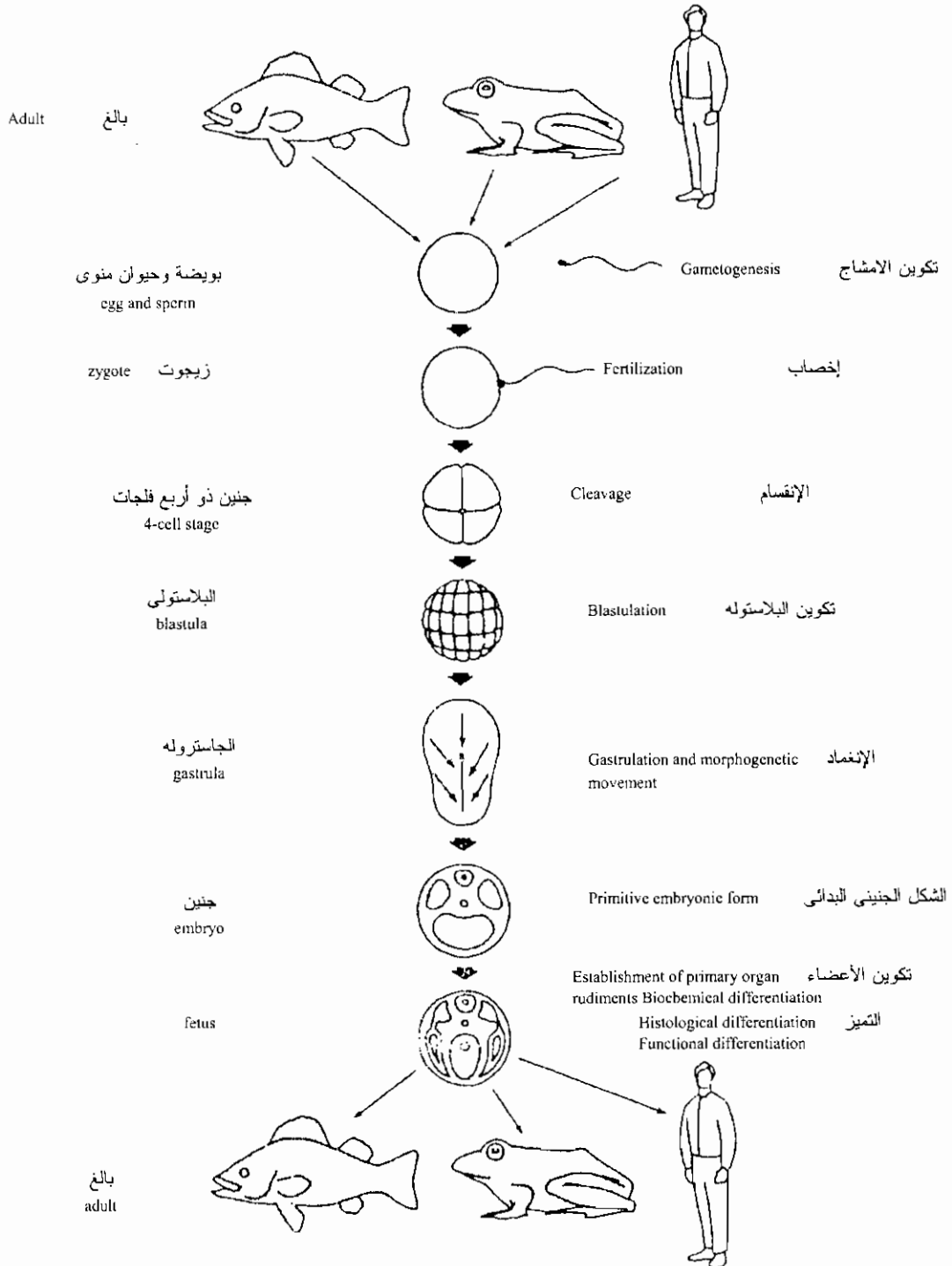
Cortical reaction and fertilization-membrane elevation in the sea urchin

Japonicus. A Unfertilized egg. b Fusion of egg plasma membrane and membrane of cortical granule with beginning of release of granule contents. c Adhesion of electron-opaque material to the vitelline membrane now lifted up; complete fusion of this material with the membrane will give rise to the fertilization membrane. Other material of the cortical granules is expelled into the perivitelline space, while other contents remain close to the egg surface to form the hyaline layer. d The egg surface upon completion of the events. [After Y. Endo, Exp. Cell Res., 25:383 (1961).]



Schematic diagram showing the events leading to the formation of the fertilization membrane and the hyaline layer. As cortical granules burst, they release peptidases, which cleave the bonds joining the vitelline envelope to the cell membrane. Mucopolysaccharides released by the cortical granules form an osmotic gradient, thereby causing water to enter and swell the space between the vitelline envelope and the cell membrane. Other enzymes released from the cortical granules act to harden the fertilization membrane and to release sperm bound to it. (Modified from Austin, 1965.)

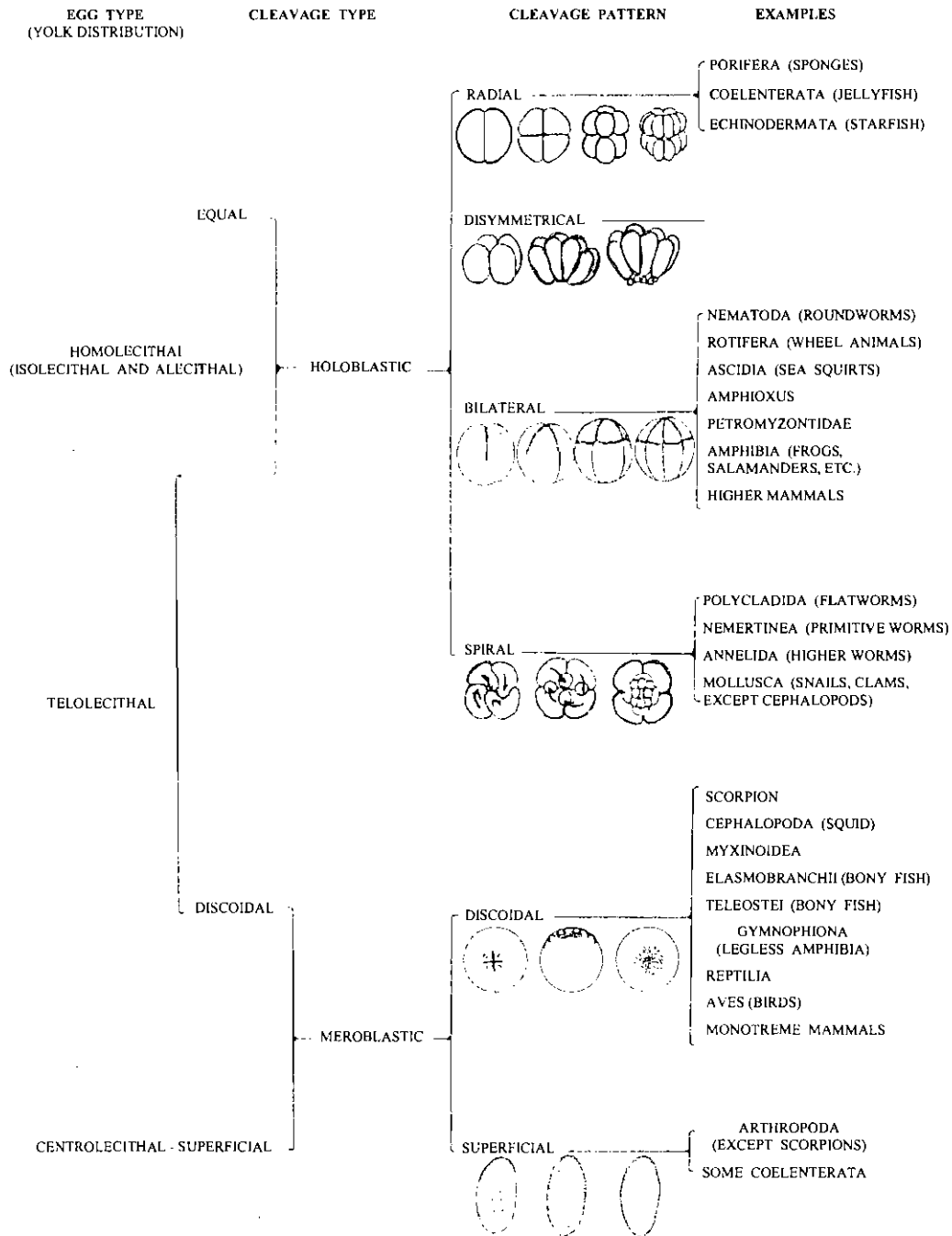
مراحل تكوين الحيوان الفقاري حتى مرحلة النضج الجنسي



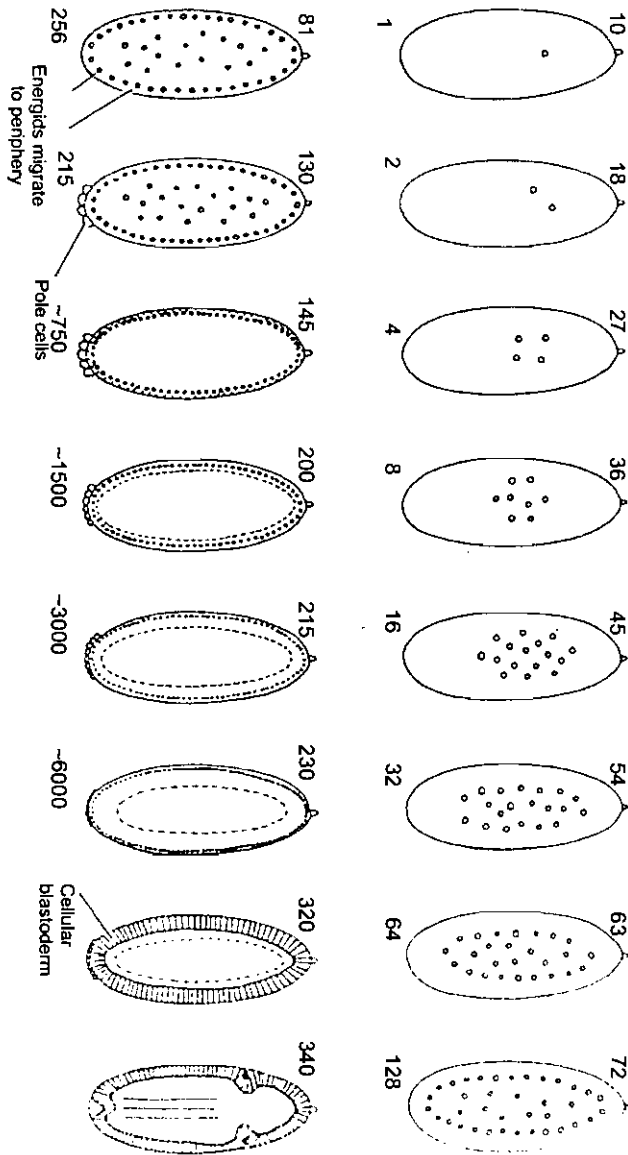
Summary of the common developmental processes that lead to the formation of adult vertebrate organs

أنماط البيض وأنواع التفليج في الحيوانات المختلفة

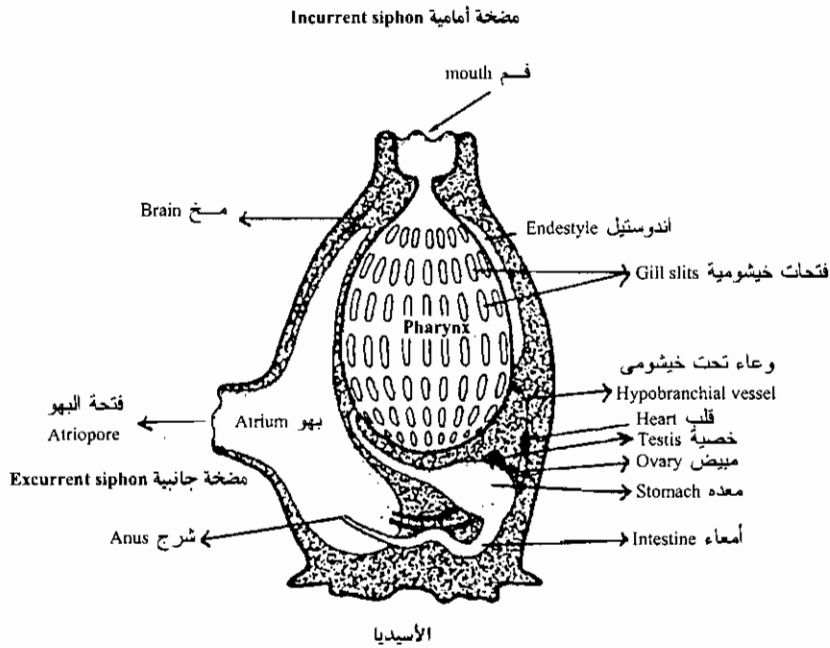
CLASSIFICATION OF EGG AND CLEAVAGE TYPES



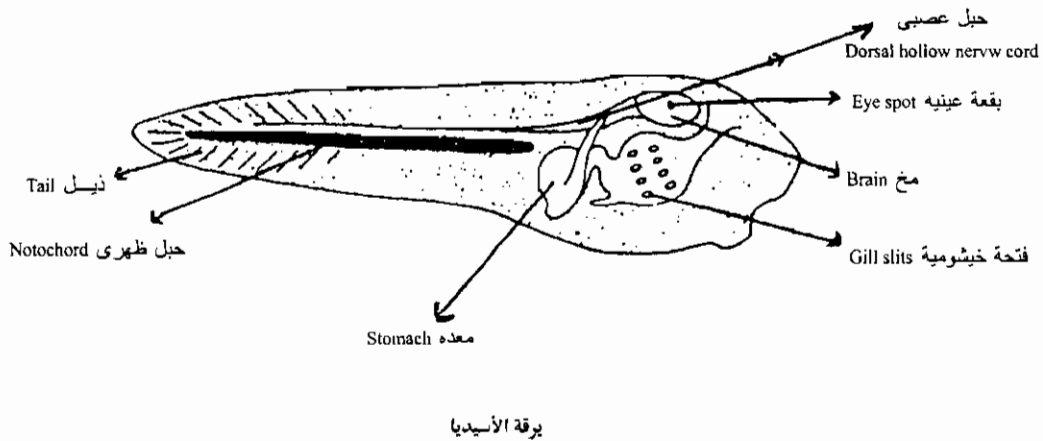
التفليج السطحي في جنين حشرة الدروسوفيليا



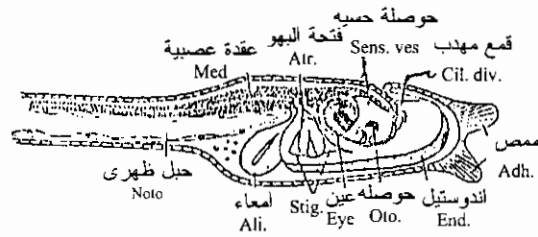
Superficial cleavage in a *Drosophila* embryo. The numeral above each embryo corresponds to the number of minutes after deposition of the egg; the numeral at the bottom indicates the number of nuclei (energids) present. Pole cells (which will form the germ cells) are seen at the 512-nuclei stage even though the cellular blastoderm does not form until nearly 3 hours later. (Modified from Zalokar and Erk, 1976.)



Mature tunicate. Water and food are taken into the large barrel-shaped pharynx by way of the incurrent siphon. The food is mixed with mucus and enters the stomach; the water moves through the gill slits into the atrial cavity, eventually passing to the outside by way of the excurrent siphon.

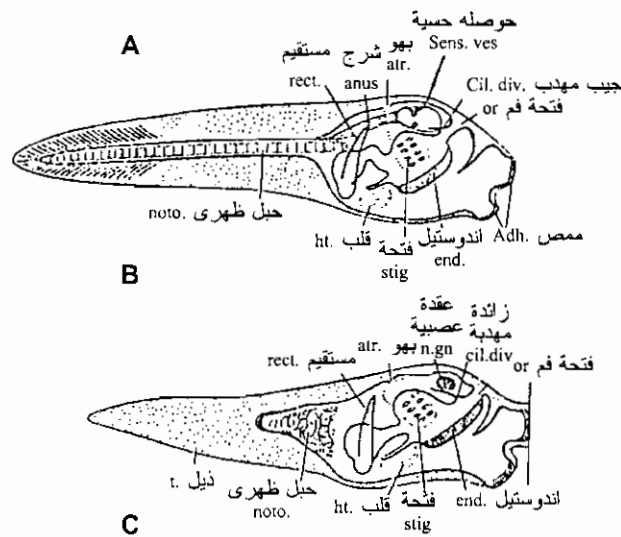


“Tadpole” larva of some tunicates has a tiny brain and a dorsal hollow never cord. A notochord is present in the well developed tail and gill slits in pharynx. After swimming about, the larva attaches itself to a suitable substratum. Undergoes metamorphosis, and develops into the sessile adult.

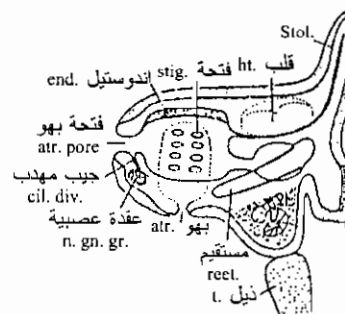


يرقة الأسيديا

Ascidia: Development, Free-swimming larva of *Ascidia mummillata*, lateral view. adh. Adhesive papillae; ali. alimentary canal; atr. Atrial aperture; cil. div. Ciliated diverticulum. becoming ciliated funnel; end. endostyle; eye; med. nerve-cord (ganglion of trunk); noto. notochord; oto. otocyst; sens. ves. sense-vesicle; stig. earliest stigmata. (From Korschelt and Heider, after Kovalevsky.)



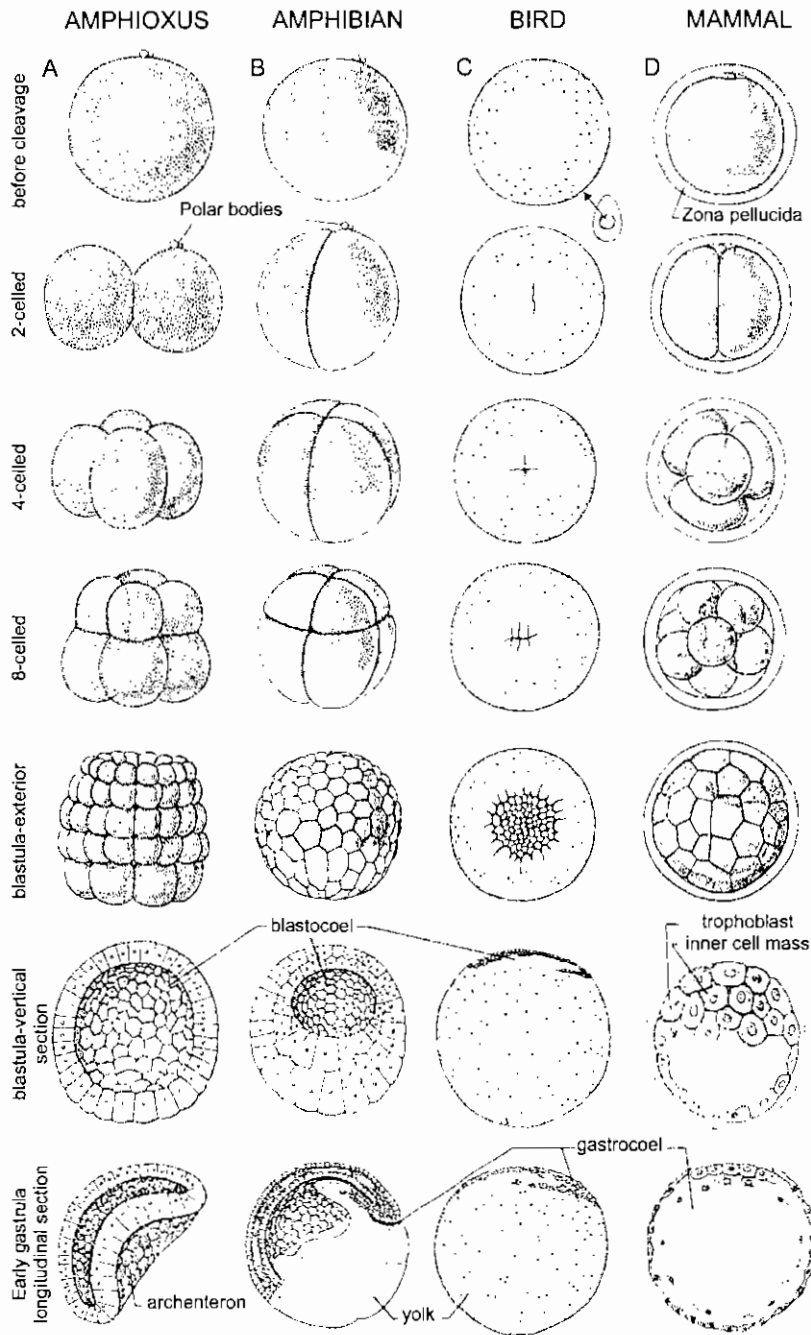
C



نمو الأسيديا

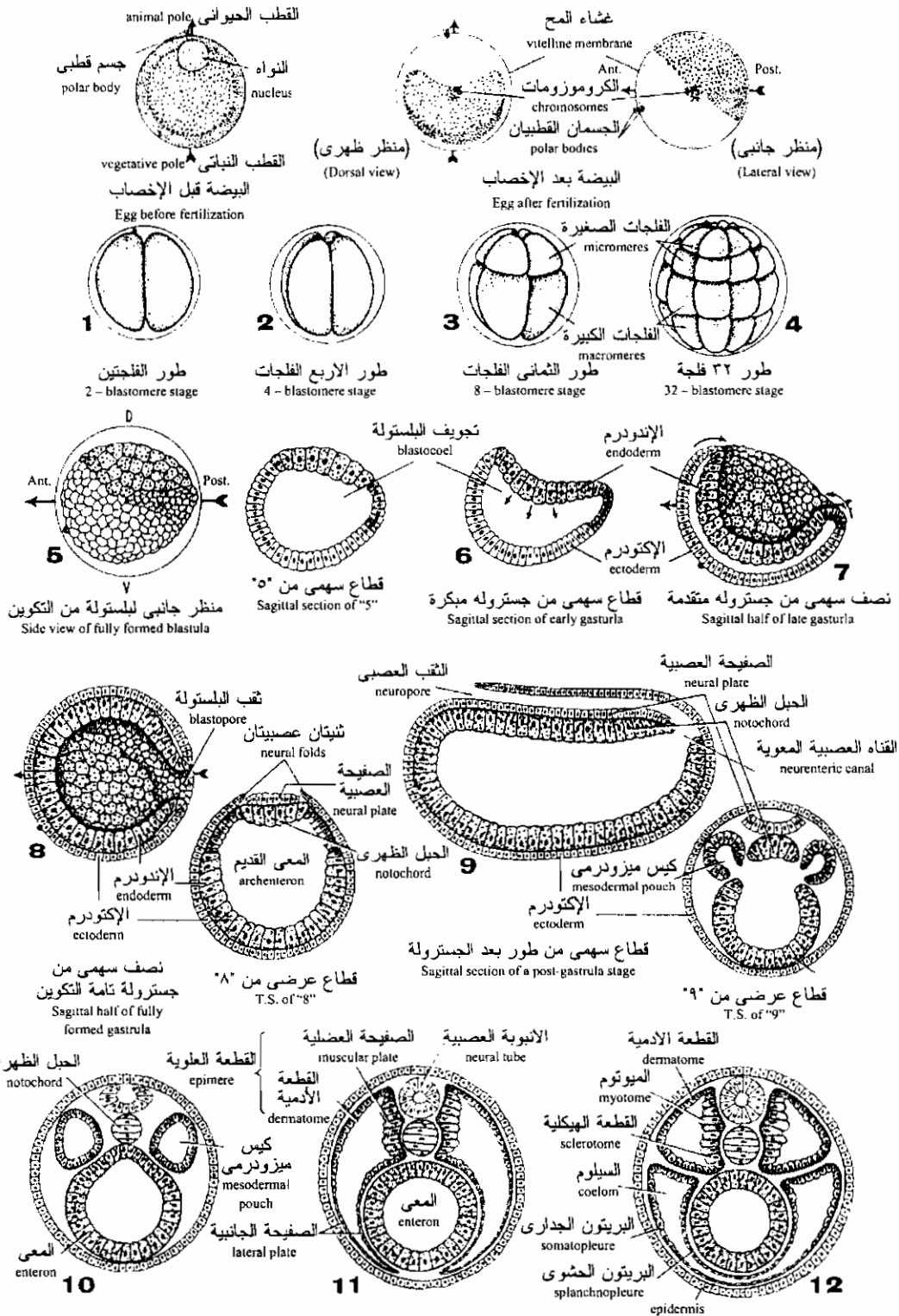
Ascidia: Development, Metamorphosis of the free-tailed larva into the fixed ascidian. A., stage of free-swimming larva; B, larva recently fixed; C, older fixed stag. Adh. Adhesive papilla; atr. Atrial cavity; cil. div. Ciliated diverticulum. becoming ciliated funnel; end endostyle; t, heart; med. ganglion of trunk; n. gn. nerve-ganglion; notochord; or. oral aperture; rect. rectum; sens. ves. sense-vesicle; stig. stigmata; stol. stolon; t. tail. (From Korschelt and Heider, after Seeliger.)

مقارنة التفليج والتبطين في بعض الحلييات

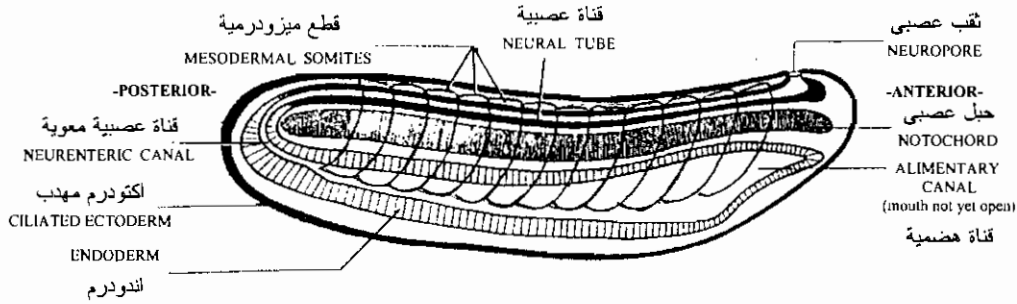


Sample stages of cleavage and gastrulation in eggs of chordates. A. amphioxus, cleavage holoblastic, little yolk; egg diameter 0.1 mm. (After Hatschek.) B. Amphibian (frog), modified holoblastic cleavage, much yolk; diameter 2 mm. (Various sources.) C. Bird, meroblastic discoid cleavage in small blastodisc on large yolk mass; diameter 30 mm. (After Blount; and Patten, *Early embryology of the chick*, McGraw-Hill Book Company.) D. Mammal, cleavage holoblastic, practically no yolk; an outer trophoblast and an inner cell mass formed in blastula; gastrula formed by migration of endoderm cells from inner cell mass (involution); egg surrounded during early cleavage by zona pellucida (from Graafian follicle of ovary), which later disappears. (After Gregory; and Patten, *Embryology of the Pig*, McGraw-Hill Book Company.)

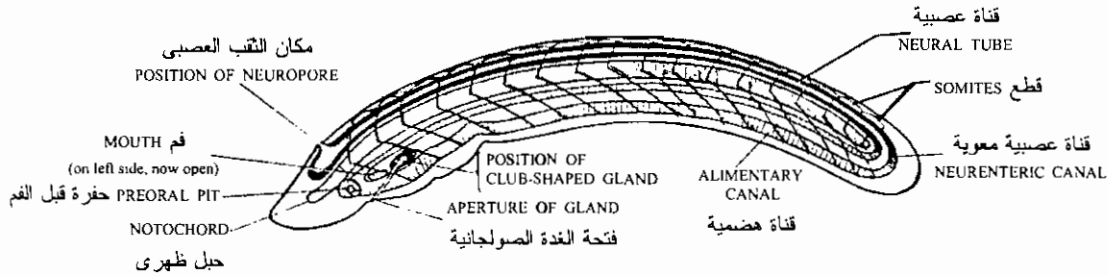
أطوار التكوين الجنيني المبكر للسهم
 EARLY DEVELOPMENTAL STAGES OF AMPHIOXUS



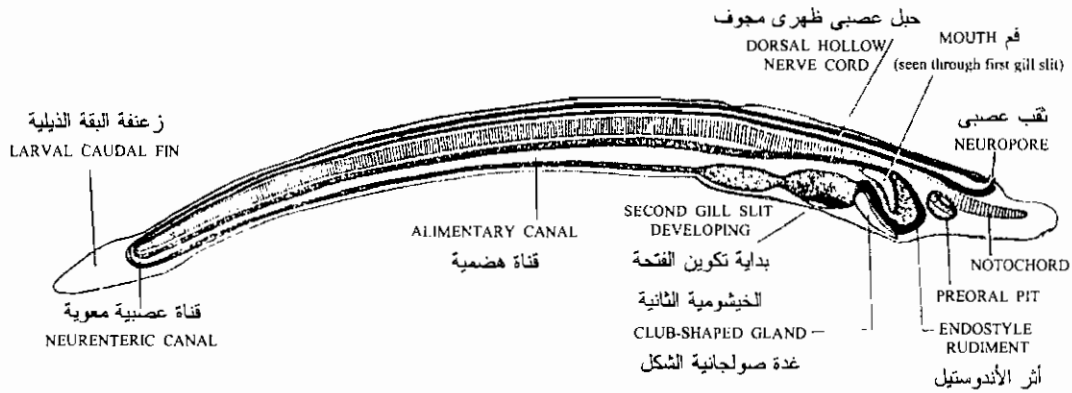
قطاعات عرضية من أطوار بعد الجسترولة
 T. S. of post-gastrula stages



رسم تخطيطي لمرحلة إثني عشر فلجة
Diagram of 12 – somite stage



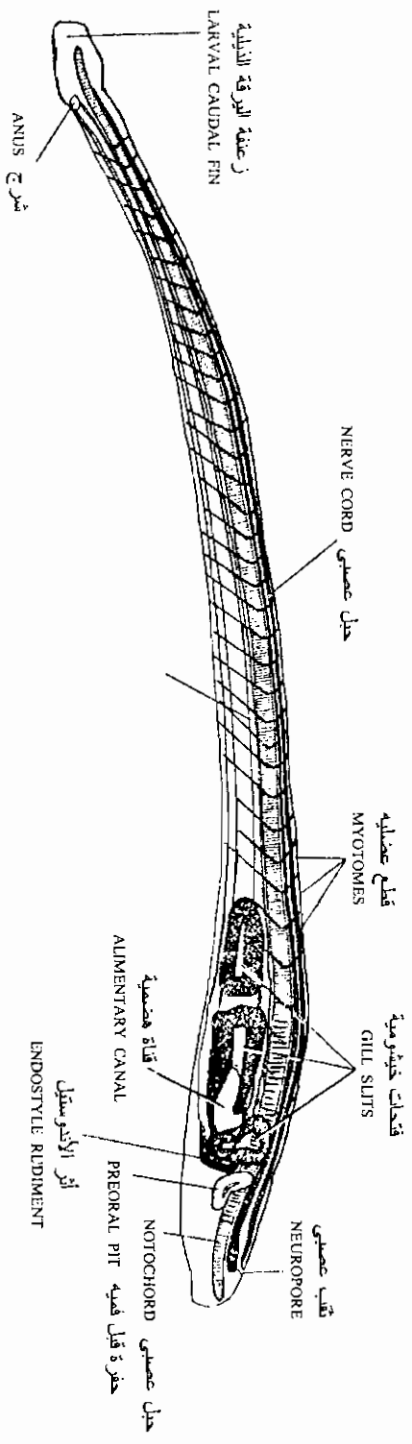
رسم تخطيطي لمرحلة سبعة عشر فلجة
Diagram of a 17 somite stage



رسم تخطيطي لمرحلة الجنين ذو الفتحتين الخيشوميتين
Diagram of two gill slit stage



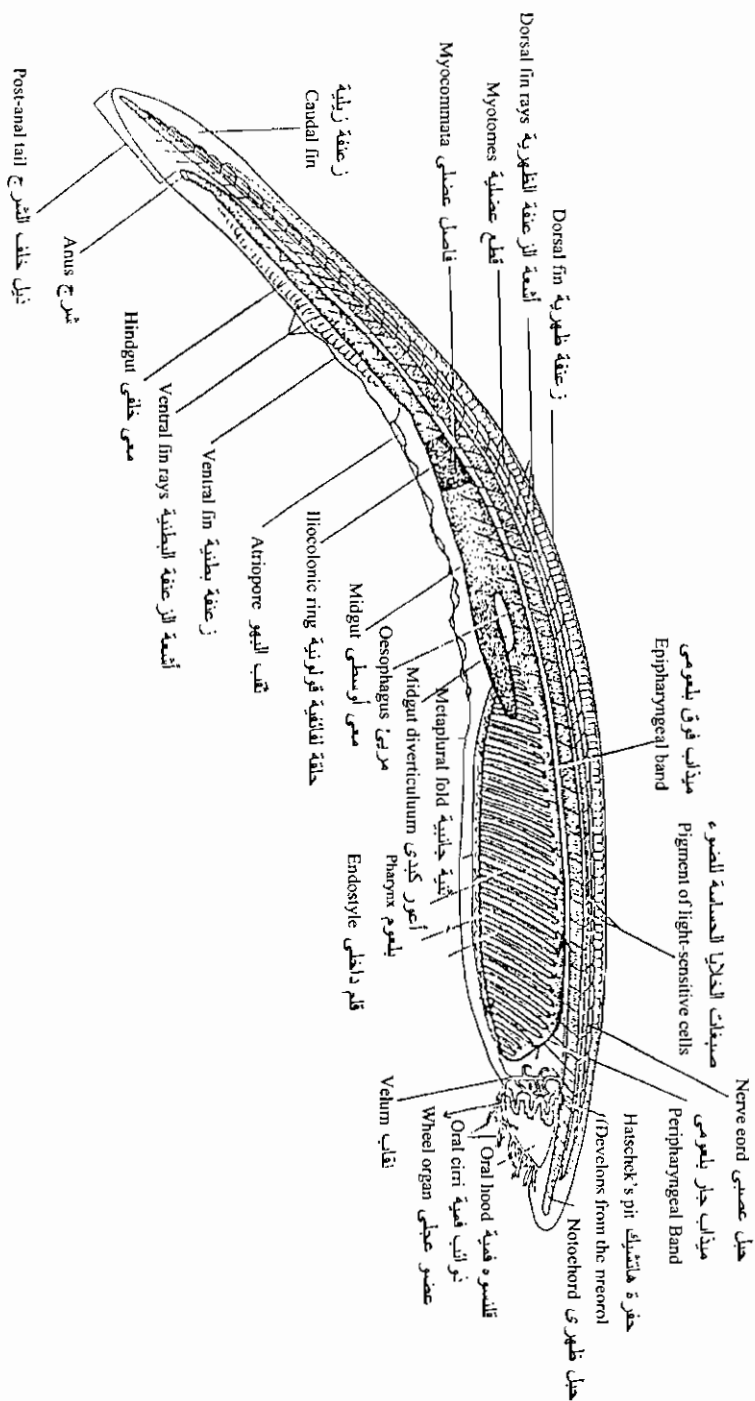
السهم: يرقة متأخرة (تكبير ٢٥ مرة)
 Amphioxus: late larva, E. mag. 250x

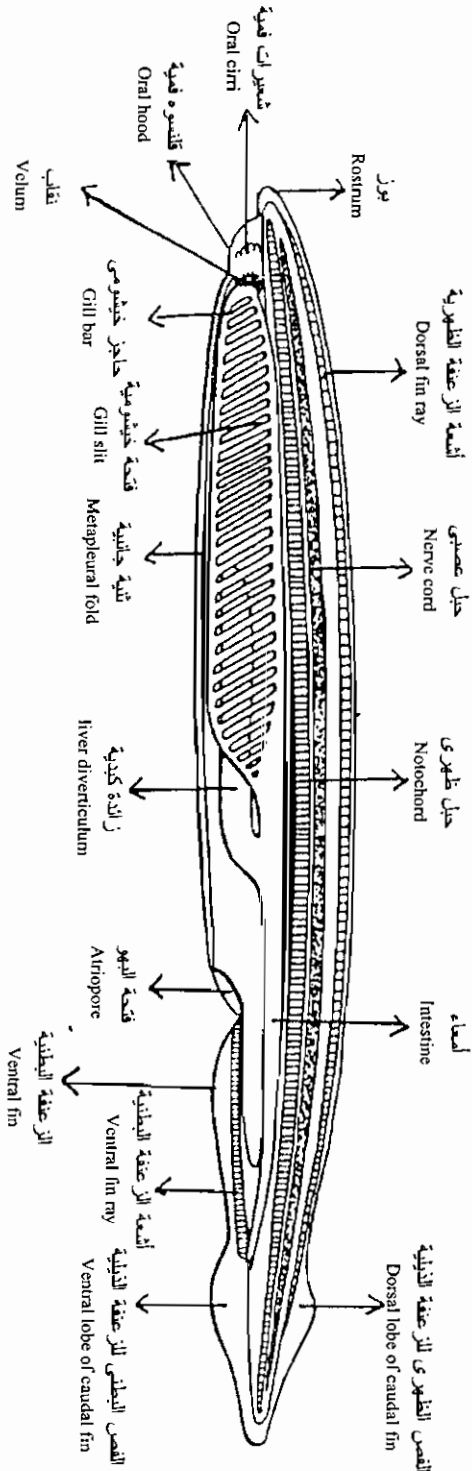


رسم تخليطي ليرقة ذات ثلاث فتحات خيشومية
 Diagram of 3 gill slit stage

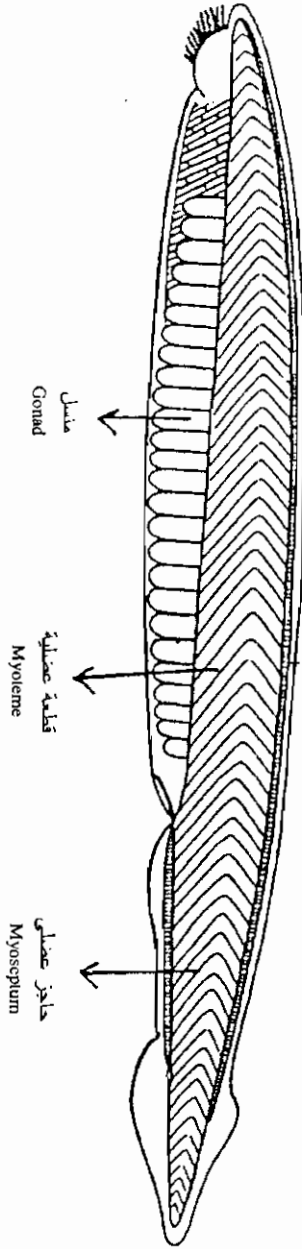
منظر جانبي لسهيم صغير في السن (بعد نزع جدار الجسم)

Young amphioxus



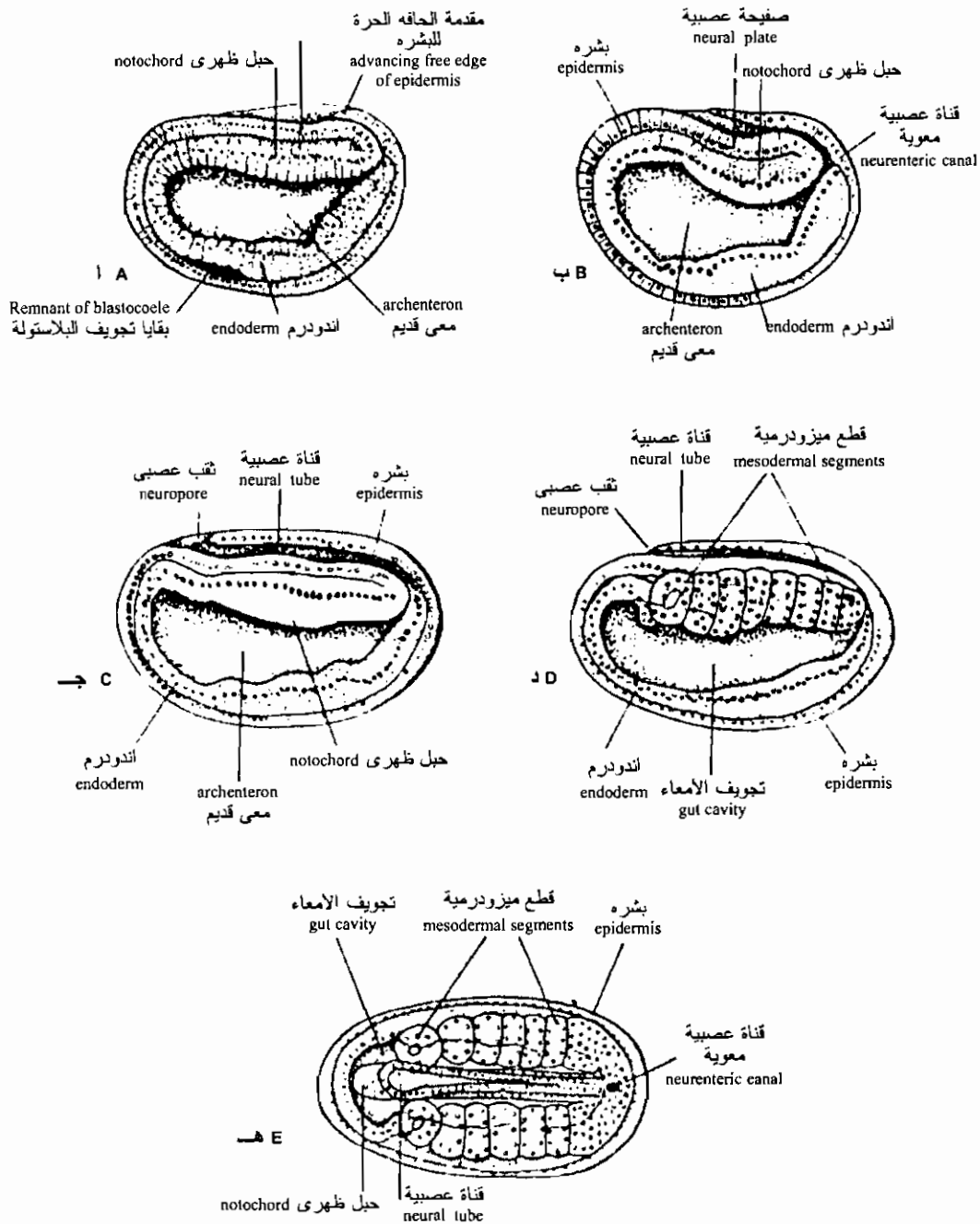


السهم: منظر جانبي للتركيب الداخلية
 Amphioxus. Longitudinal diagram of internal structure.

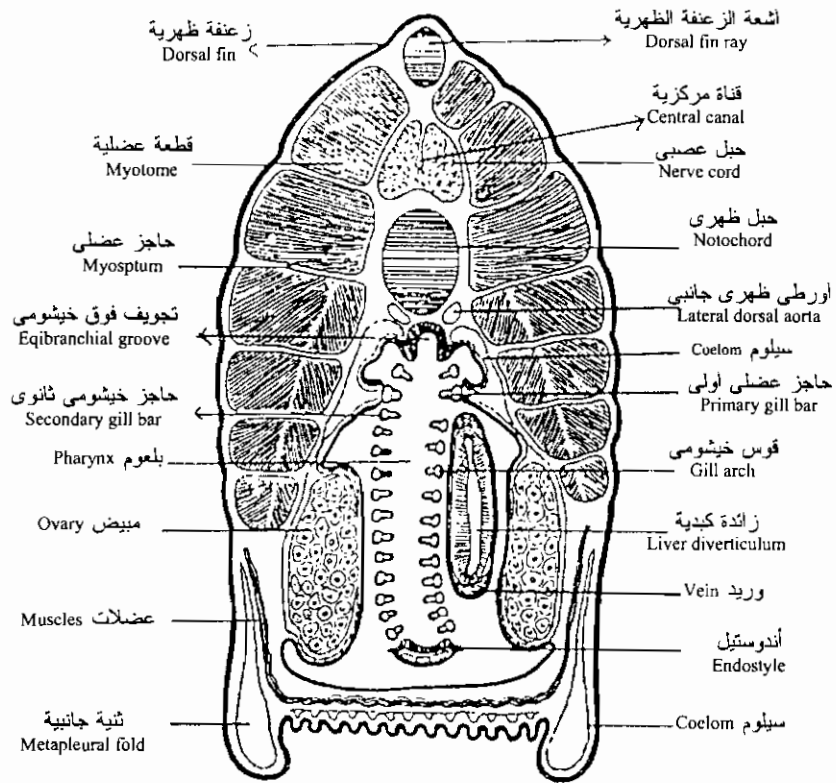


السهم: شكل خارجي
 Amphioxus. External view.

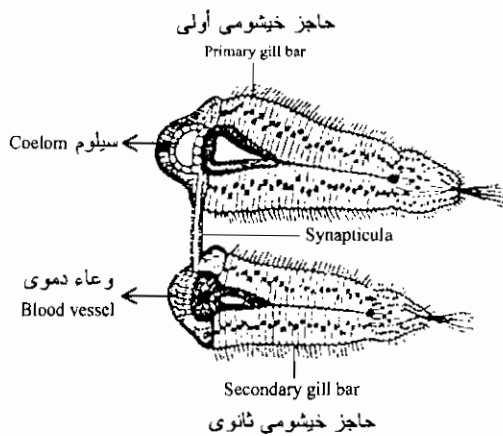
مراحل تكوين الأنبوبة العصبية في السهيم كما تظهر في مقاطع طولية للجسم



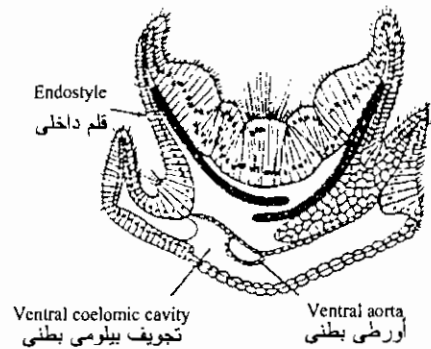
Stages of neurulation of Amphioxus. In A, B, and C the embryos are represented as being cut in the median plane. A Earliest stage of neurulation. C, almost completed neurula; D, slightly later stage than C but cut paramedially so that the right row of mesodermal segments can be seen; E, completed neurula whole, seen from the dorsal side. The transparency of the embryo allows one to see at the same time the various parts superimposed over one another (neural tube notochord mesodermal segments and gut). (From Conklin. 1932).



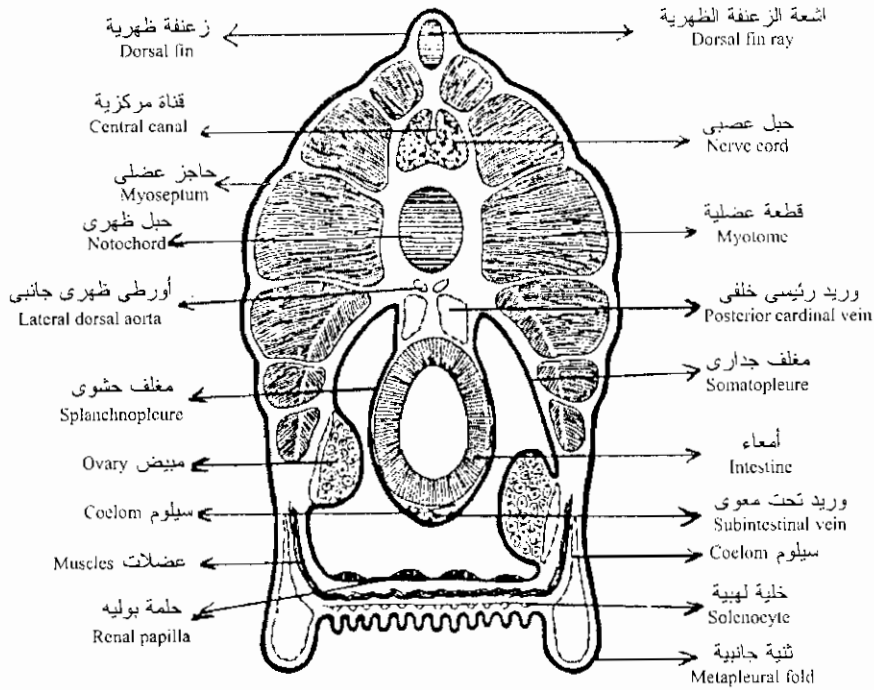
السهم: قطاع عرضي في المنطقة الخلفية للبلعوم
Amphioxus. Cross Section through the Posterior Region of the Pharynx



الحواجز الخيشومية
Gill bars (enlarged)

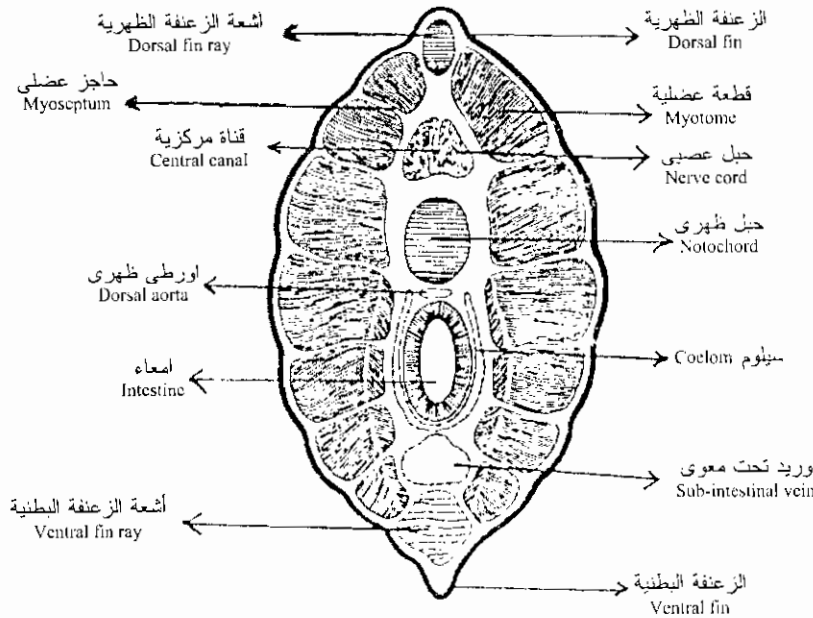


الإندوستيل
Endostyle (enlarged)



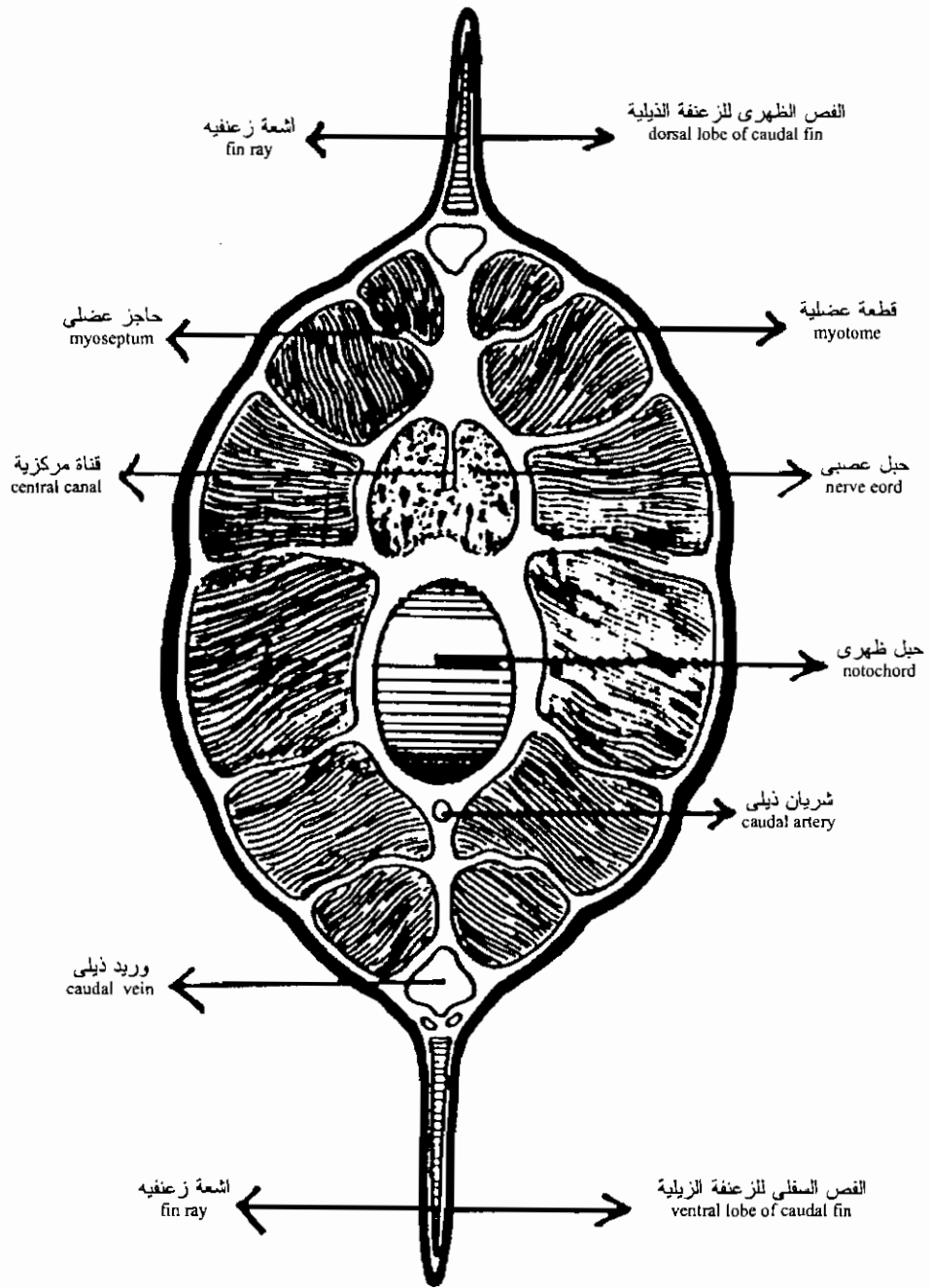
السهم: قطاع عرضي في منطقة الأمعاء

Amphioxus. Cross section through region posterior to pharynx.

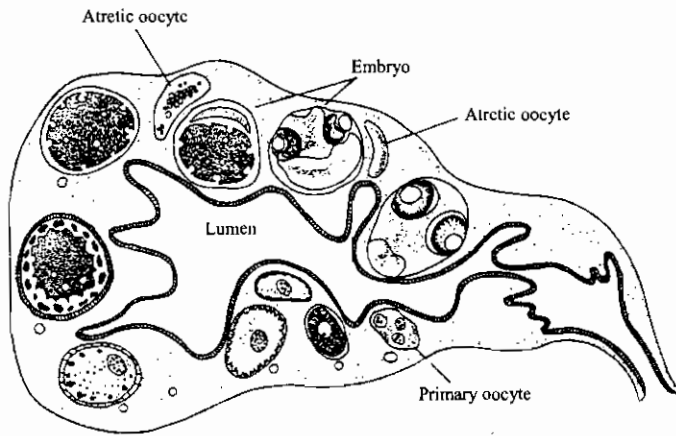
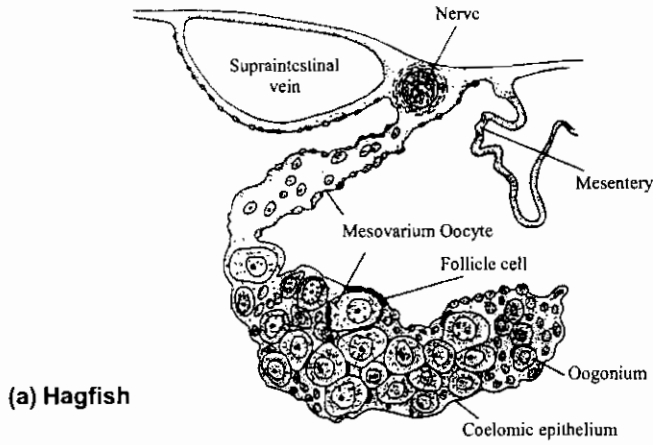


السهم: قطاع عرضي في منطقة الأمعاء خلف البهو

Amphioxus. Cross section through region posterior to artil pore.

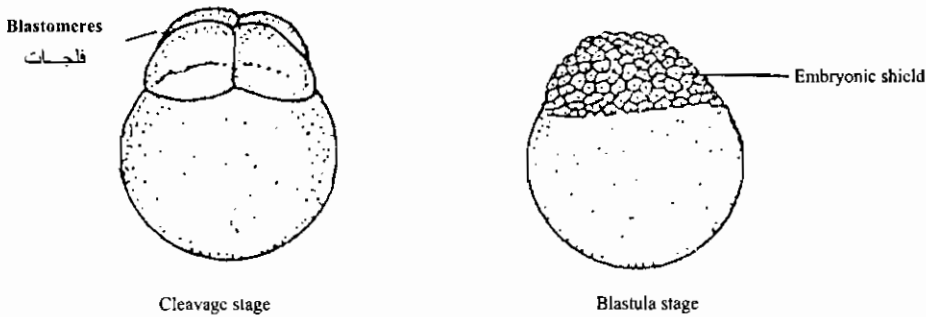


السهم: قطاع عرضى فى منطقة الذيل
Amphioxus. Cross section through region posterior to anus.



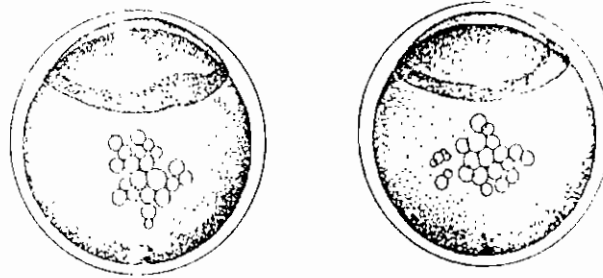
Fish ovaries. (a) Hagfish. Oocytes and surrounding follicle cells are held within the ovary. (b) Teleost. Section of the ovary of the guppy *Poecilia reticulata*. Ova are fertilized while they are within the ovary, and they are

retained well into embryonic development. There can be one to seven oocytes in progressive stages of development. Atretic oocytes that fail to develop and developing embryos are illustrated.

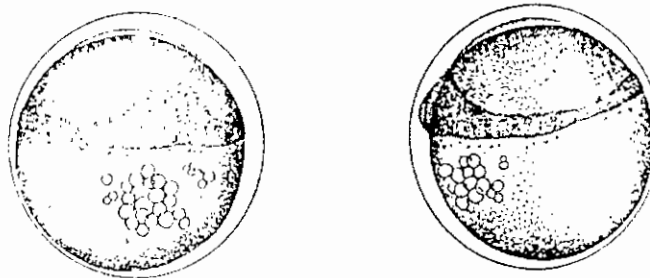


تكوين الجاستروله في الأسماك العظمية

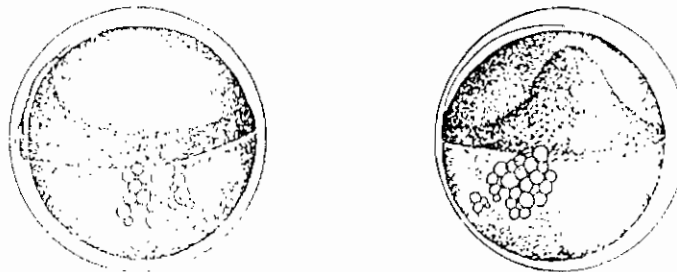
Gastrulation



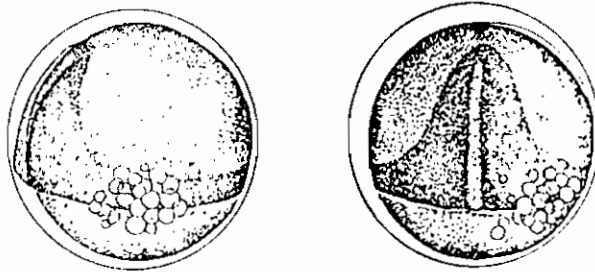
As the blastoderm continues to expand over the yolk, its cells pile up at the periphery at the expense of the centre. The central thin area of the blastoderm is the extra-embryonic membrane which will form yolk sac epithelium. The thickened rim is the germ ring. The thickening of the rim is greater at one portion of the blastoderm. Forming the embryonic shield. This is the region of the future embryo, and it is here that gastrulation begins.



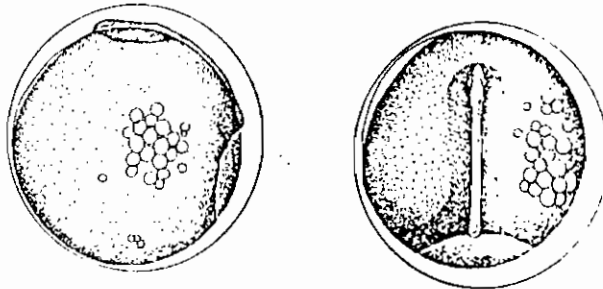
As gastrulation continues, the embryonic shield enlarges by the addition of cells anteriorly, laterally and posteriorly. There is a further accumulation of fine droplets at the vegetal pole, at the future site of the closure of the blastopore.



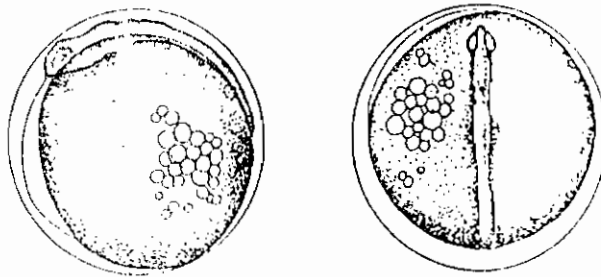
The gastrula has expanded to cover one-half of the yolk. The germ ring is little if any wider but the embryonic shield and axis have extended with epiboly. The latter is about one-sixth the circumference of the egg in length. (A refractive streak of cells is visible in the midline of the shield; this is the solid keel which forms the beginning of the central nervous system.)



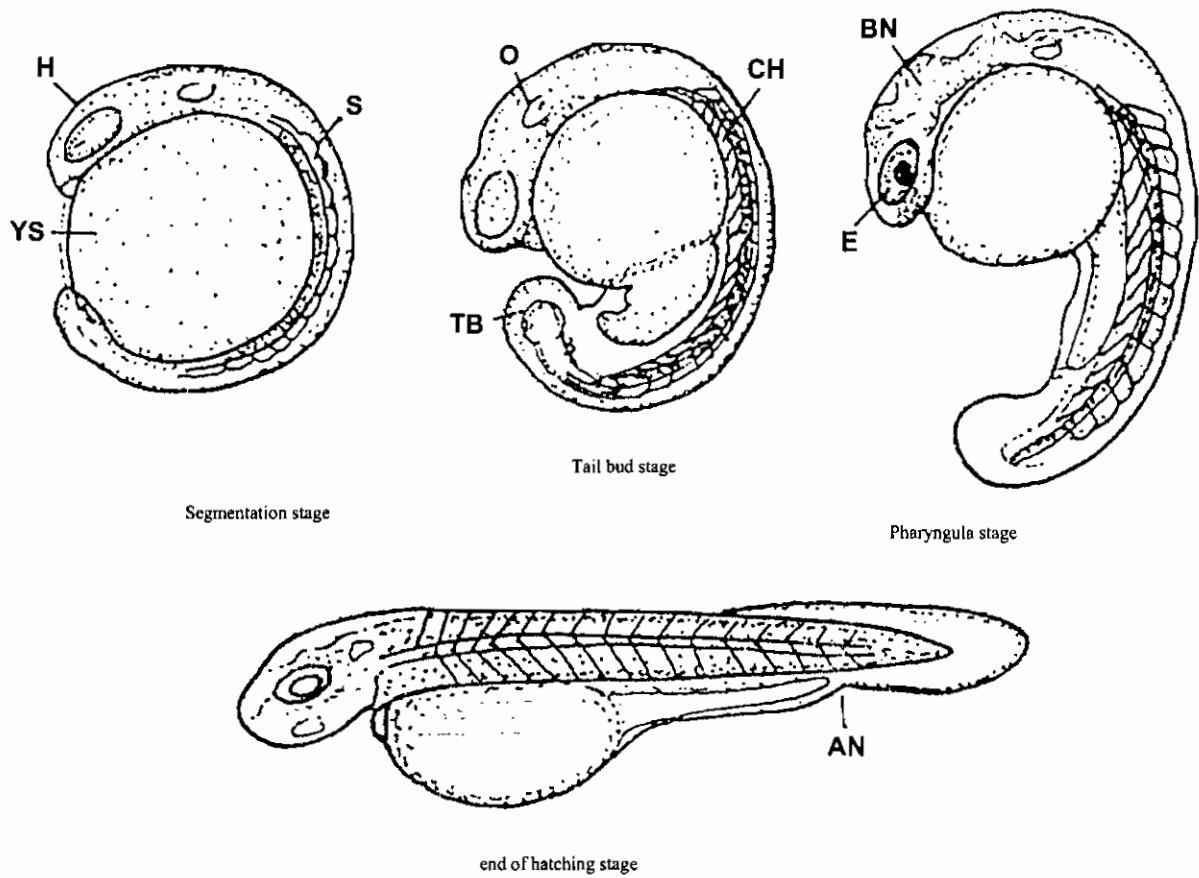
The extra-embryonic ectoderm covers three-fourths of the surface of the yolk. (As the blastoderm continues to expand over the yolk, gastrulation continues, and the shield narrows; the keel of the central nervous system is more clearly marked.)



The blastopore is reduced to a small opening through which the yolk may bulge. The embryonic axis is well defined with some condensation of tissue along its lateral margins. The optic vesicles are present but rudimentary. The embryonic keel is prominent.

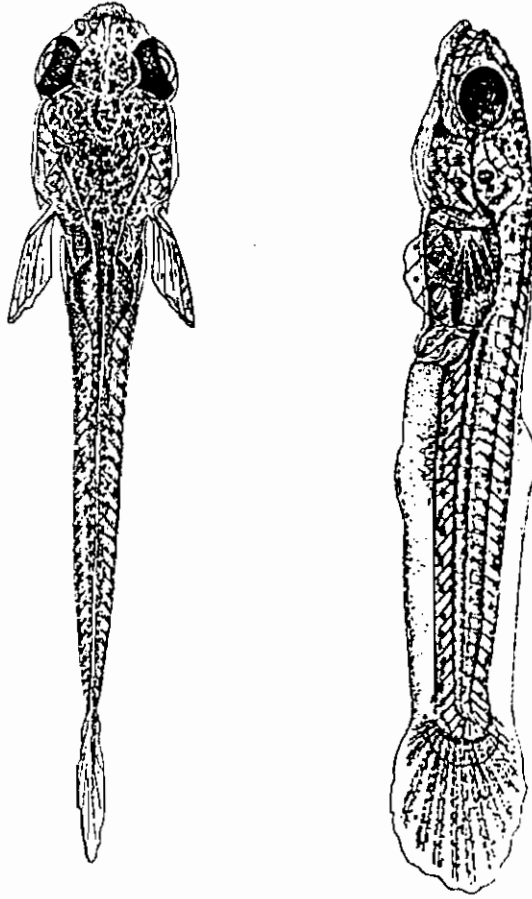


The closure of the blastopore is complete. The main divisions of the brain, the forebrain, midbrain, and hindbrain, are distinguishable with a well defined keel, ventral to the brain, indenting the yolk sac. There is an increased but variable condensation of cells lateral to the embryonic axis in the location of the future anterior somites. Kupffer's vesicle appears as the embryos advance towards the next stage. The ectoderm lifts to form a large vesicle anterior to the head, possibly the forerunner of the pericardial cavity.

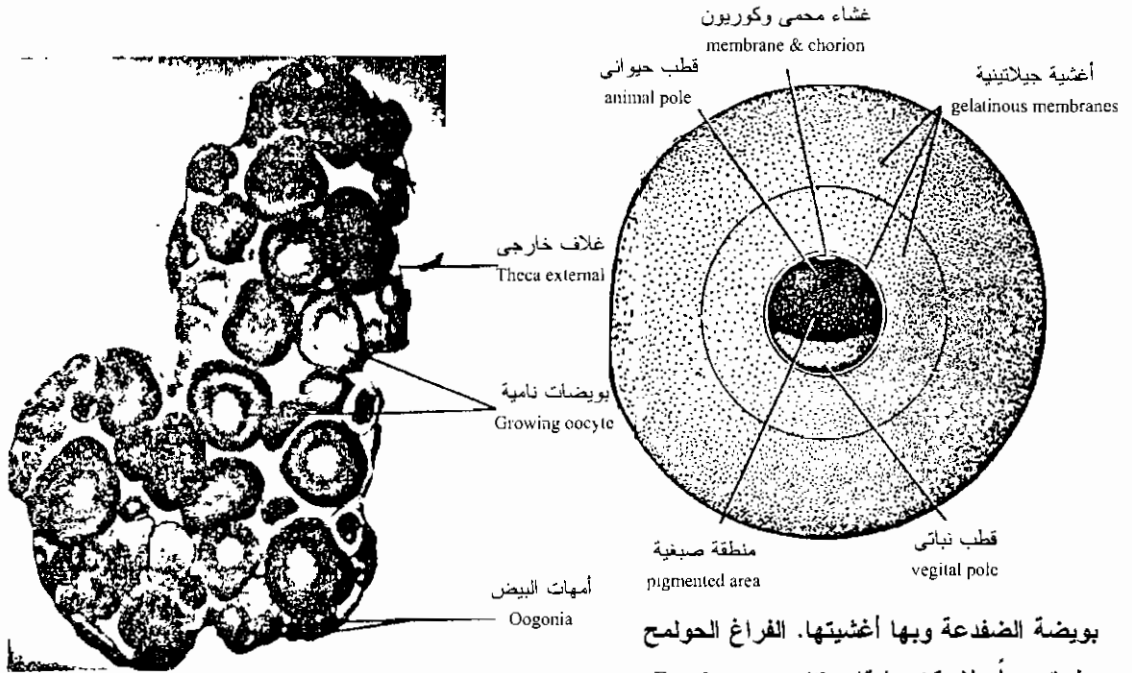


رسوم تخطيطية توضح مراحل مختلفة من التكوين الجنيني المتأخر في سمكة الشبوط
Schematic diagrams illustrating various stages of the embryonic development of silver carp.

مرحلة وسطية بين الجنين واليرقة في سمكة عظمية

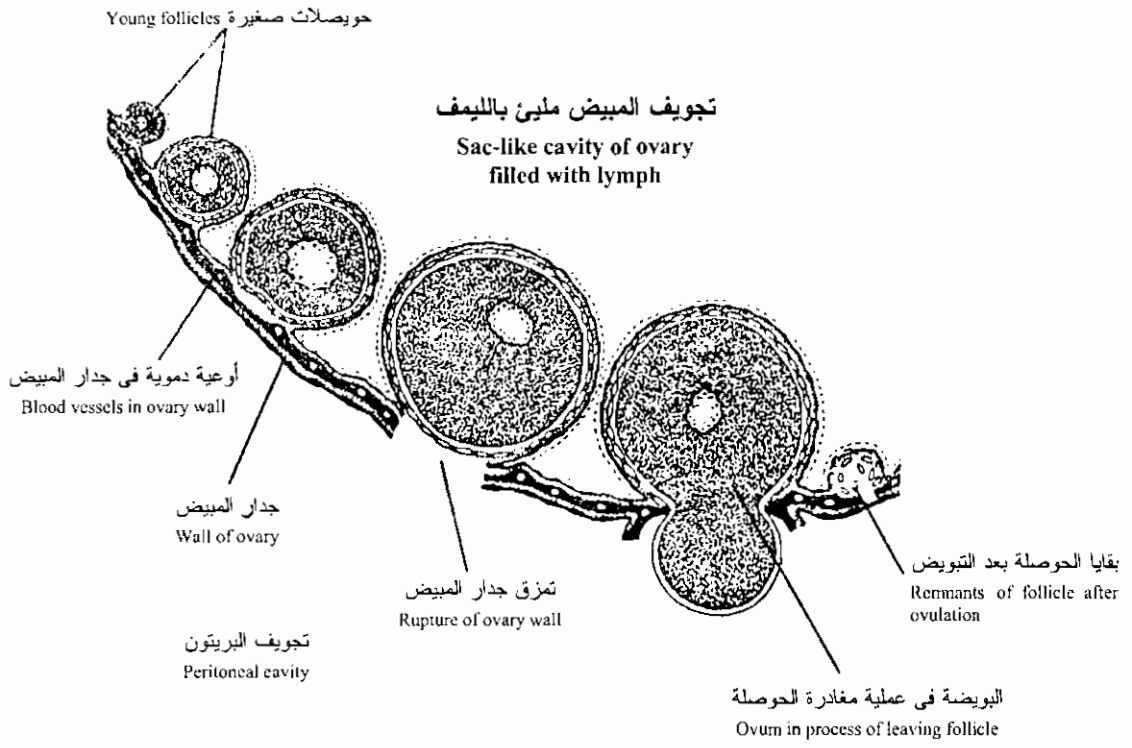


This is a transition stage from the embryonic to the larval state with the complete absorption of the yolk. The operculum and pectoral fins are almost continuously rhythmically active. The swim bladder has increased in size and the embryos commonly swim at the surface of the water, but will swim to the bottom of the aquarium if disturbed, the pectoral fins being in constant motion. (The designation of the stage where the yolk is absorbed as the final step of the series is purely arbitrary; it must not be thought that at this stage the fry are miniature adults. Many more changes must ensue before adult proportions are attained: skin and scales must be differentiated, much of the skull and axial skeleton remains to be elaborated, the definitive pigment pattern is yet to be laid down, and the anal fins are still to be formed, to mention only a few of these changes. In addition the body as a whole is to undergo considerable change of proportion, and its parts varying degrees of heterogonic growth. Since all these processes are gradual and a continuation of the earlier processes described, there can be chosen no exact moment when the embryo metamorphoses into an adult. The stage of yolk absorption is a convenient stopping place because the primitive organ systems are all represented at this stage.)

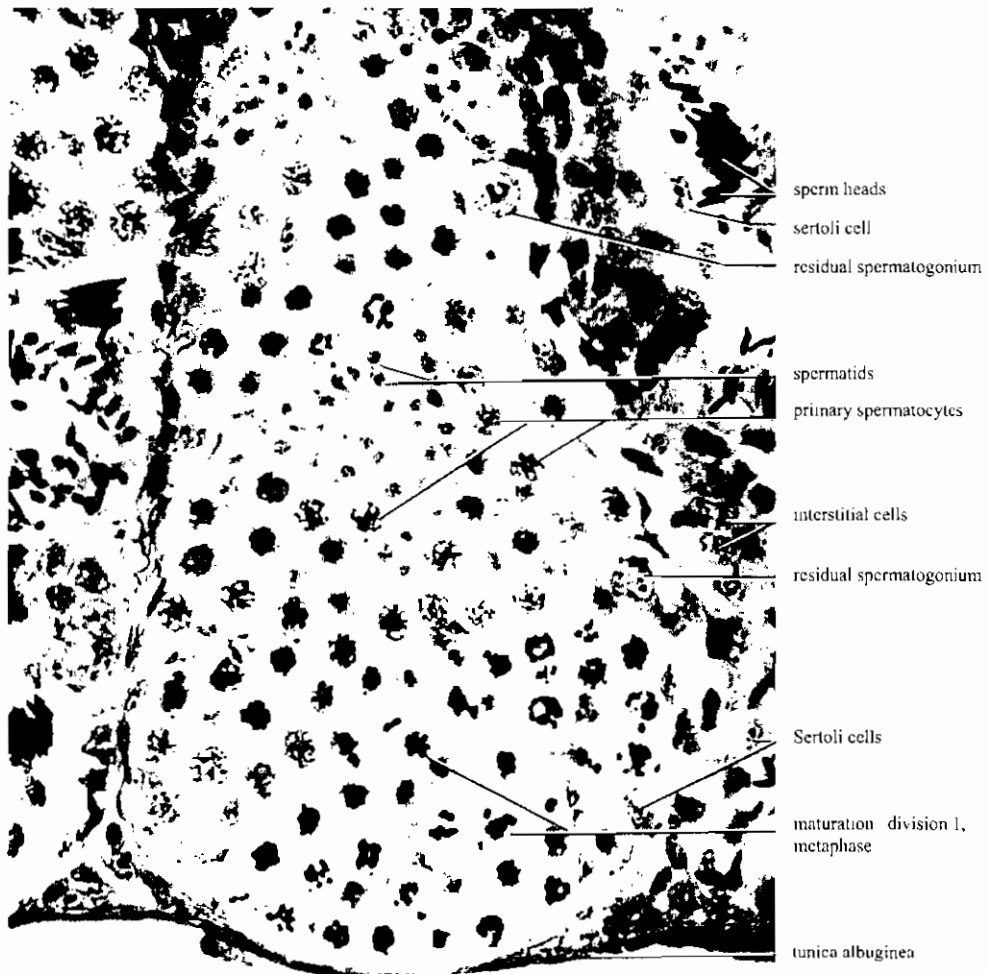


بويضة الضفدعة وبها أغشيتها. الفراغ الحولم ضيق جداً ولا يمكن رؤيته. Frog's ovum with membranes.

قطاع يظهر مبيض ضفدعه نامي. A section through a growing frog ovary. (x 40.)



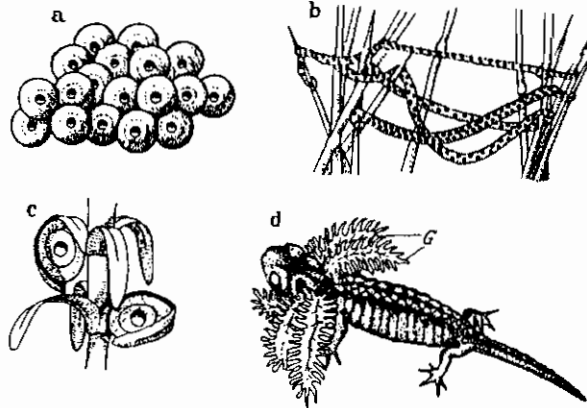
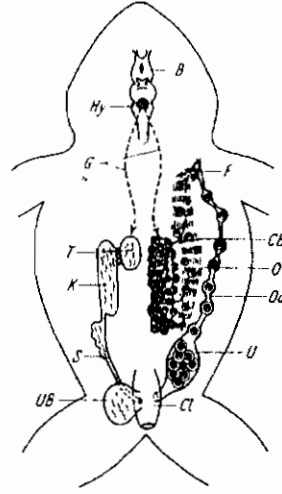
عملية التبويض في مبيض كيسي Saccular type of ovary showing ovulation.



قطاع في خصية ضفدعة يوضح تركيب الأنبيبة المنوية
Frog testis, section (mag. 725 x)

رسم يوضح تأثير الغدة النخامية على المناسل في الضفدعة

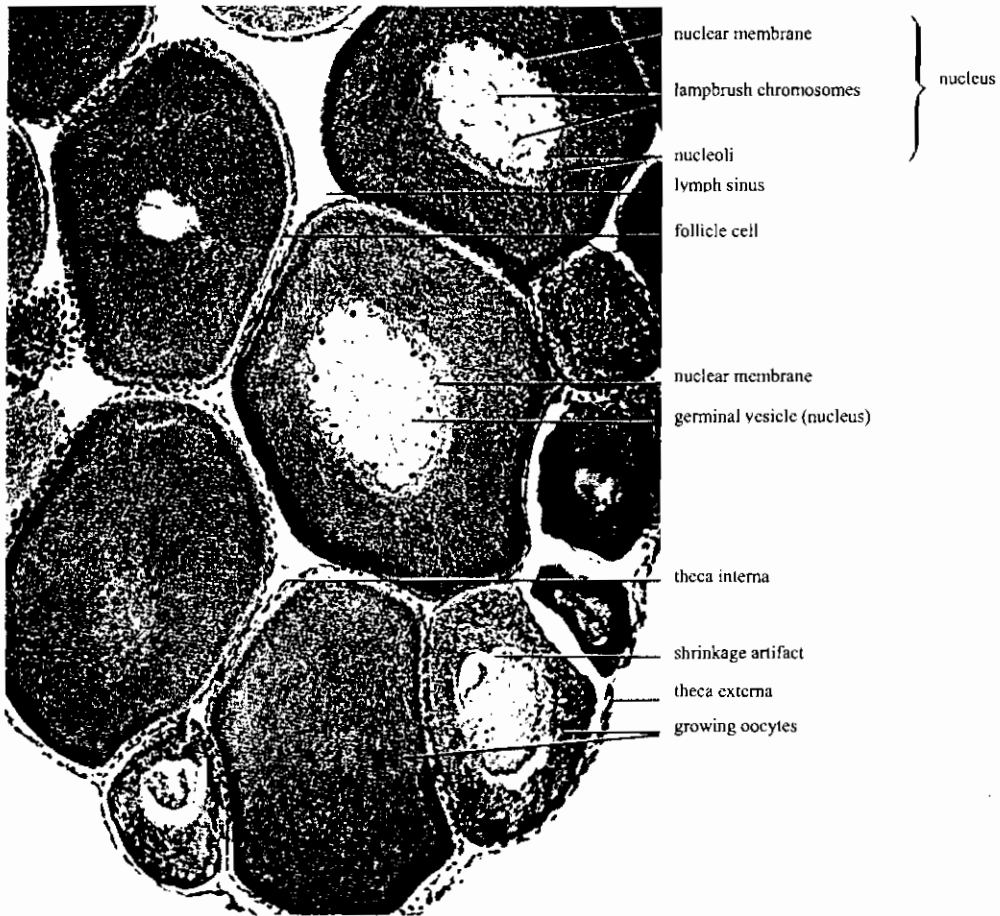
Diagram of hypophysis action and migration of the gametes in the frog. The male situation is shown on the left, that for the female on the right. B brain; Hy hypophysis; G gonadotropic hormone; T testis; K kidney; S sperm duct; UB urinary bladder; F funnel; CB ciliary bands; O ovary; Od oviduct; U uterus; Cl cloaca



a Part of the egg mass of the common European frog. b Strings of toad eggs stretched between plant stems. c Two newt eggs under leaves of a water plant. d Larva removed from the oviduct of an alpine salamander, showing the extreme development of the gills (G)

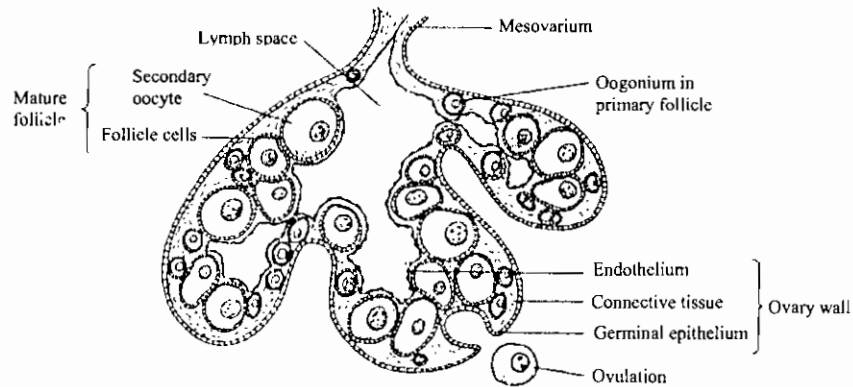
- أ- جزء من كتلة بيض الضفدعة الأوروبية الشائعة.
 ب- شرائط بيض ضفدع ممتدة بين سوق النباتات.
 ج- بيض نيوت تحت أوراق النباتات المائية.
 د- يرقة سلمندر البى مستخرجة من قناة البيض.
 هـ- الخياشيم الخارجية في مرحلة متأخرة من نموها.

قطاعات في مبيض الضفدعة توضح البويضات النامية

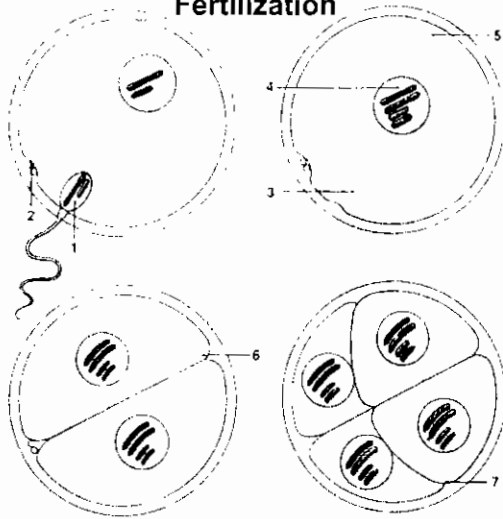


Frog ovary, section showing growing oocytes (mag. 135x)

A section through an amphibian ovary



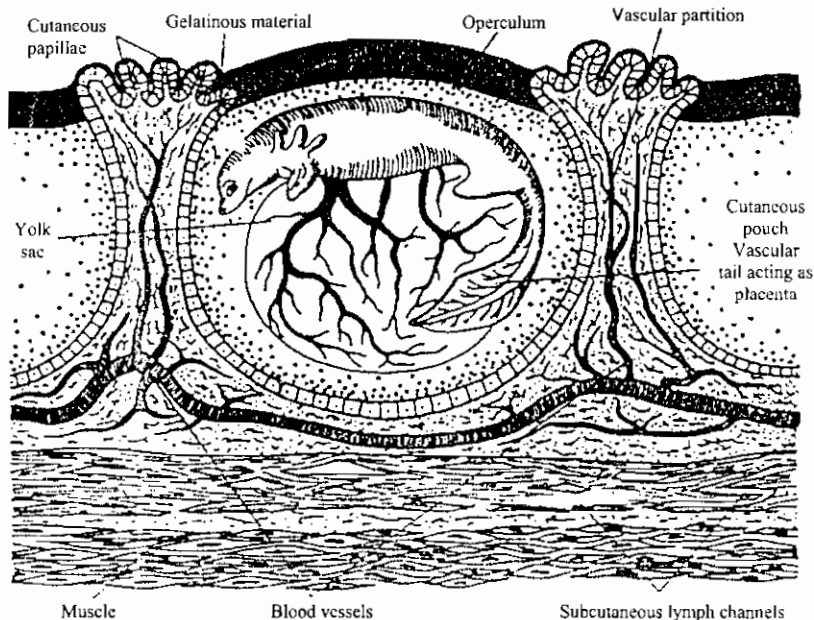
الإخصاب
Fertilization



Fertilization of a frog's egg occurs in shallow water. When a sperm (1) from the male penetrates the egg, the second polar body (2) forms. The sperm leaves a trail (3) caused by the displacement of granules in a layer of pigment. The nuclei of the sperm and egg fuse, forming a zygote (4). Penetration by the sperm induces a shift in the pigment layer, resulting in the formation of a gray crescent (5) opposite the point of entry, which determines the first line of cleavage (6). Successive divisions (7) form a ball of cells.

Anura: Ovoviviparity. In the Surinam Toad (*Pipa dorsigera*) the eggs are lodged in lidded pits in the dorsal surface of the female. (After Mivart.)

ضفدعة سورينام البيوضة الولودة حيث تحتفظ الأنثى ببيضها، في حفر ظهرية ذات غطاء، حتى يفقس

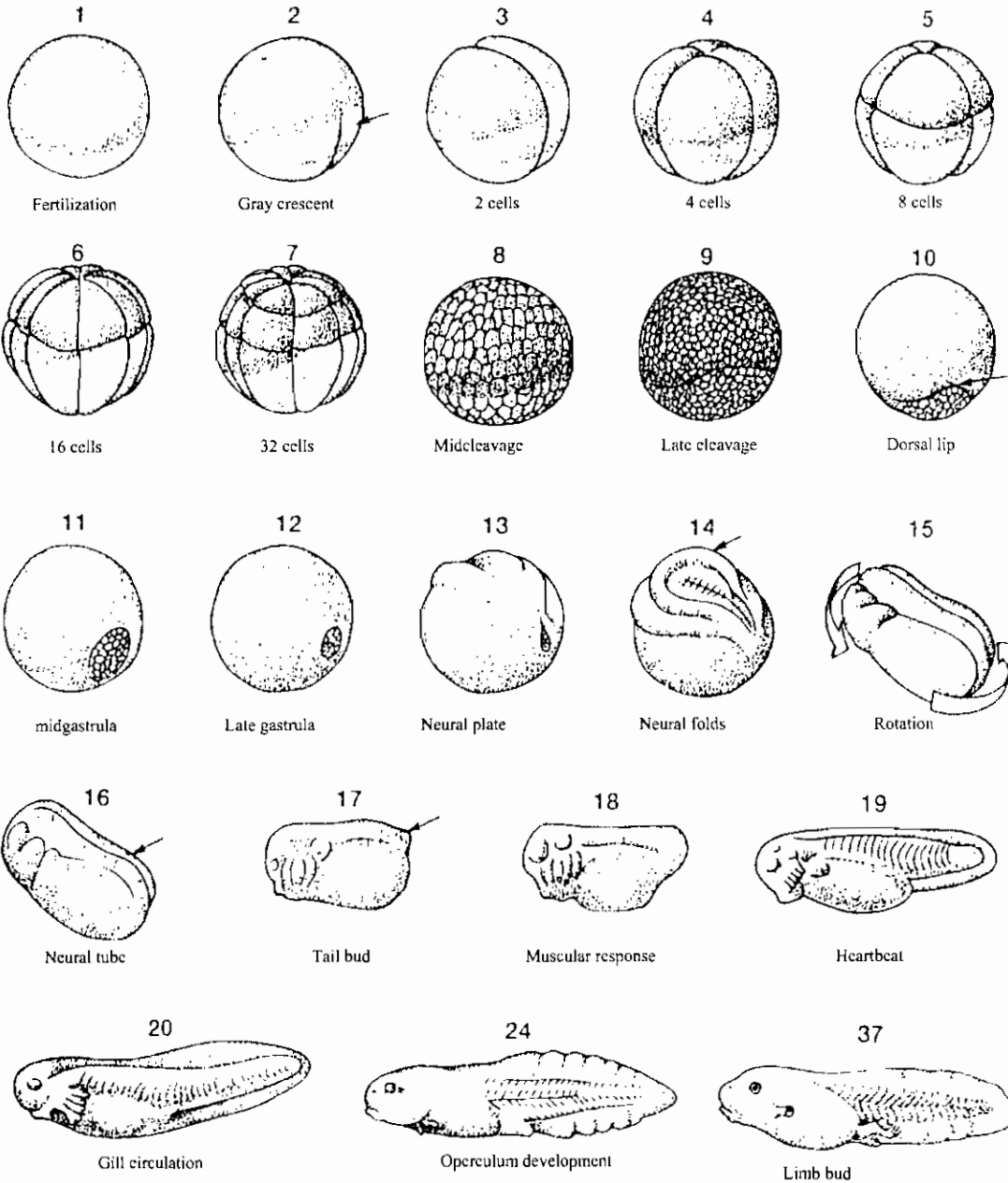


Anura: Pseudo-placentation. Gaseous exchanges occur between the maternal tissues and the expanded, leaf-like tail of the pouch larva of *Pipa dorsigera*. (After Amoroso).

المشيمة الزائفة في البرمائى اللازولى المسمى بيبا حيث يحدث تبادل فى الغازات بين الأوعية الدموية للأم وتلك الموجودة

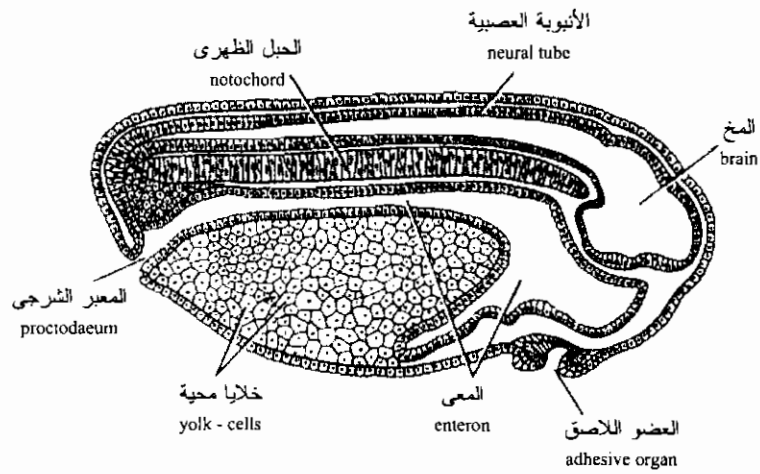
فى ذيل الجنين الورقى الشكل

مناظر خارجية لتكوين البرمائيات الالاذيلية

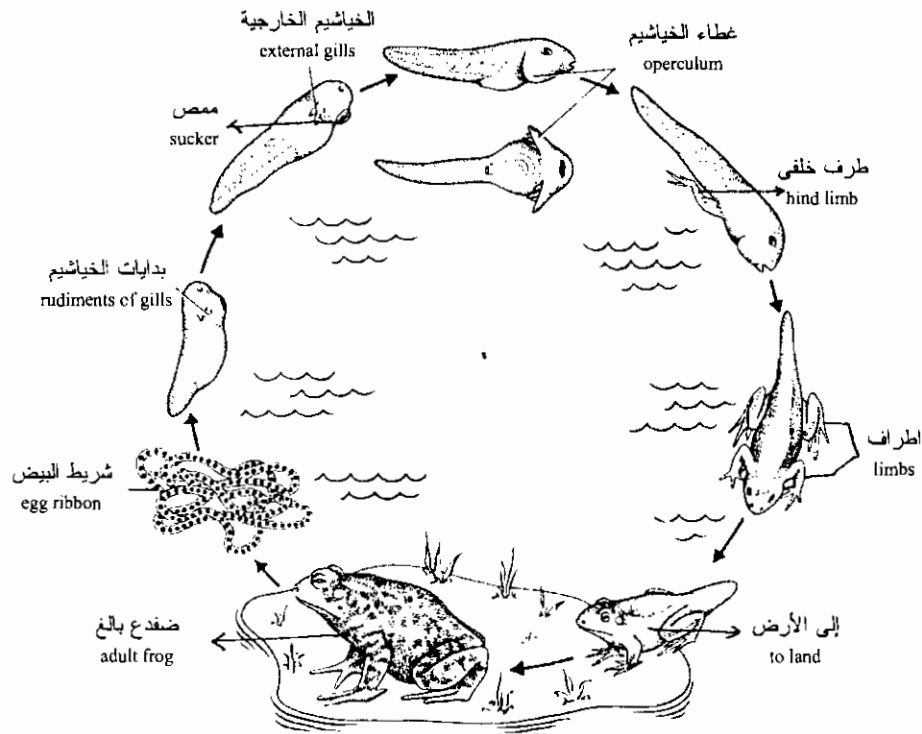


External view of anuran development. Beginning with fertilization (1), morula (6-8), blastula (9 and 10), gastrula (11 and 12), and neurula (13-16) stages follow successively. In later development, the tail bud forms (17), muscular twitches begin (18), heartbeat commences (19), functional external gills develop (20), and blood circulation

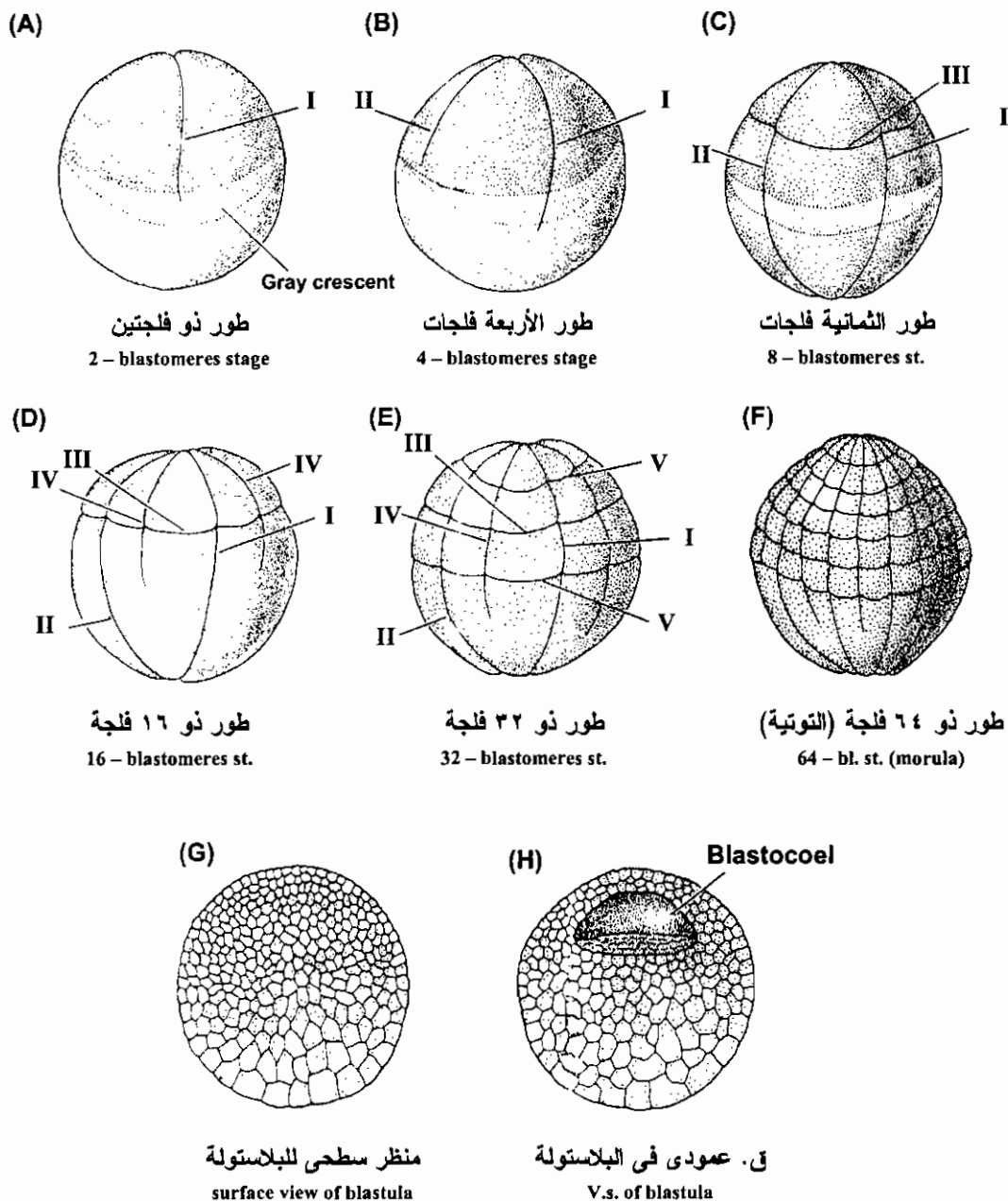
occurs through the caudal fin. Subsequent events include the formation of an operculum (24), a flap of head skin that grows over and covers the gills. The hindlimbs develop first and then the forelimbs. Eventually the embryo undergoes metamorphosis into a juvenile frog. Stages between 20-24 are not illustrated.



قطاع سهمي في أبي ذنبية طوله مليمتران (طور الفقس)
Sagittal section of a tadpole 2mm in length (hatching stage)



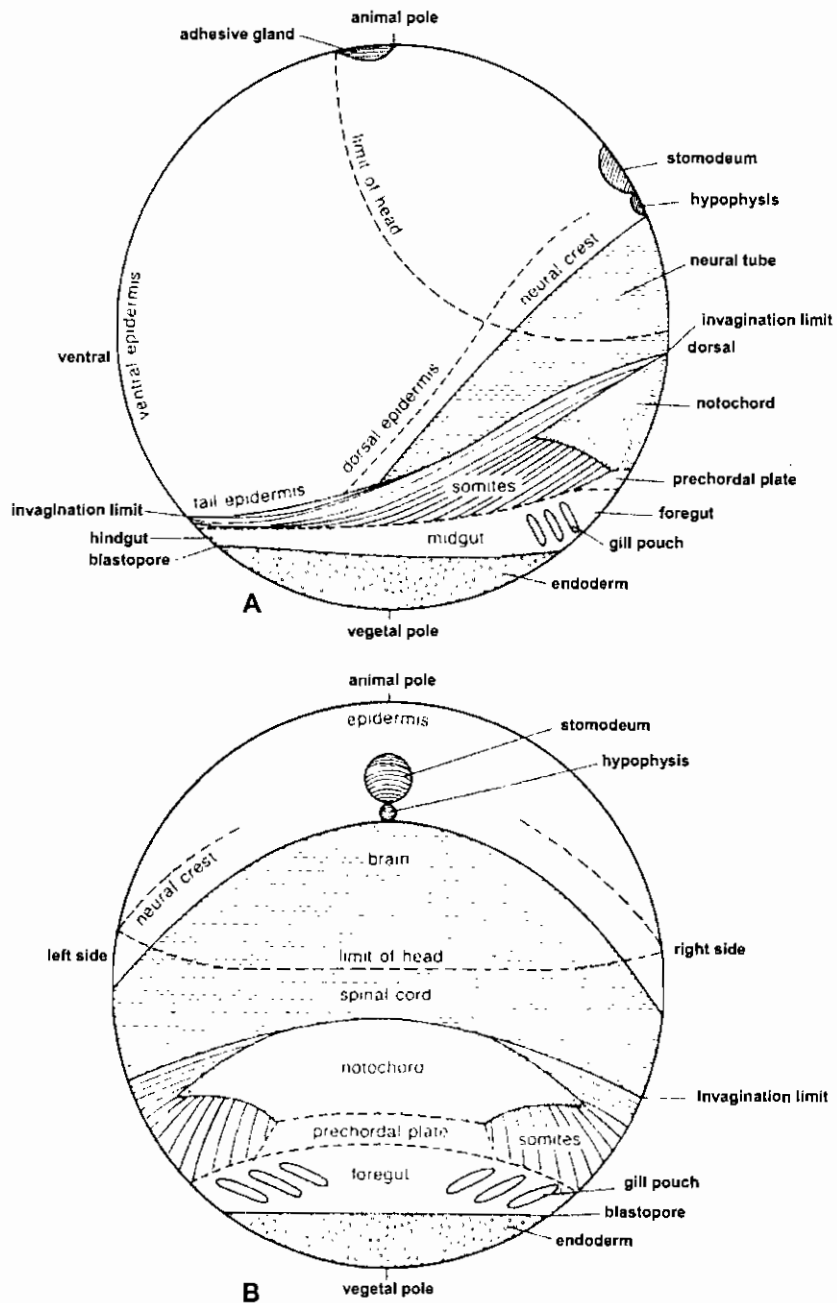
أطوار الضفدعة من البيضة حتى اكتمال التحول
LIFE CYCLE OF THE TOAD FROM
THE EGG TILL THE END OF METAMORPHOSIS



التفنج فى الصفدعة

Cleavage of a frog egg. Cleavage furrows are designated by Roman numerals in order of appearance. The vegetal yolk impedes the cleavage such that the second division begins in the animal region of the egg before the first division has divided the vegetal cytoplasm. The third division (C) is displaced toward the animal pole. The vegetal hemisphere ultimately contains longer and fewer blastomeres than the animal half. (After Carlson, 1981.)

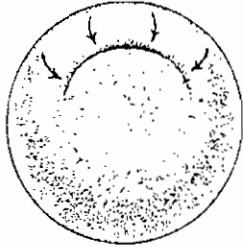
منظر جانبي وعلوي في جاسترولة صغيرة لبرمائى لا ذيل يوضحان خرائط المصير



Maps of the presumptive regions of the very young gastrula of the anuran, *Discoglossus*, (a) side view. (b) dorsal view. [Redrawn from Jean Pasteels; New observations concerning maps of presumptive areas of the young amphibian gastrula (*Amblystoma* and *Discoglossus*). *Journal of Experimental Zoology* 89:255-251 (1943). Used with permission of the Wistar Institute Press.]


التبطين في البرمائيات
Gastrulation in Amphibia

مناظر سطحية خلفية متتالية



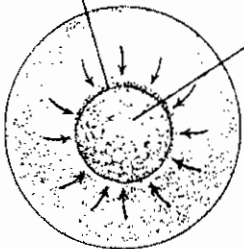
(A)

جاسترولة متقدمة



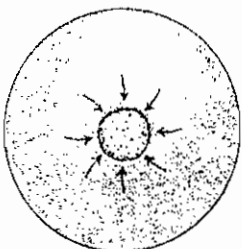
(B)

Lip of blastopore
Yolk plug



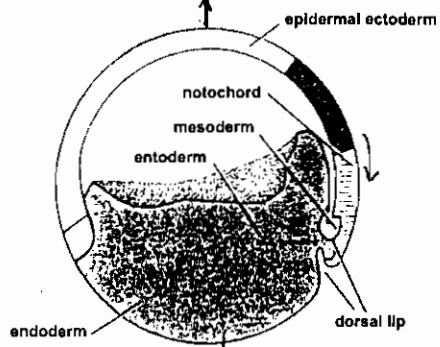
(C)

جاسترولة متأخرة

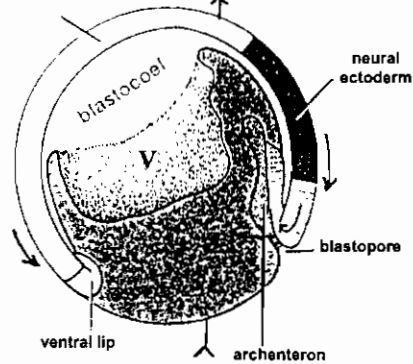


(D)

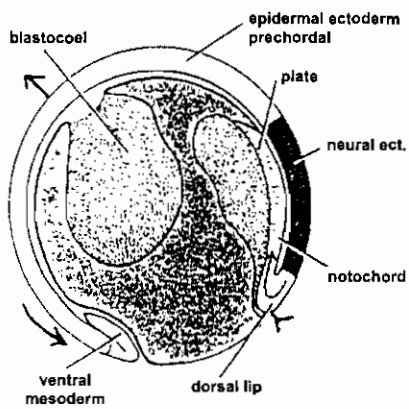
قَطَاعَات عمودية في نفس المراحل



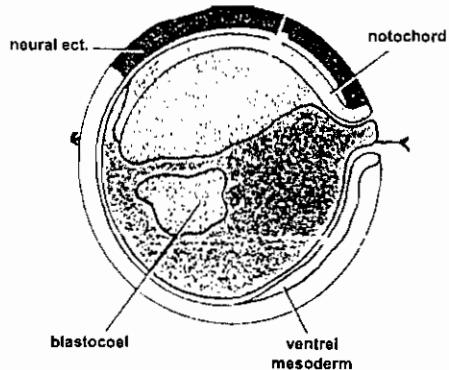
(A')



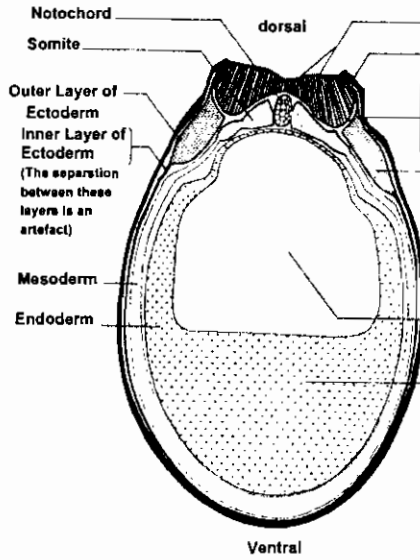
(B')



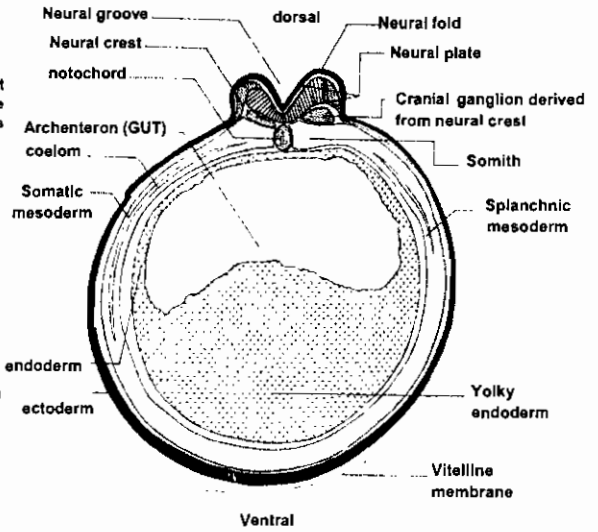
(C')



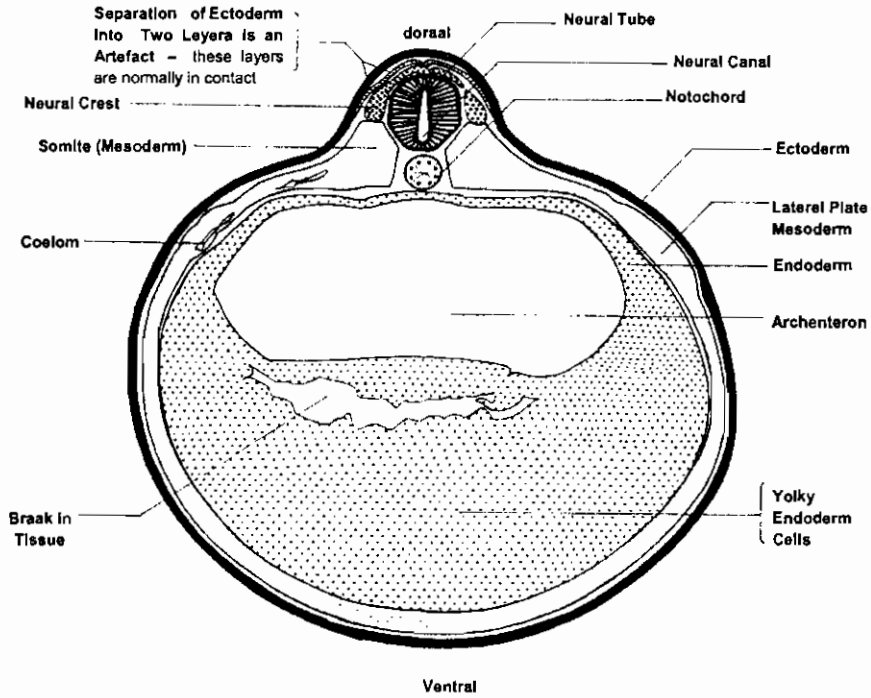
(D')



ق.ع. في مرحلة الصفحة العصبية للضفدعة
T.s. of frog, neural plate stage

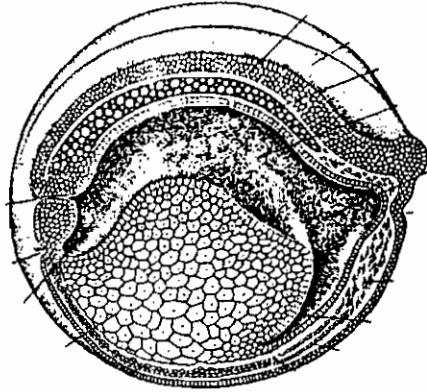


ق.ع. في مرحلة الثنية العصبية للضفدعة
T.s. of neural fold stage



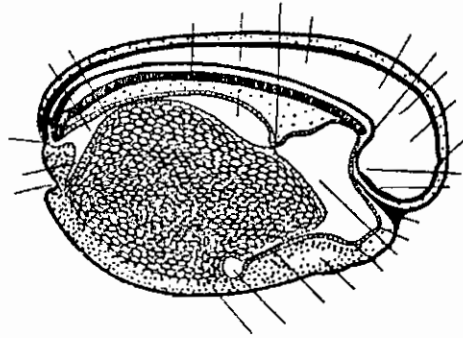
ق.ع. في مرحلة الأنبوبة العصبية للضفدعة
T.s. of neural stage of the frog

قطاعات طولية في يرقة الضفدعة توضح تكوين الأعضاء الأساسية

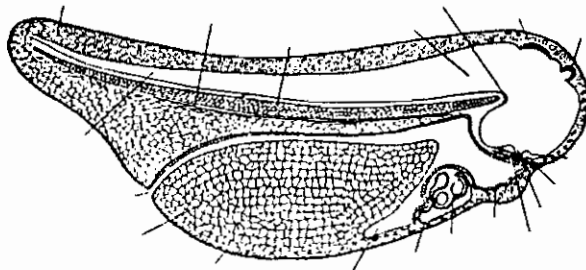


قطاع محوري في مرحلة الأنبوبة العصبية المفتوحة

Sagittal section of the open neural fold stage. (Redrawn and modified after Huettner.)

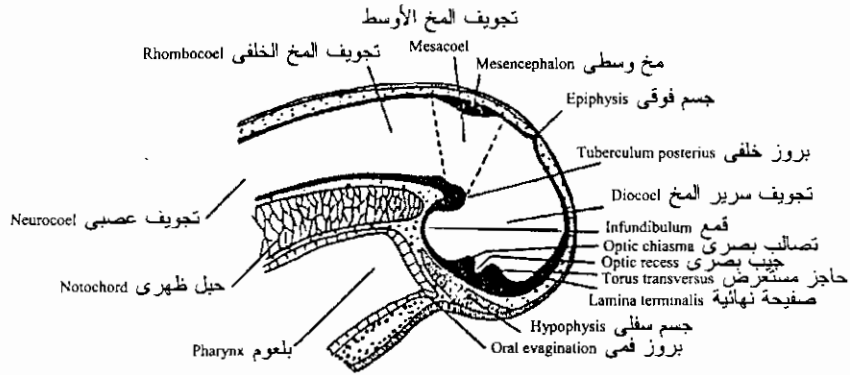


قطاع محوري في يرقة ضفدعة طولها ٣ مم
The 3 mm. Frog tadpole: sagittal section.



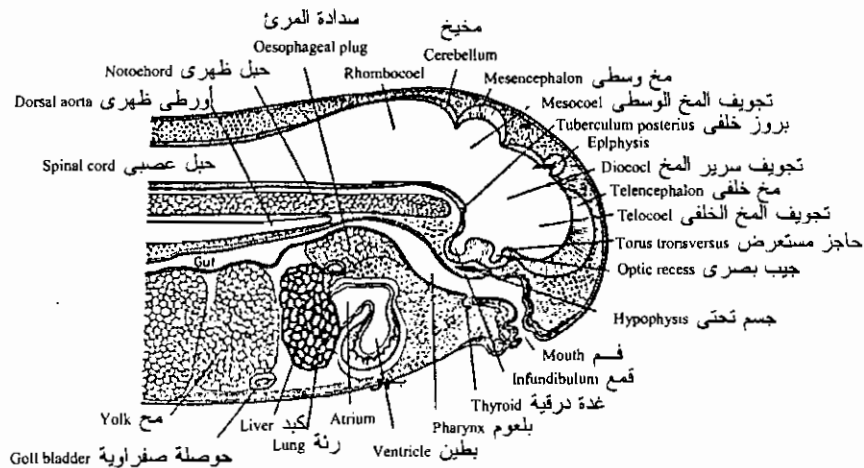
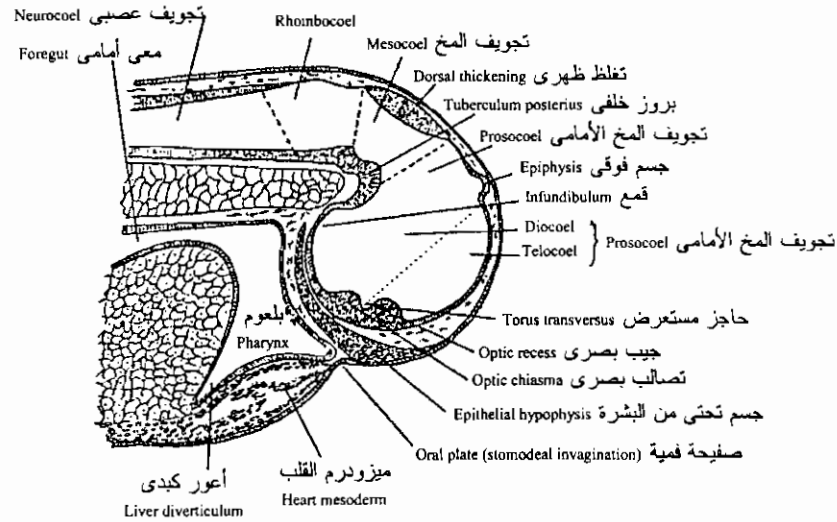
قطاع محوري في يرقة ضفدعة طولها ٥ مم
Reconstruction of the 5 mm. Tadpole in sagittal section

قطاعات محورية في النصف الأمامي من يرقة الضفدعة توضح تكوين المخ

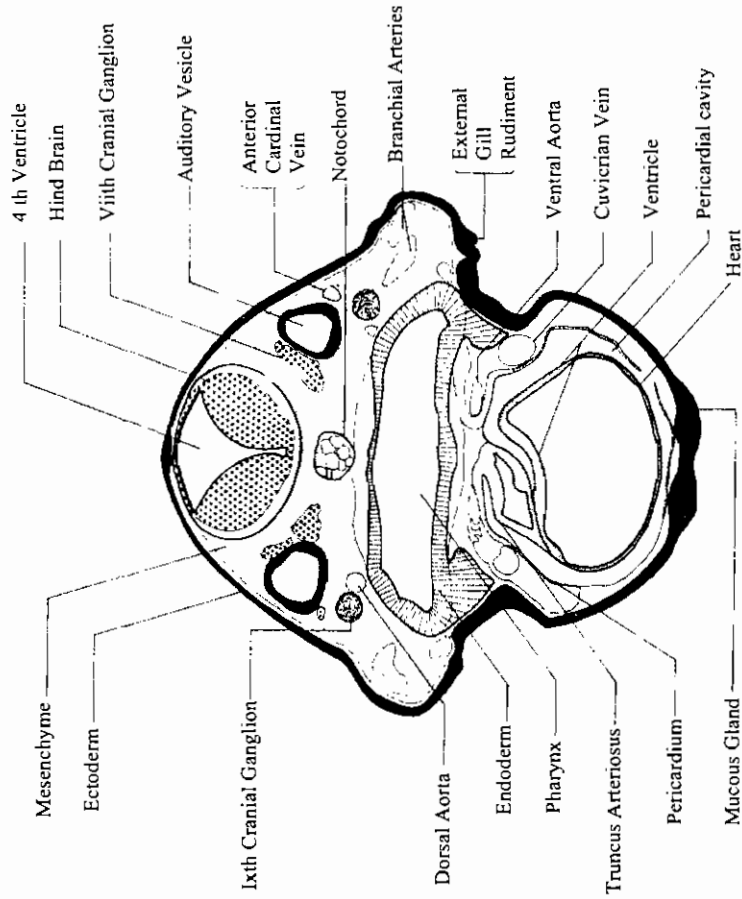


قطاع محوري للحويصلات المخية في يرقة ضفدعة

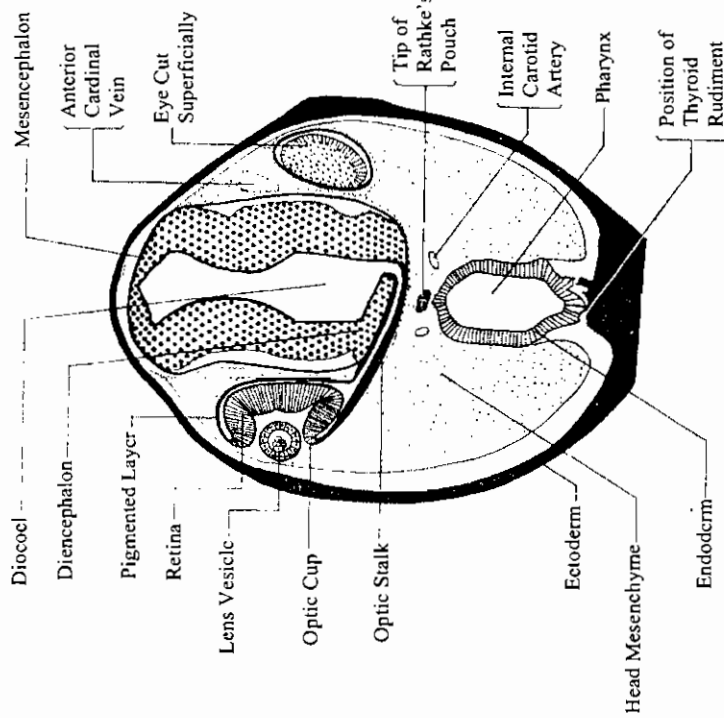
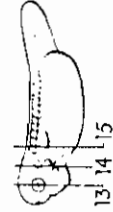
Early organogeny of the frog tadpole, showing the primary brain vesicles in sagittal section.



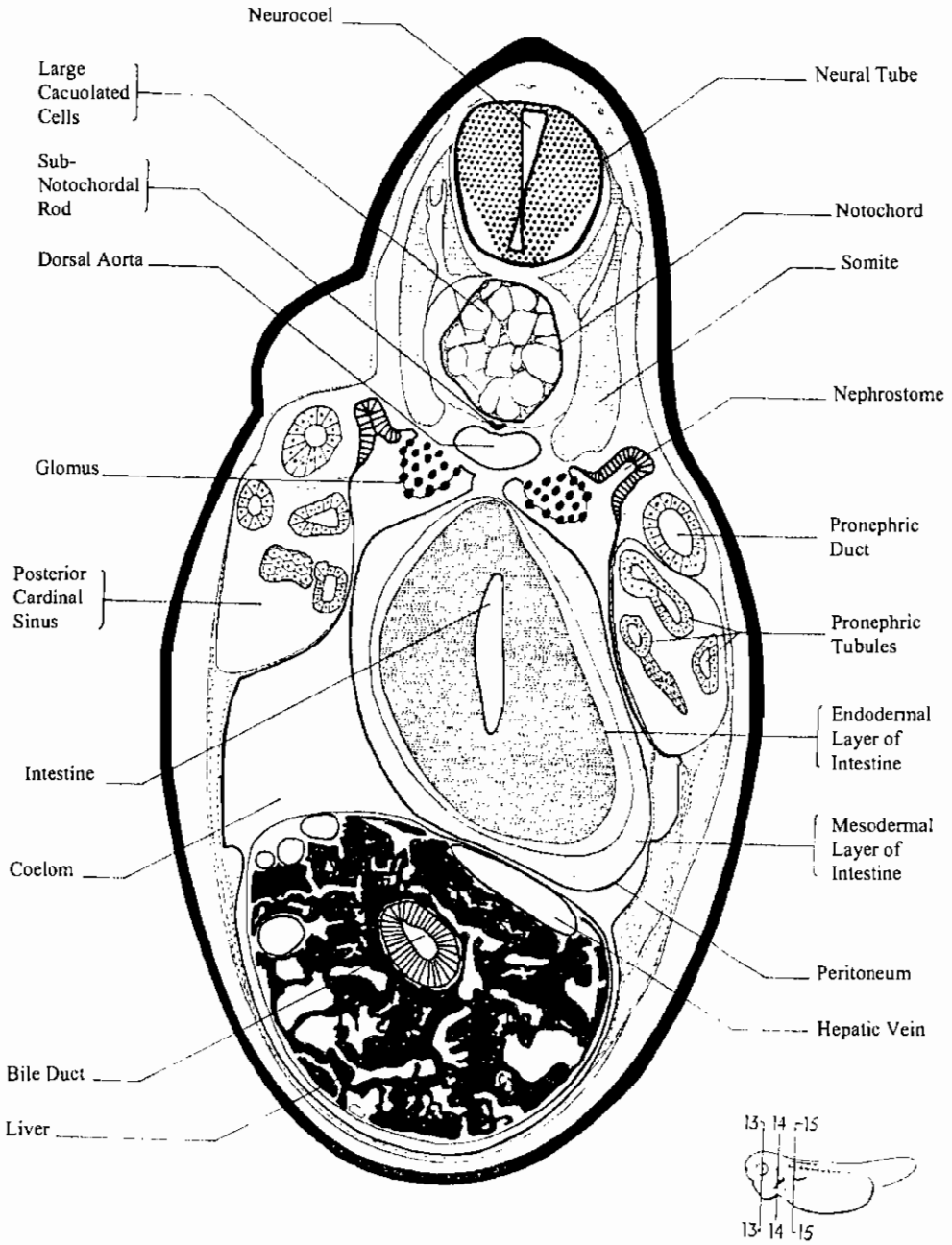
Development of the brain and anterior structures of the frog tadpole. (Center) Median sagittal section of the 7 mm. frog tadpole. (Bottom) Median sagittal section of the 11 mm. frog tadpole.



ق.ع. في المنطقة السمعية ليرقة ضفدعة حديثة الفقس
14- T. s. of auditory reg. of newly hatched frog larva. X 55

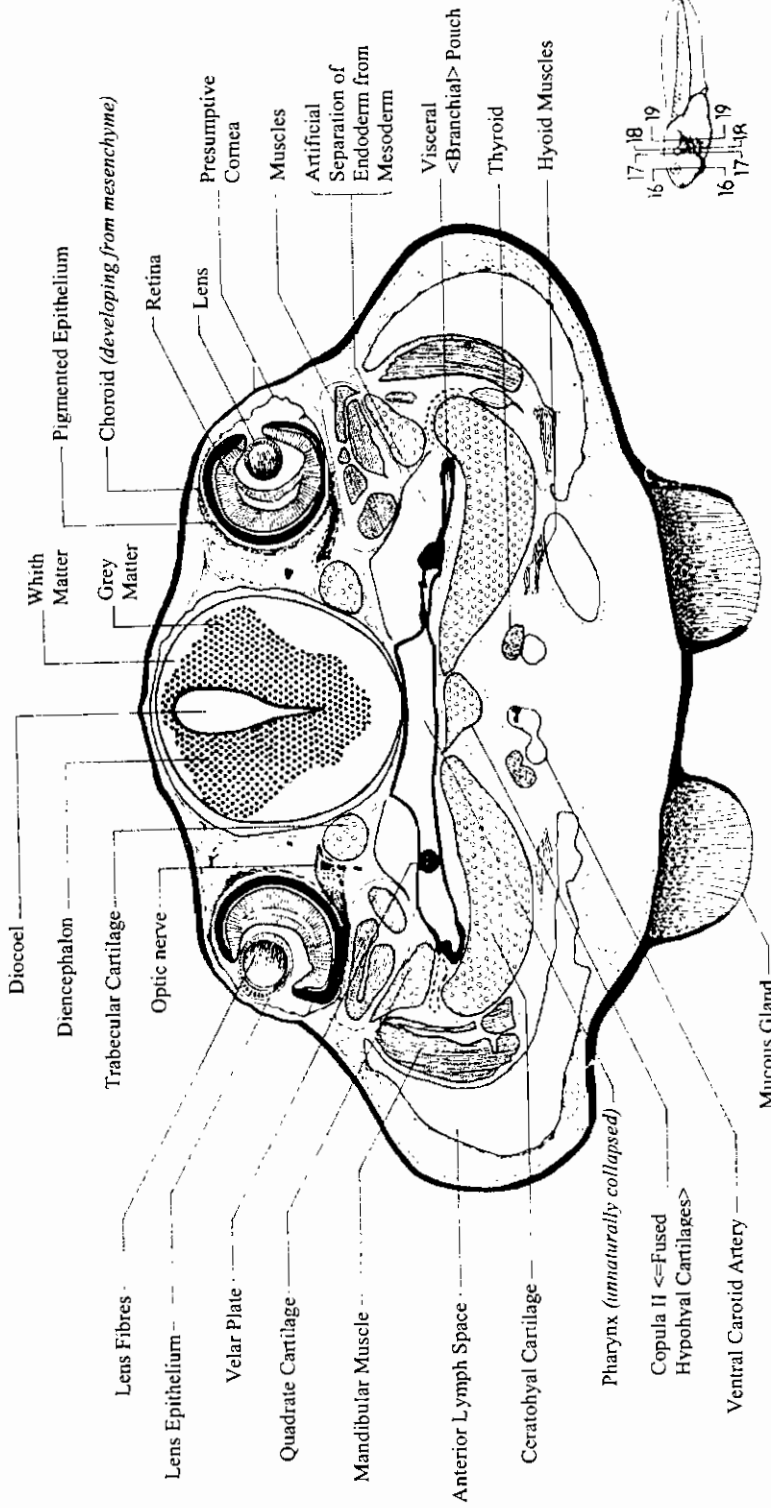


ق.ع. في منطقة العينان ليرقة ضفدعة حديثة الفقس
13- T. s. of optic reg. of newly hatched frog larva. X 80

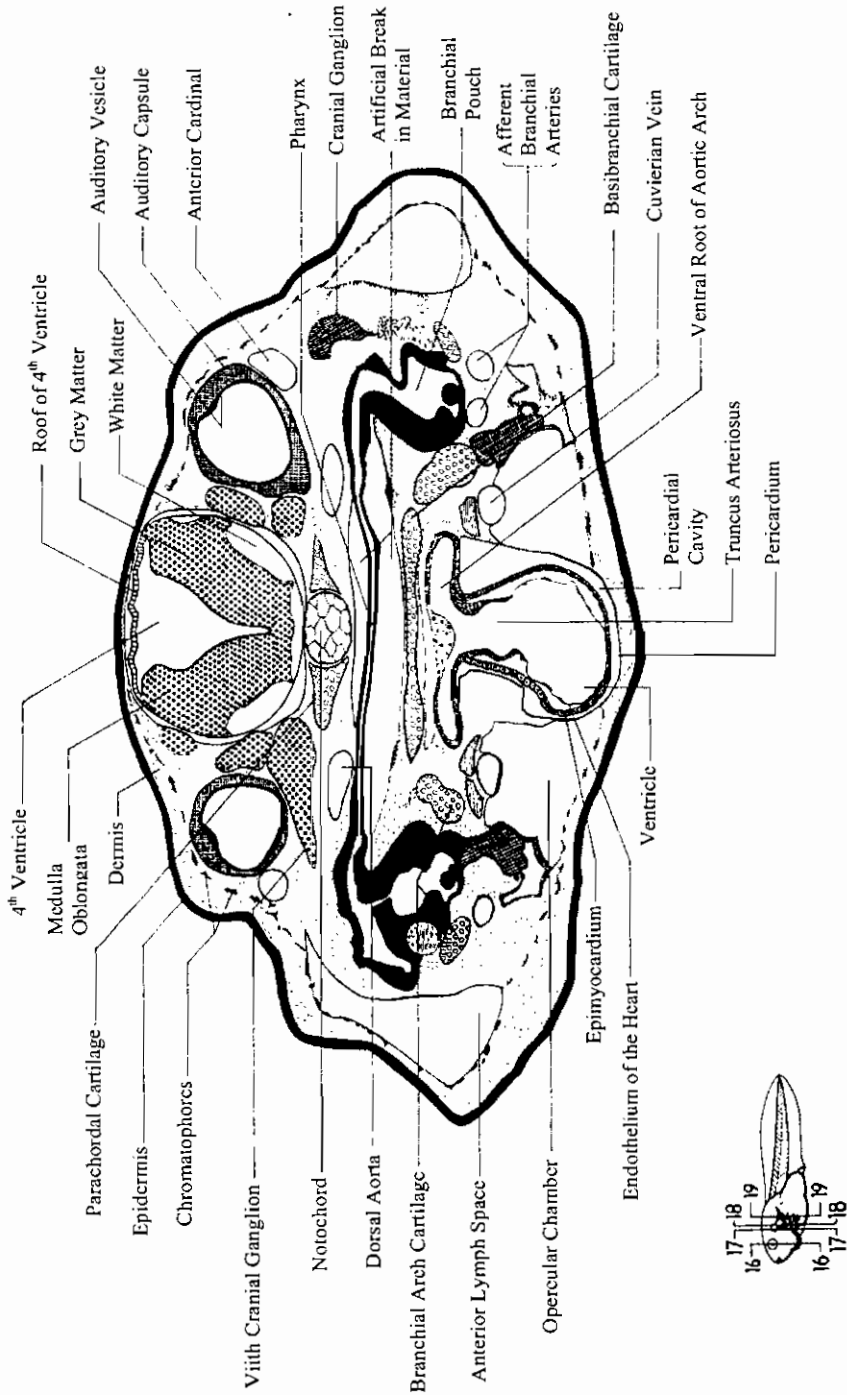


ق.ع. في منطقة الجزع ليرقة ضفدعة حديثة الفقس

15- T. s. of the trunk region of newly-hatched frog larva. X 130

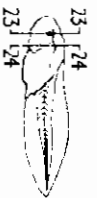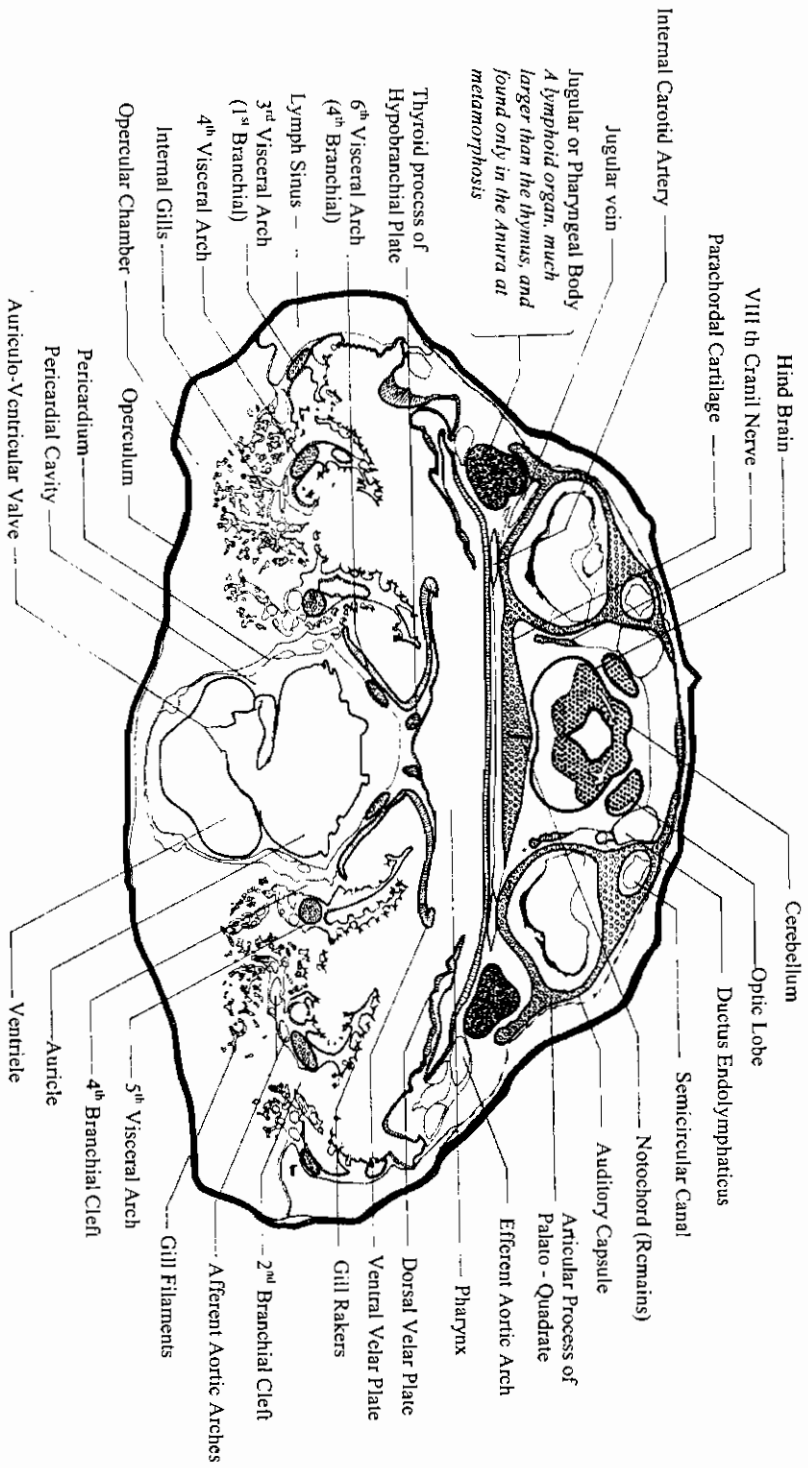


ق.ع. في منطقة العين ليرقة ضفدعة ذات خياشيم خارجية
T. s. of the optic region of external gill frog larva



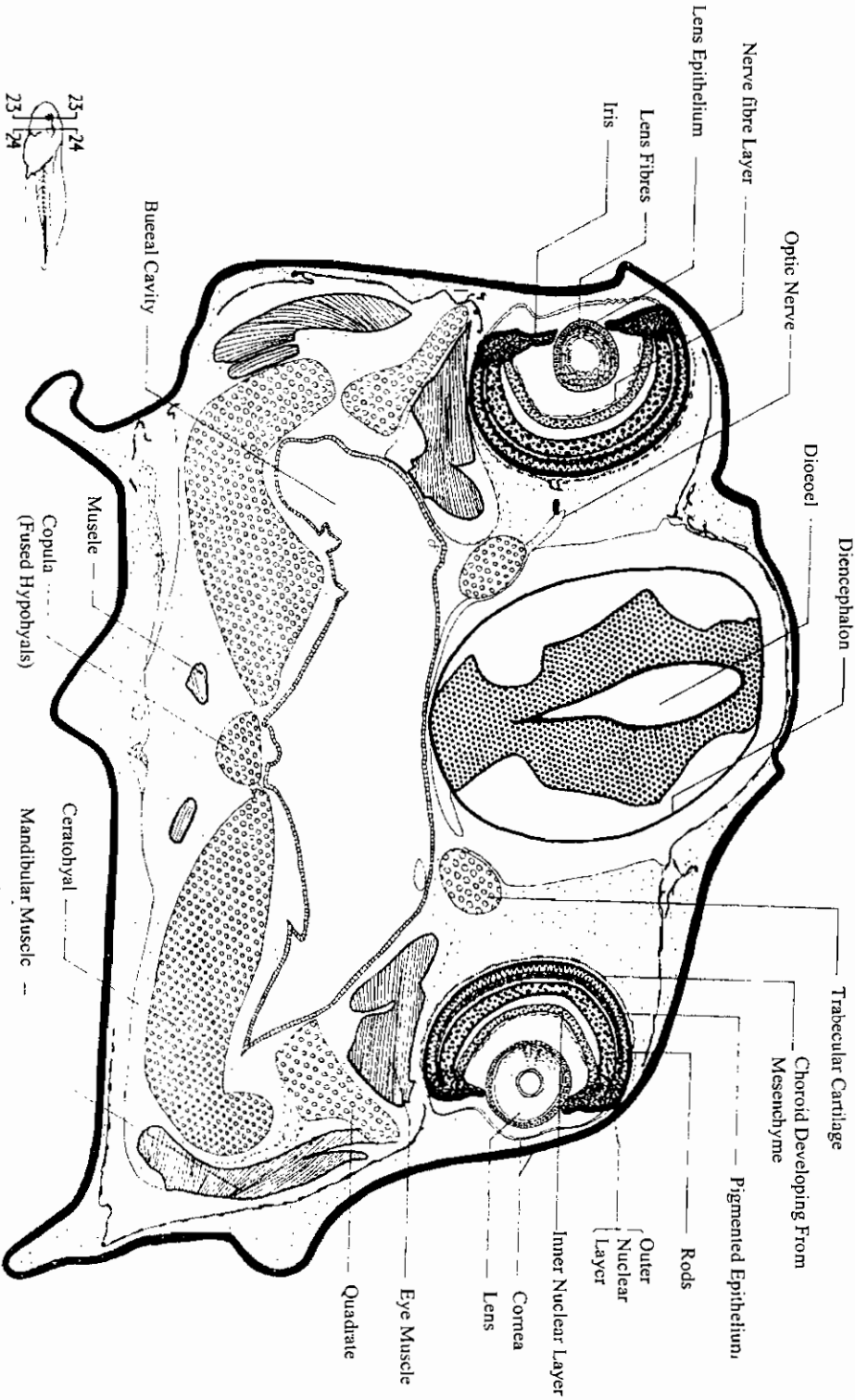
في.ع. في منطقة العين ليرقة ضفدعة ذات خياشيم خارجية
T. s. of the optic region of external gill frog larva

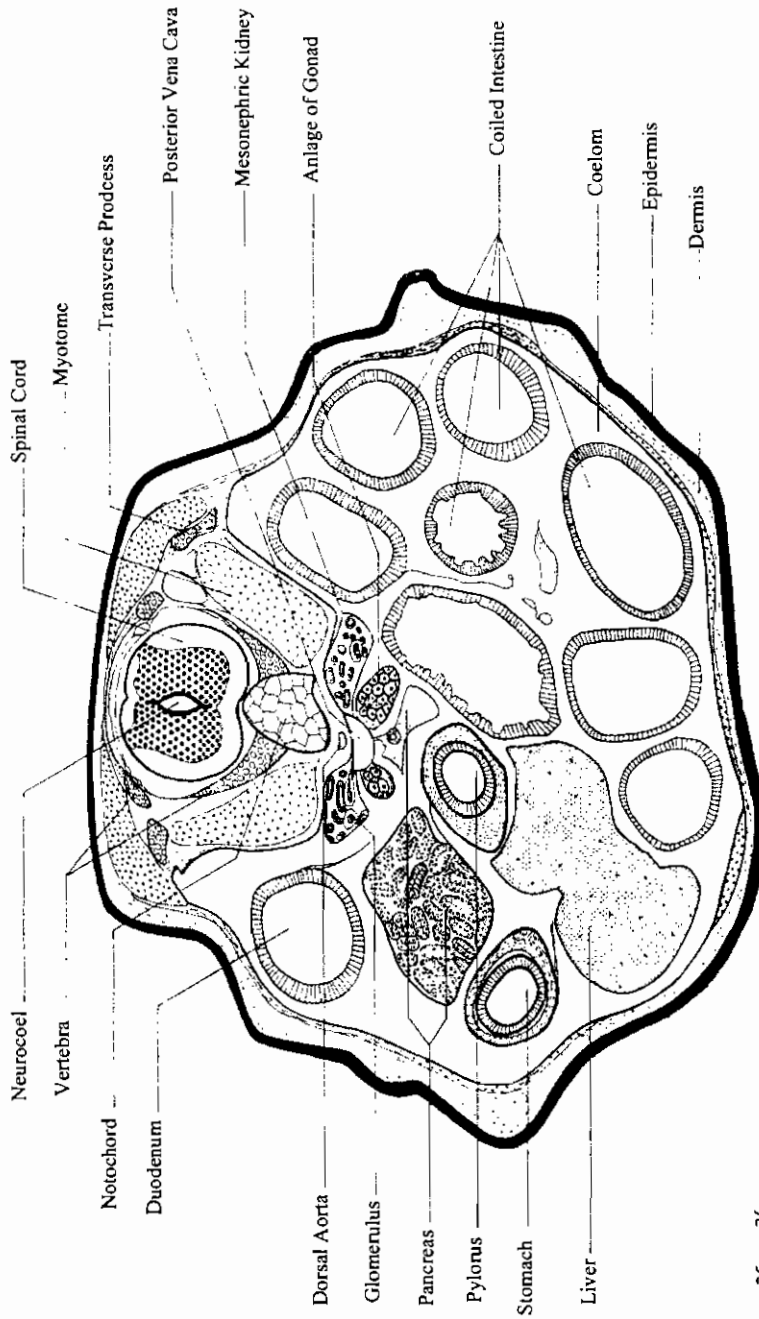
ق.ع. في منطقة الخياشيم لبرقة صفذعة ذات خياشيم داخلية
 T. s. of the gill region of enternal gill frog larva



ق.ع. في منطقة الخياشيم ليرقة ضفدعة ذات خياشيم داخلية

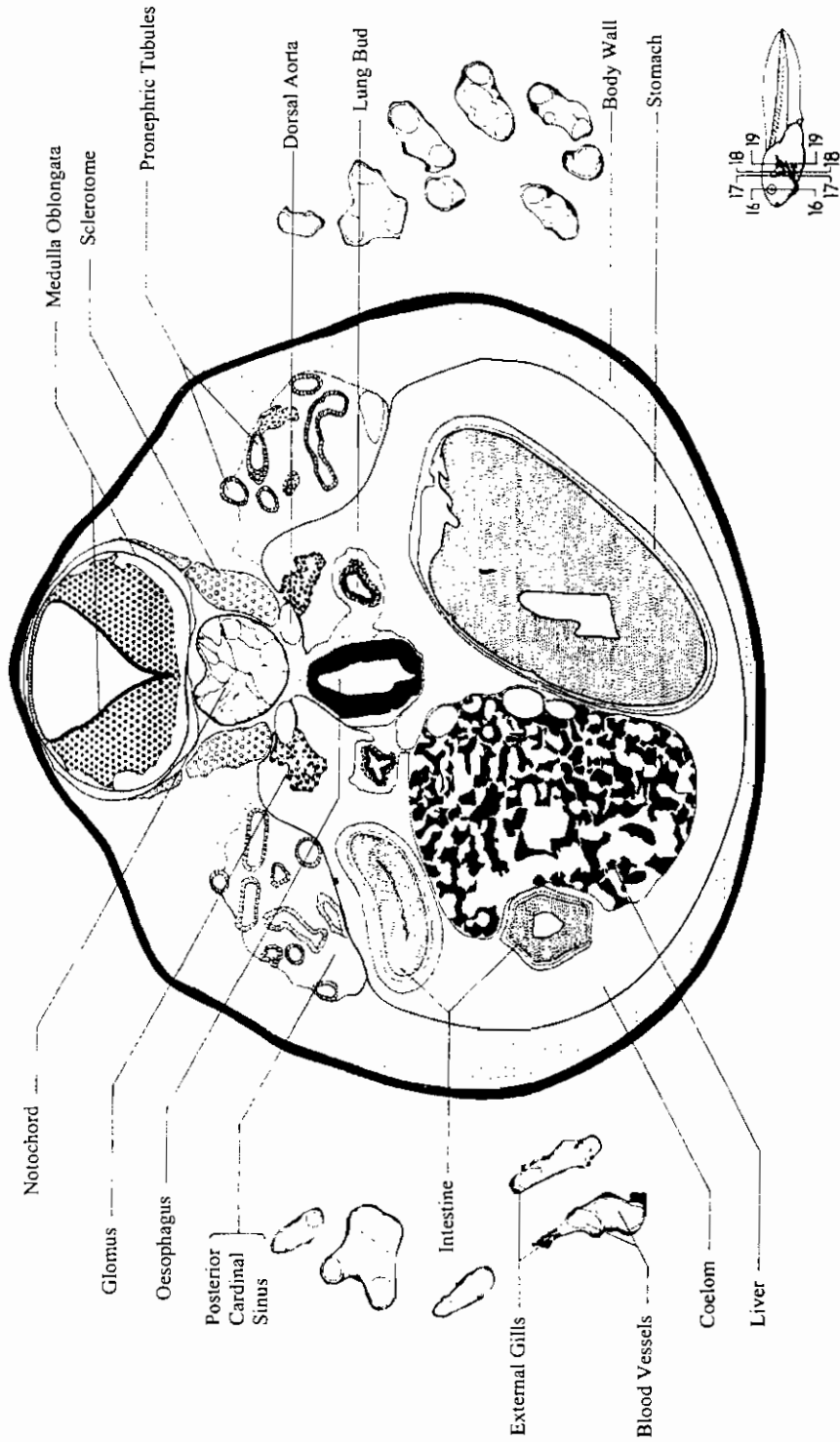
T. s. of the gill region of enternal gill frog larva





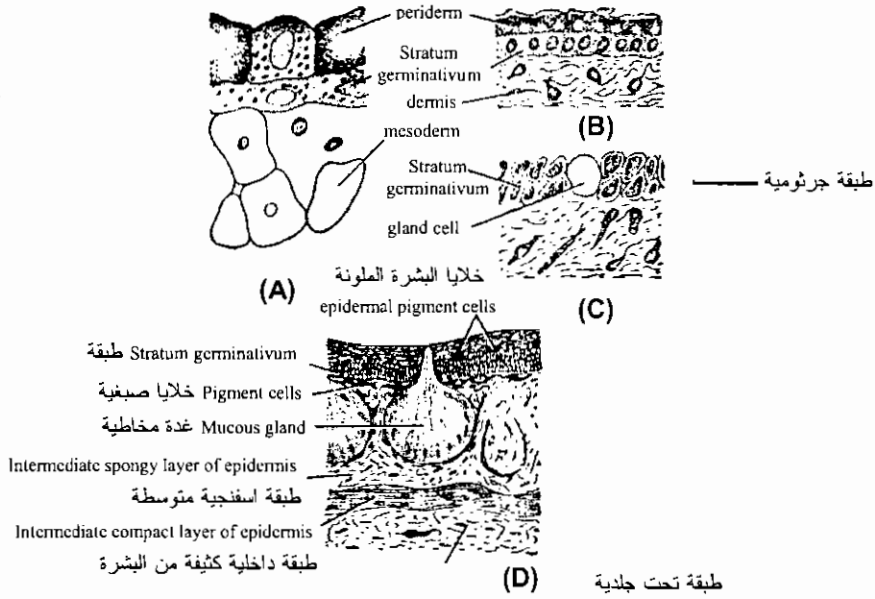
ق. ع. في منطقة الجرع ليرقة ضفدعة طولها ١٩ مم

T. s. of the trunk region of 19mm. tadpole

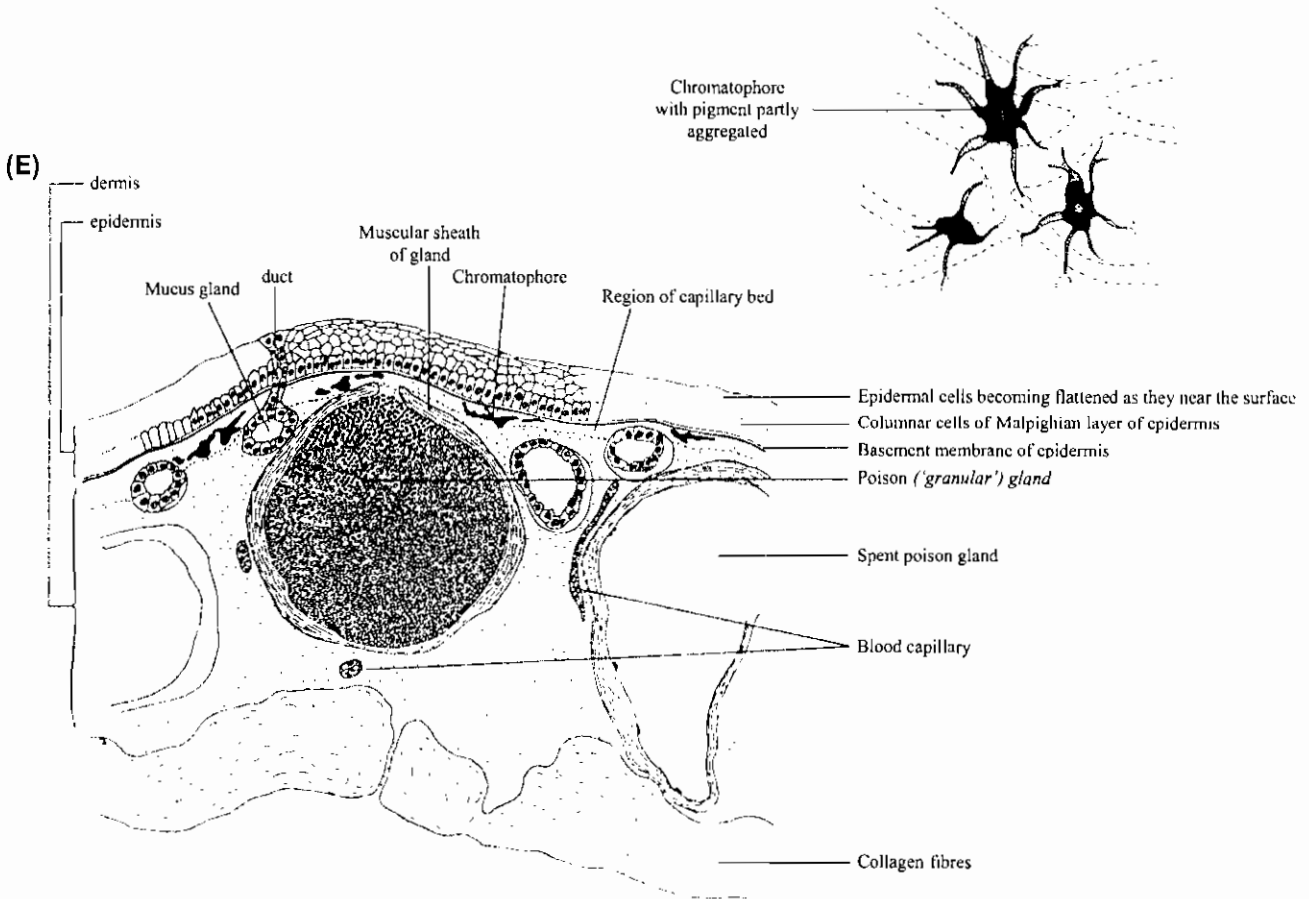


ق.ع. في منطقة الجذع لبرقة ضفدعة طولها ١٩ مم
 19-T. s. of the trunk region of 19mm. tadpole

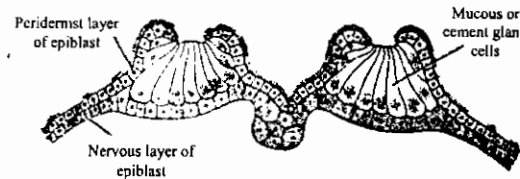
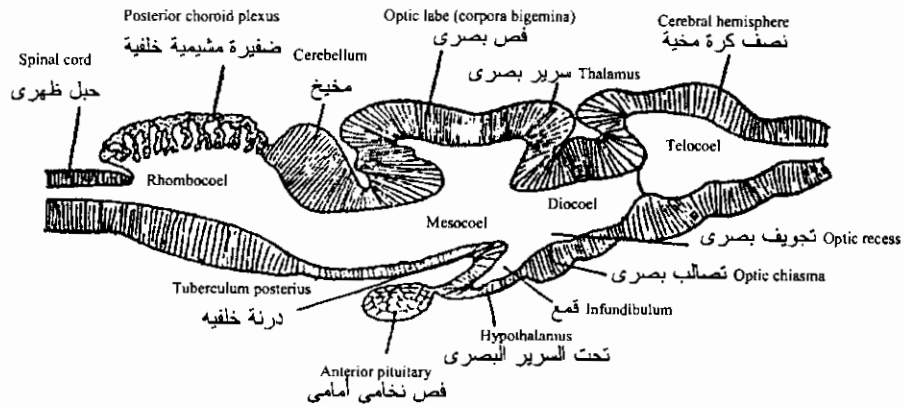
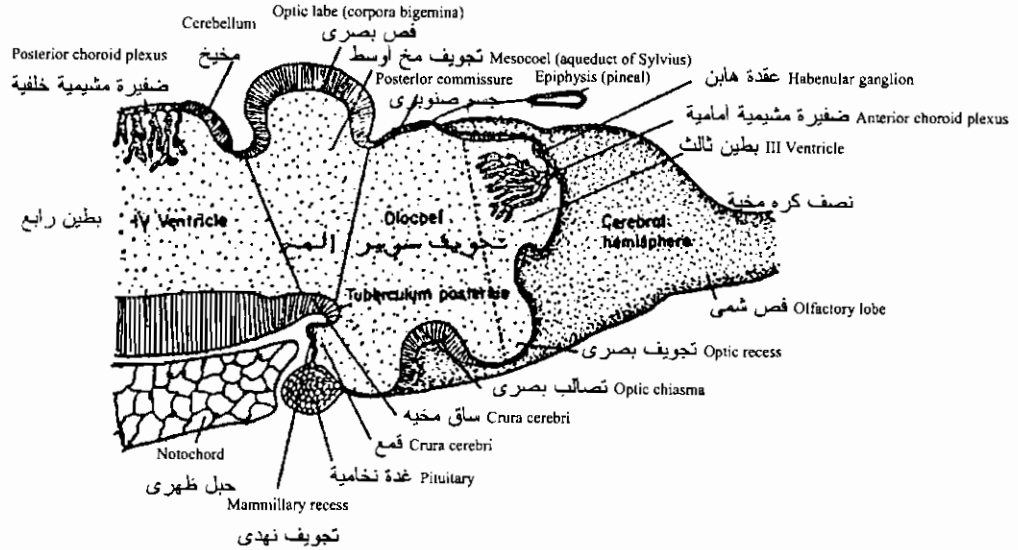
تكوين الجلد في الضفدعة



Development of skin of frog. A-Section of skin of early neurula; B-Section of skin of early tadpole; C-Section of skin of mature tadpole; D-Section of skin of a just metamorphosed frog (after Nelson, 1953). E. Section of skin of a frog.

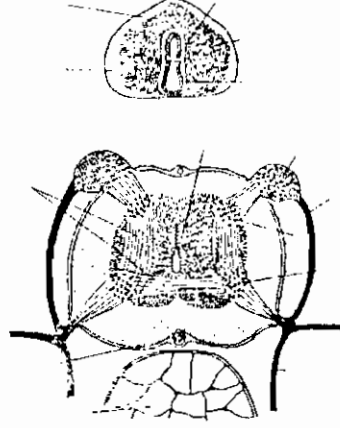


قطاعات طولية توضح تكوين المخ في الضفدعة: في الأعلى في يرقة قبل التحور وفي الأسفل في ضفدع بالغ
 Late development of the brain of the frog tadpole. (Top) Pre-metamorphic stage. (Bottom) Adult brain, schematized, reduced in size.

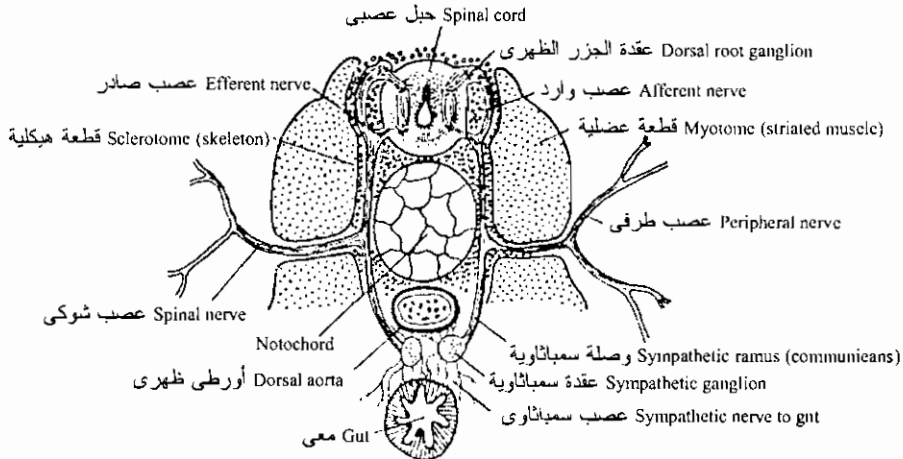


ق. ع. في ممص الإلتصاق لأبى زنبية
 Cross-section of an adhesive sucker of tadpole

قطاعات عرضية توضح تكوين الحبل العصبى والأعصاب فى الضفدعة

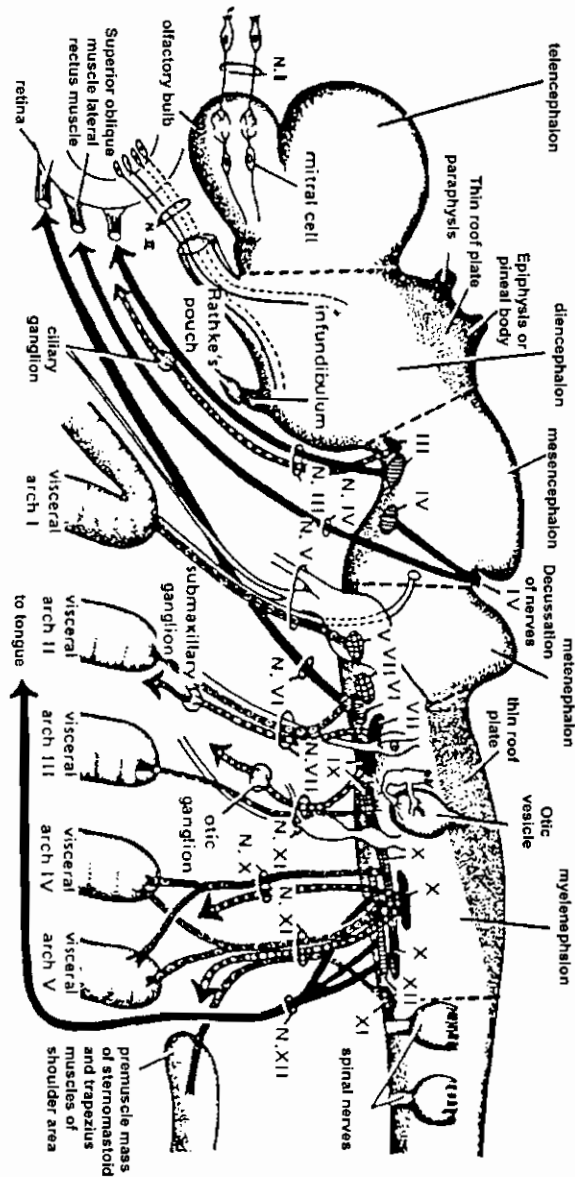


تكوين الحبل العصبى فى الضفدعة: بأعلى فى يرقة طولها 7مم وفى الأسفل فى يرقة قبل التحور مباشرة
Development of the spinal cord of the frog. (Top) Spinal cord of the 7mm. larva. (Bottom) Spinal cord just before metamorphosis.



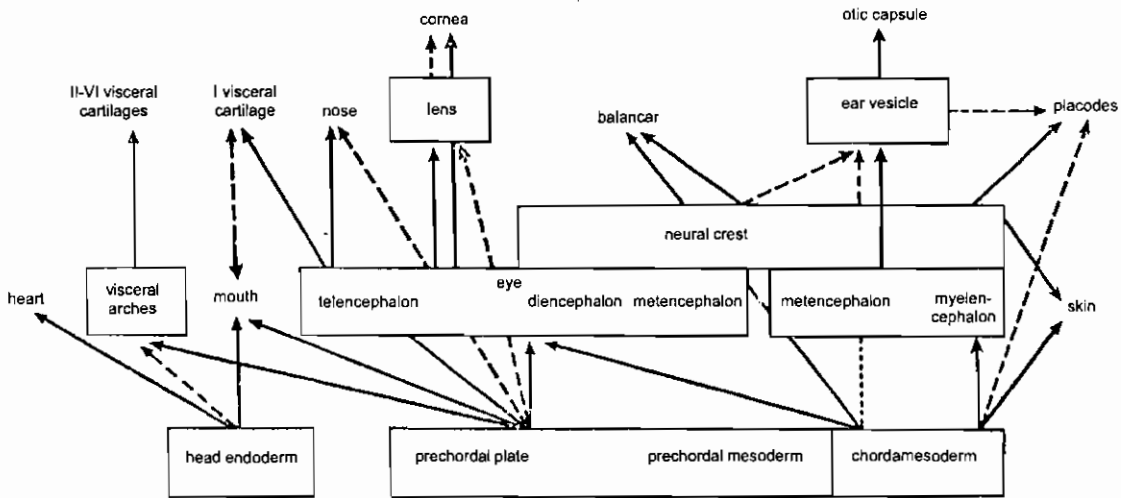
العلاقة بين الأعصاب الشوكية والسمبثاوية
Relation of the spinal and the sympathetic nervous systems.

تكوين الأعصاب المخية في الضفدعة



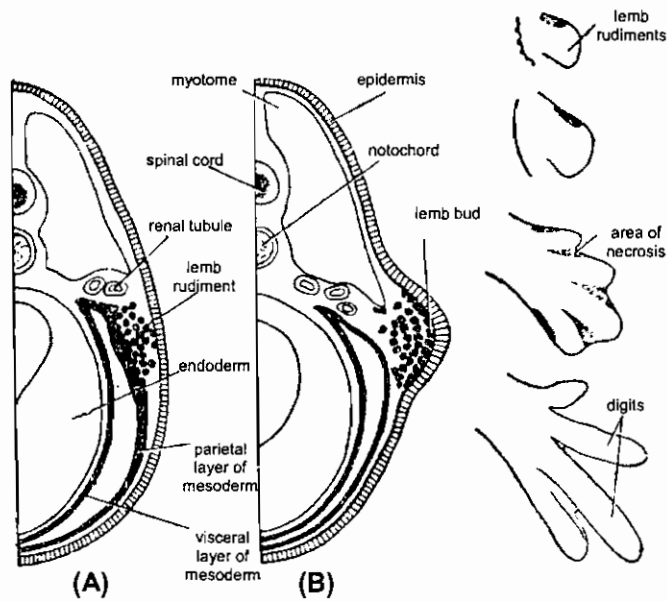
Schematic diagram showing the motor components of the cranial nerves. The nuclei of origin are shown to be located within fairly definite regions along the anteroposterior axis of the vertebrate brain. Somatic motor fibers are shown in solid black; special visceral motor fibers are indicated in black with white circles; general visceral motor fibers are black with white markings. [From O. E. Nelsen, "Comparative Embryology of the Vertebrates," McGraw-Hill, 1953.]

عمليات التحفيز وتكوين الطرف في الضفدعة



The induction process during early amphibian development in head region. The inductive action starts from the anterior part of archenteron roof (inductor of first degree-primary inductor), the inductors of second, third and following degrees effect the process by their own actions. The different strengths of the inductive actions are indicated by thick and broken arrows (after Berrill, 1971).

عمليات التحفيز المتتالية في منطقة الرأس في التكوين الأولى للضفدعة

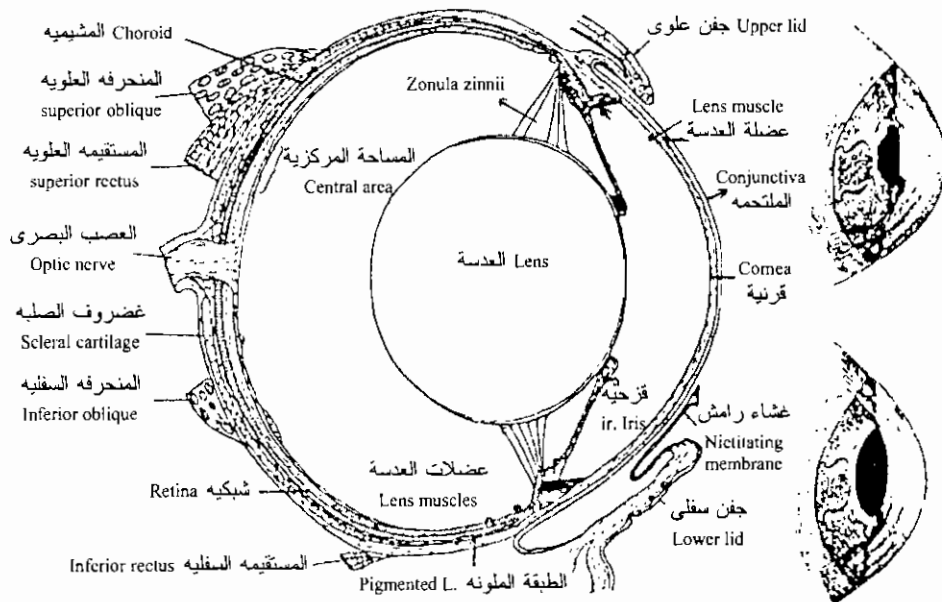
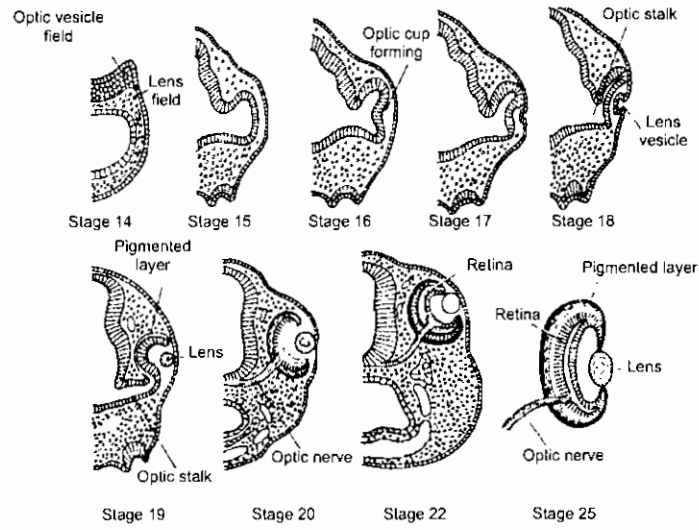


Origin of limb-mesoderm and formation of a limb-bud of an amphibian embryo. (after Balinsky, 1970).

Differentiation of a limb-bud into hind-bud into hind-limb of a vertebrate embryo (after Balinsky, 1970).

تكوين الطرف في الضفدعة

تكوين العين في الضفدعة
Development of the eye of the frog.

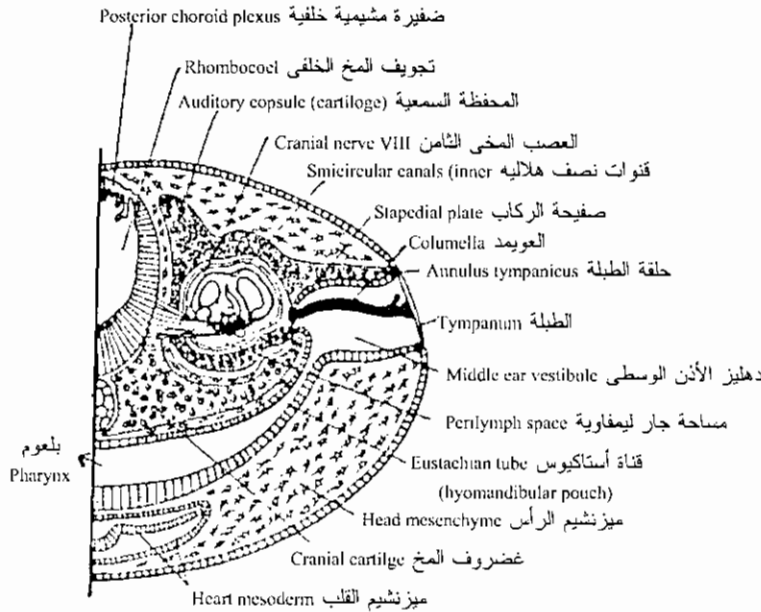
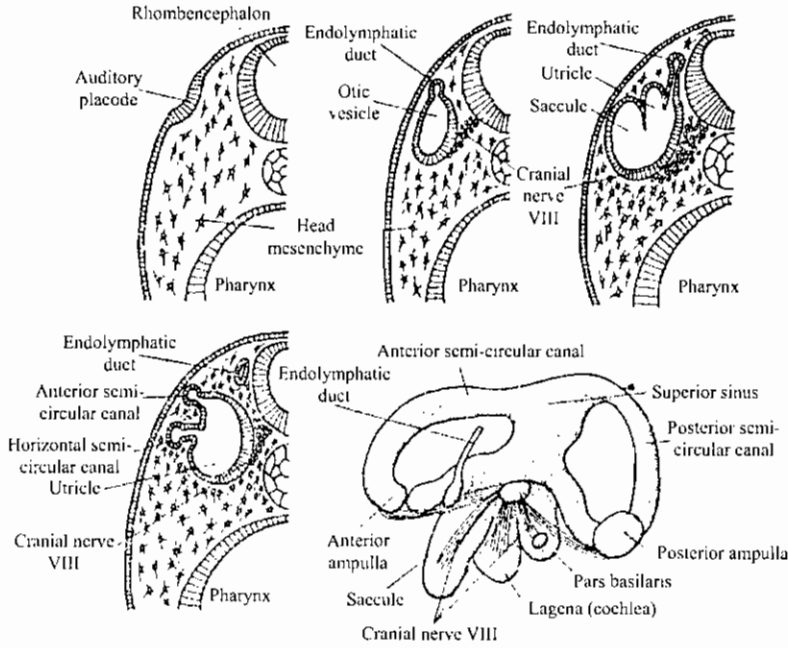


الضفدعة: منظر جانبي للعين وكيفية تأقلم العدسة مع الضوء

The amphibian eye and its accommodation. A anuran eye in vertical section. B, anterior segment of *Bufo* in relaxation. C, in accommodation; note forward movement of lens. (From walls 1942).

تكوين الأذن في الضفدعة

Development of the auditory apparatus of the frog. (Redrawn after Krause.)

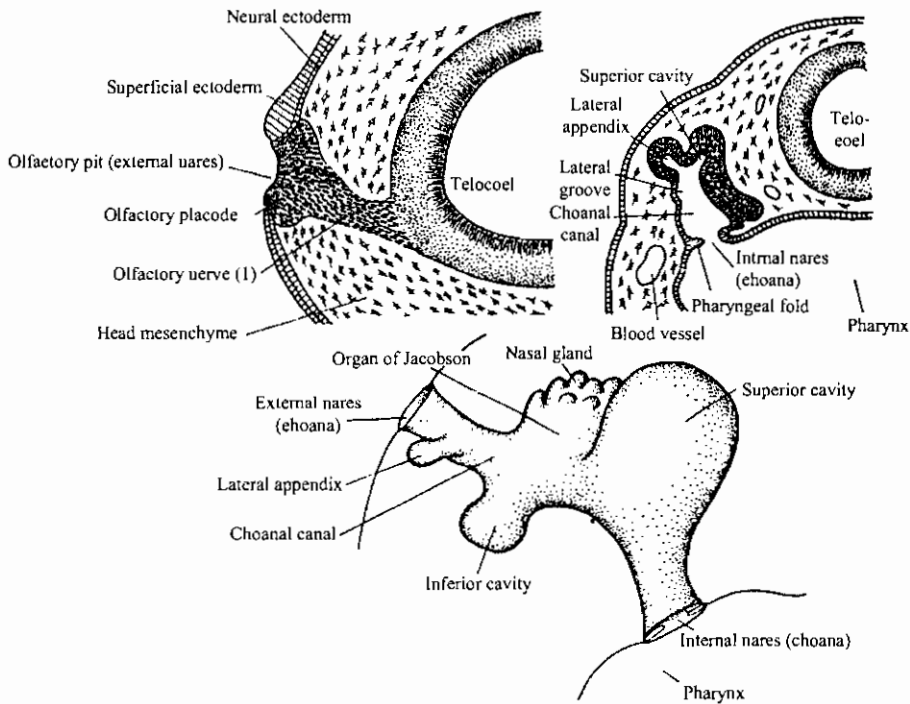
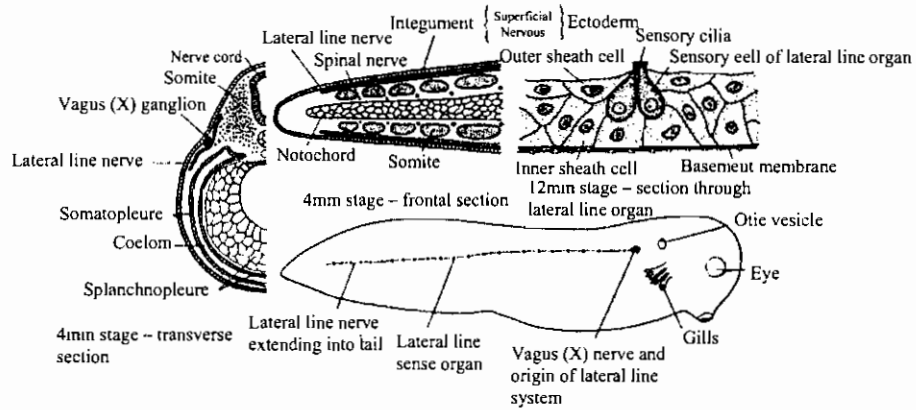


الصفدعة: رسم تخطيطي يوضح تركيب الأذن الوسطى والداخلية

Parts of the middle and inner ear of the frog, schematized drawing.

تكوين الخط الجانبي في يرقة الضفدعة

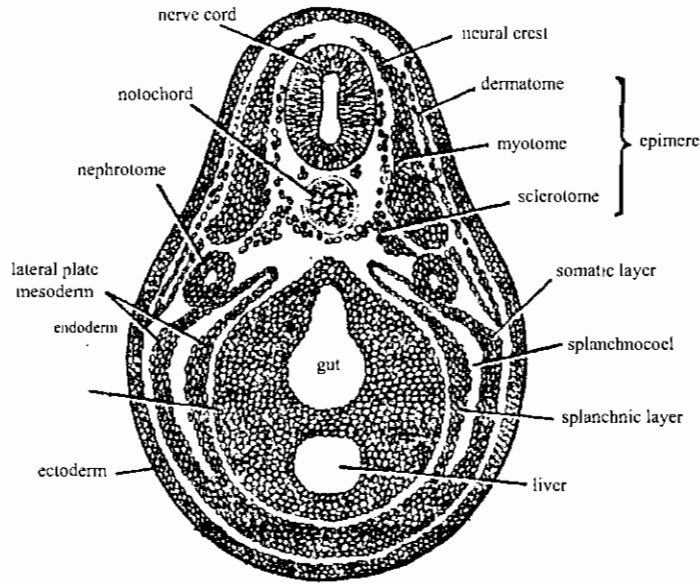
Origin of the lateral line sense organ system in the frog larva.



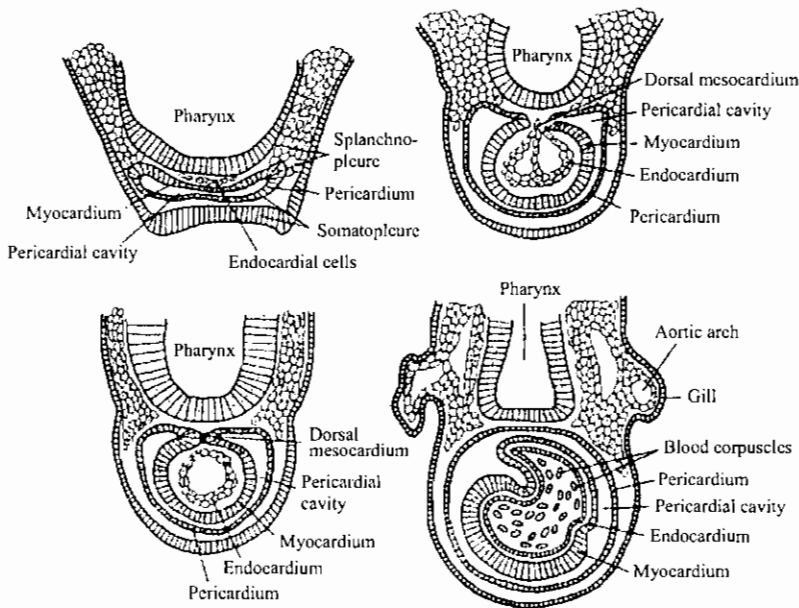
تكوين عضو الشم في الضفدعة

Development of the olfactory organ of the frog. (Top, left) Sagittal section through the olfactory placode and nerve. (Top, right) Posterior transverse section through the choanal canal. (Bottom) Schematic reconstruction of the embryonic olfactory organ.

قطاعات عرضية توضح
تميز الميزودرم والقلب في يرقة الضفدعة

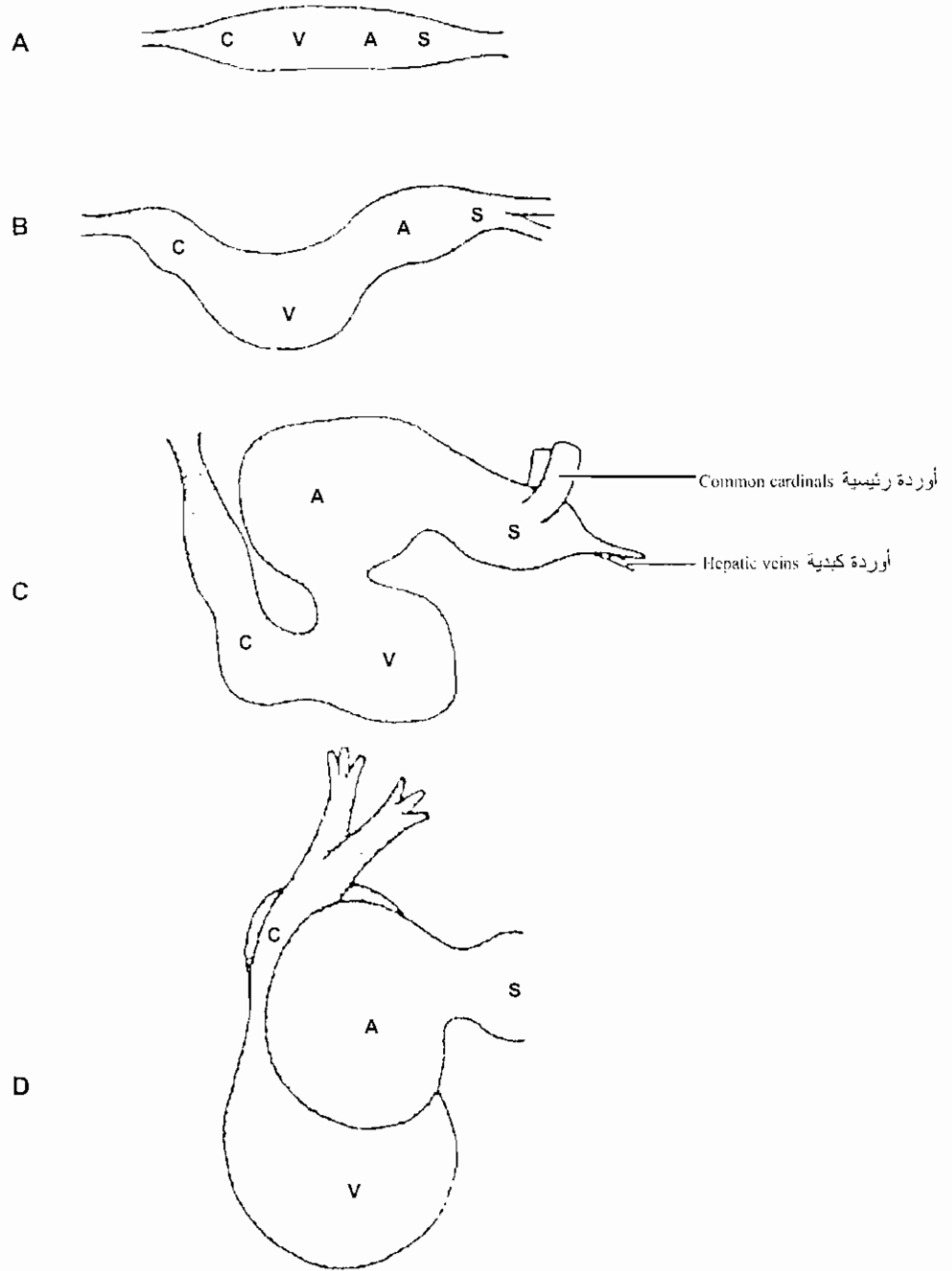


T. S. of a young tadpole through trunk region showing differentiation of mesoderm (after Huettner. 1949).



Development of the heart of the frog embryo.

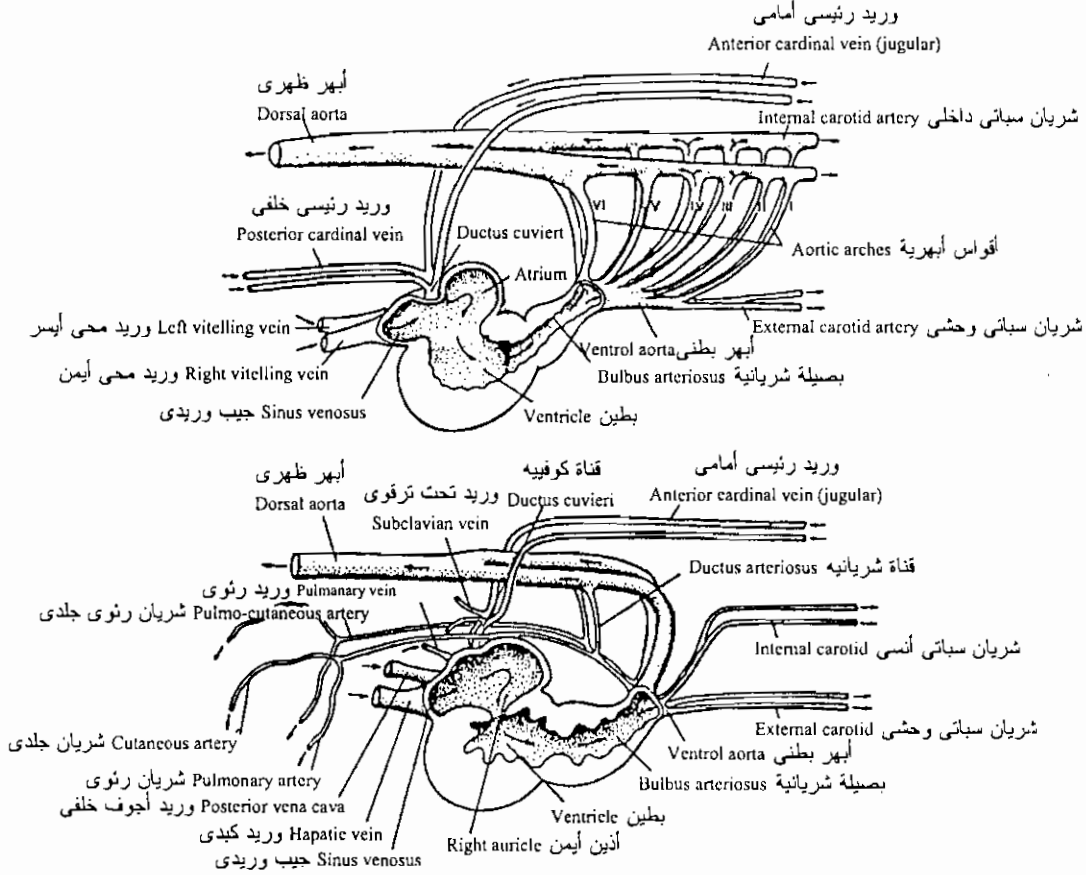
إلتفاف أنبوبة القلب في الضفدعة



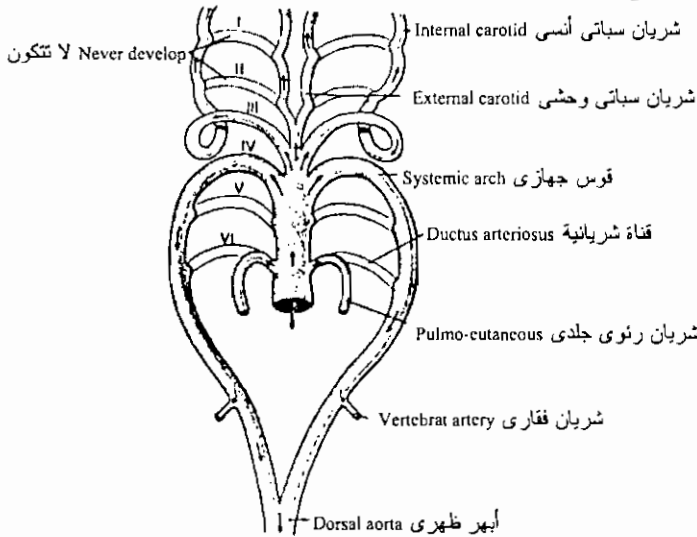
Heart rudiment of frog (and all vertebrates) develops as longitudinal tube that differentiates into four heart chambers. A, Starting at the posterior end, they are sinus venosus, S; atrium, A; ventricle, V; and conus arteriosus, C. B, The heart tube bends on itself, forming an S-shaped structure, C. As a result of the bending, the atrium's final position is dorsal and anterior to the ventricle, D.

تكوين الأوعية الدموية في الضفدعة

Blood vascular system of the developing frog embryo. (Top) Early embryo, from the right side. (Bottom) Late frog embryo, from the right side.



تكوين الجهاز الدوري في الضفدعة كما يرى من الجانب الأيمن



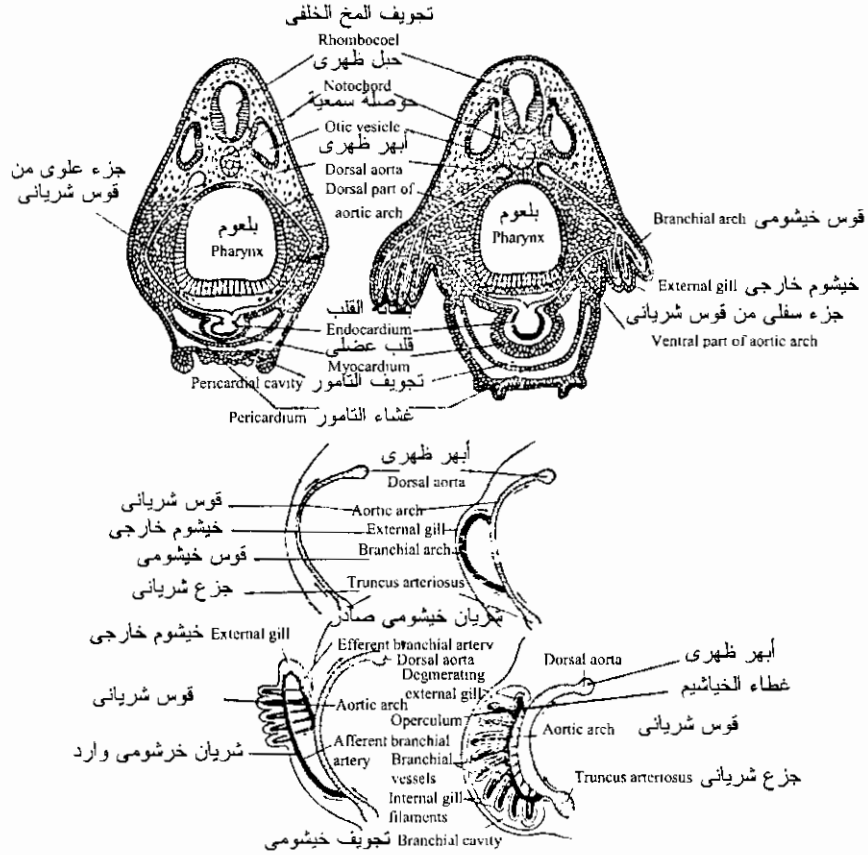
مصير الأقواس الشريانية في يرقة الضفدعة

Fate of the aortic arches of the frog embryo

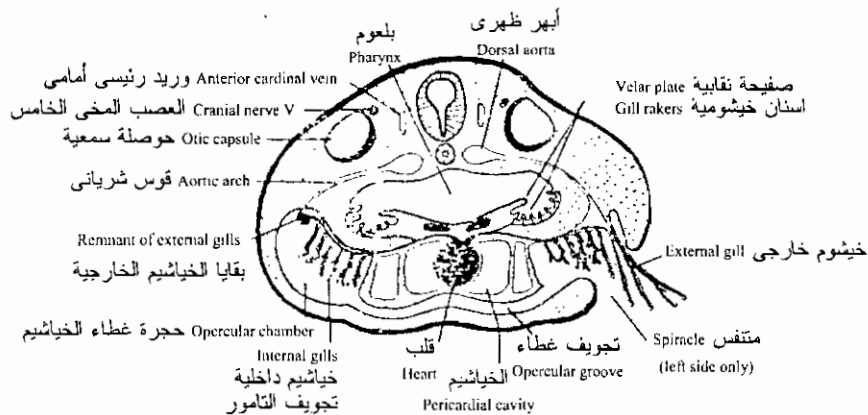
قطاعات عرضية توضح

تكوين الخياشيم وأعضاء التنفس في يرقة الضفدعة

Larval respiration in the frog. (Top) Development of the external gills. (Center) Changes from internal to external gill circulation.

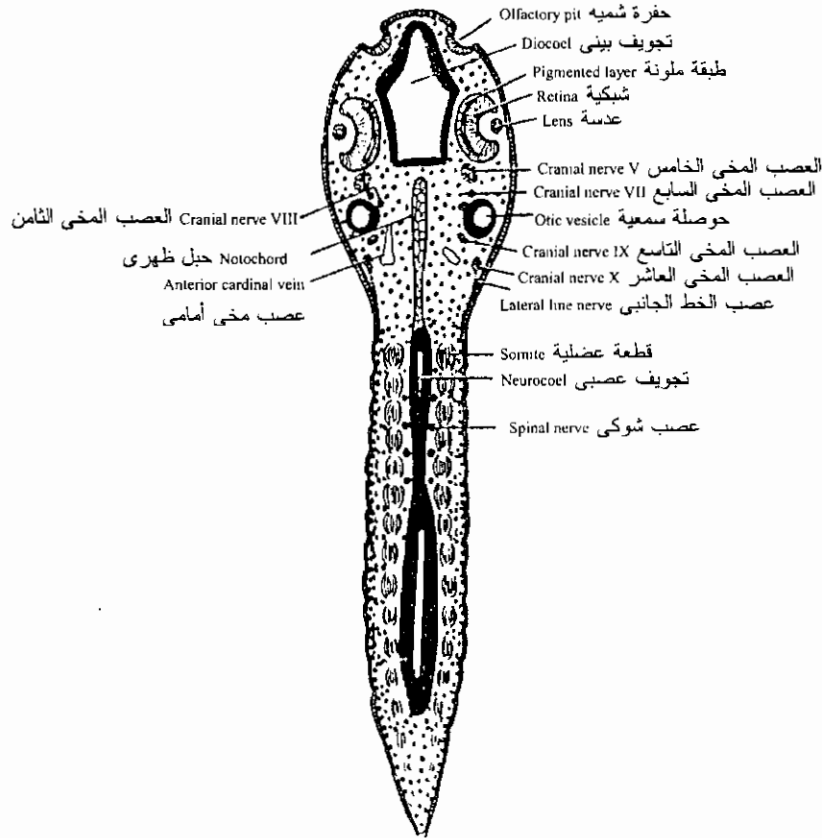


تكوين الجهاز التنفسي في الضفدعة وتكوين الخياشيم الخارجية



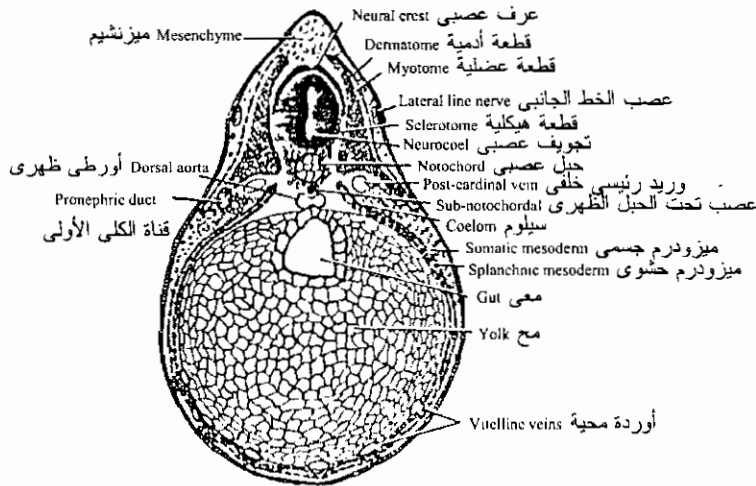
قطاع عرضي يوضح العلاقة بين البلعوم والخياشيم الداخلية والخارجية في الضفدعة
Relation of the pharynx to the internal and external gills of the frog. transverse section.

قطاعات في يرقة ضفدعة طولها ٧مم



قطاع جبهى في يرقة الضفدعة البالغ طولها ٧مم

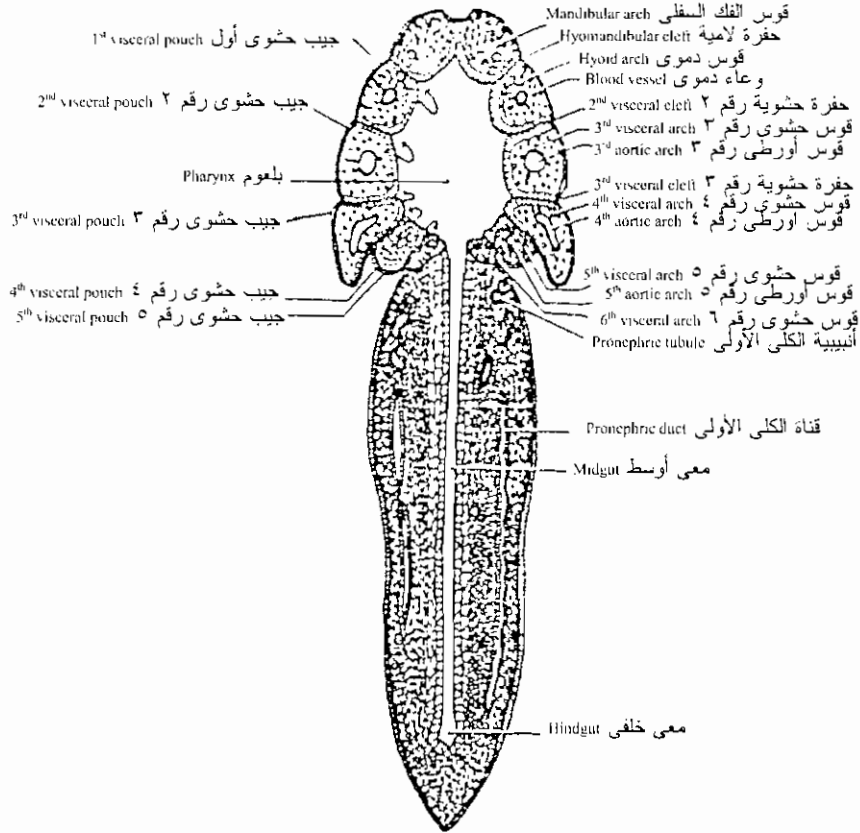
The 7mm. frog tadpole: frontal section.



قطاع عرضي في منتصف جسم يرقة الضفدعة البالغ طولها ٧مم

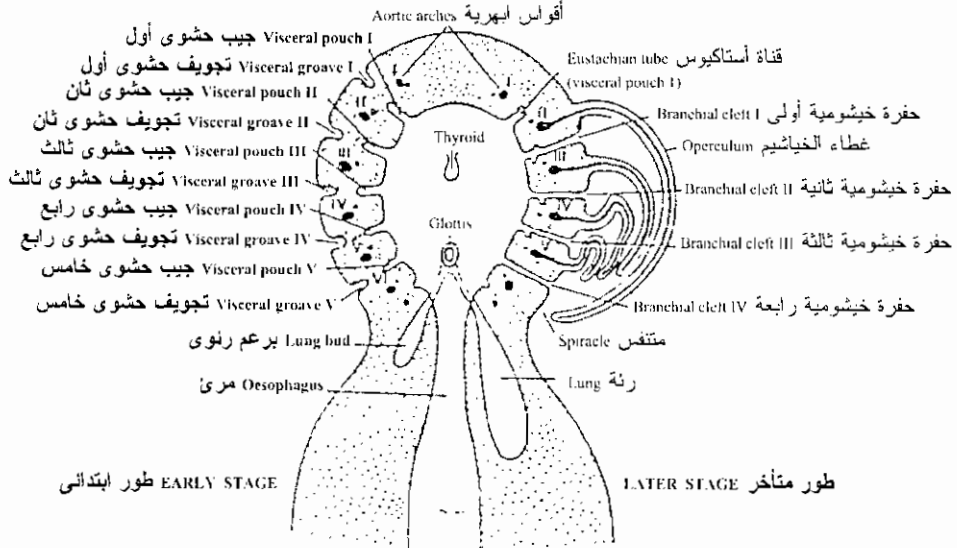
The 7 mm. frog tadpole: transverse sections. Through the mid-body level.

قطاعات في يرقة الضفدعة طولها 7 مم توضح أعضاء التنفس



قطاع جبهى في يرقة الضفدعة البالغ طولها 7 مم

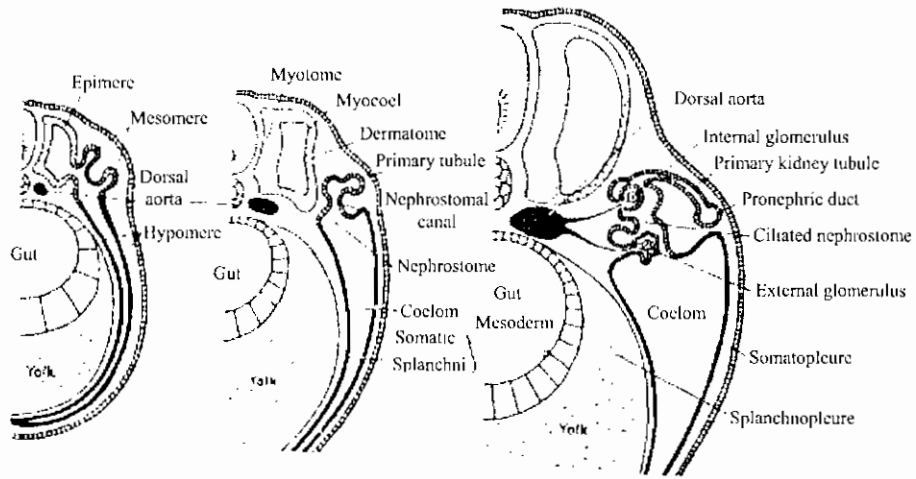
The 7mm. frog tadpole: frontal section



تكوين الجهاز التنفسي في الضفدعة

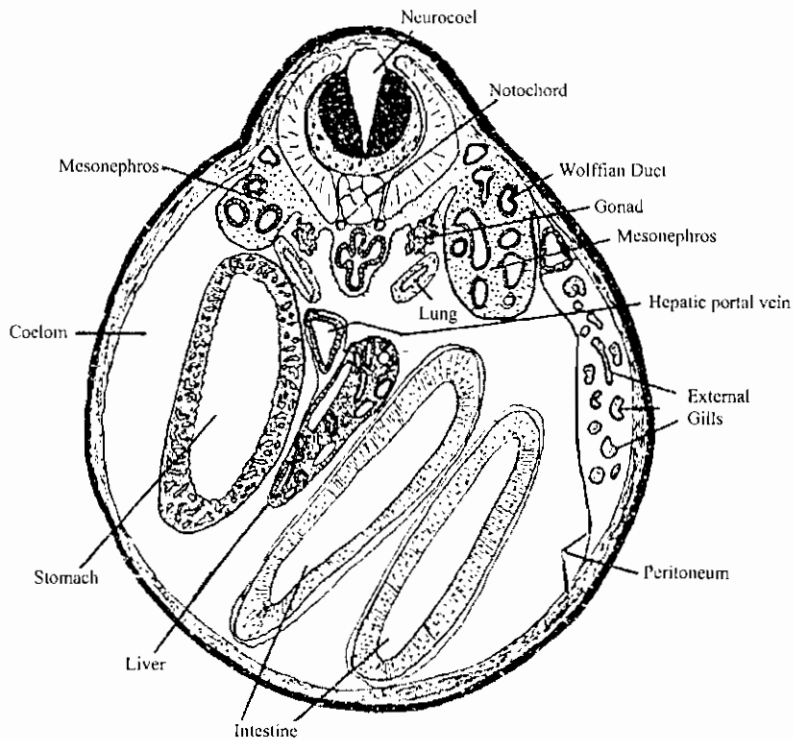
Development of the respiratory systems of the frog larva

قطاعات عرضية في يرقة ضفدعة توضح تكوين الكلية



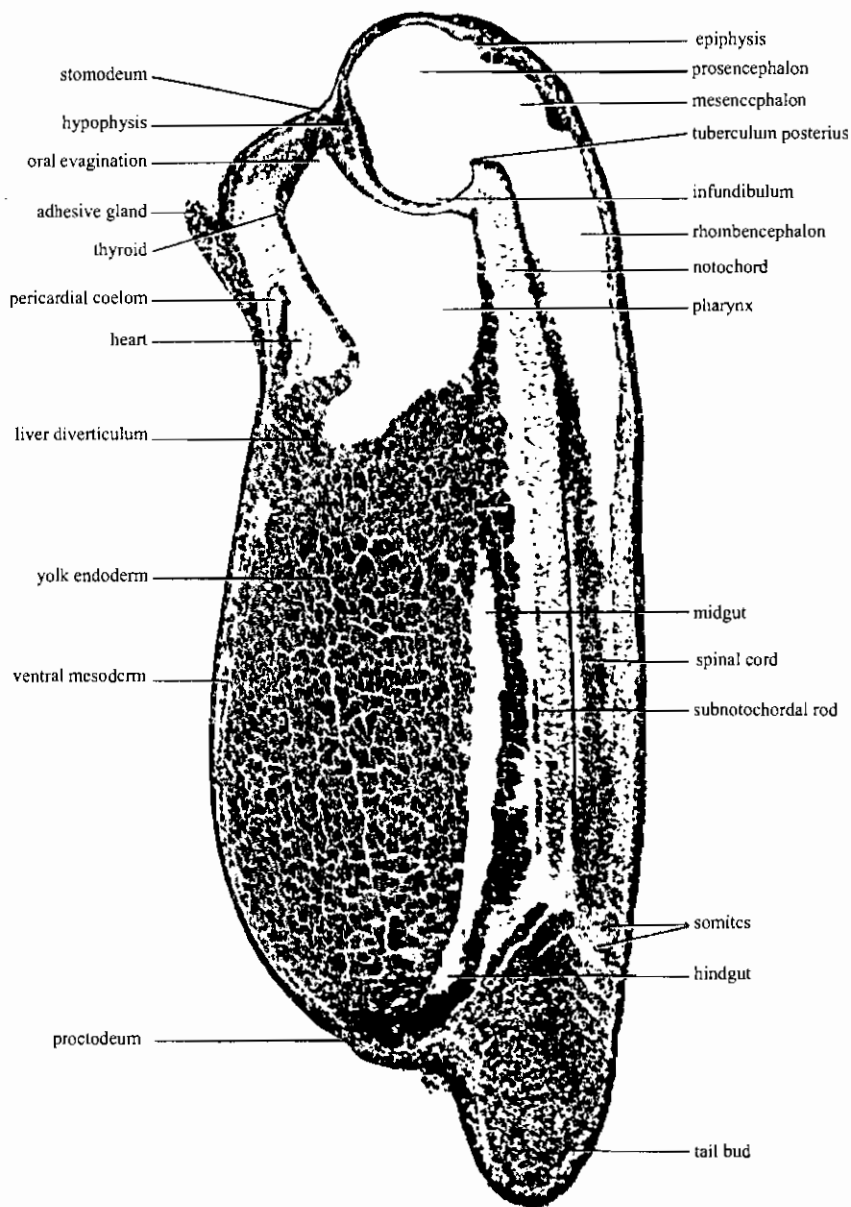
تكوين الكلية في الضفدعة

Development of the pronephric tubule. (Schematized after Felix.)



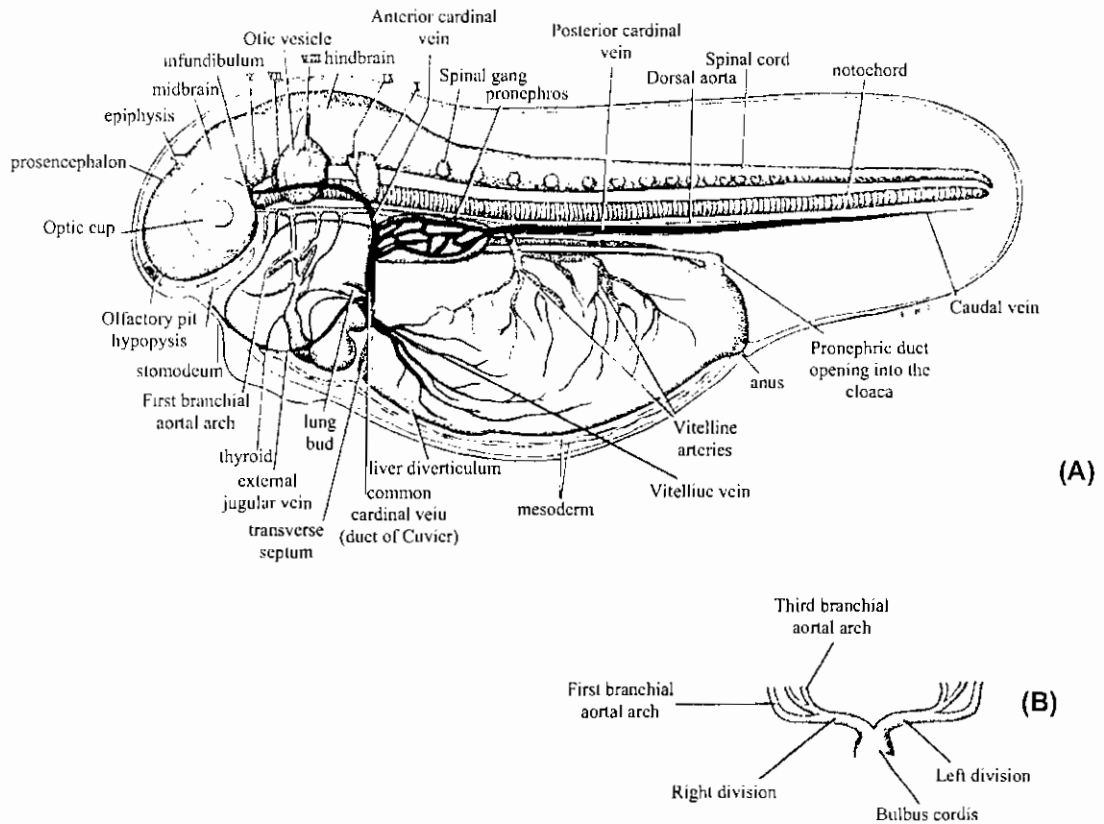
رسم تخطيطي لقطاع عرضي ليرقة ضفدعة طولها 11 مم في منطقة المنسل الأولى

Schematized diagram through the level of the gonad primordium of the 11mm. frog tadpole.



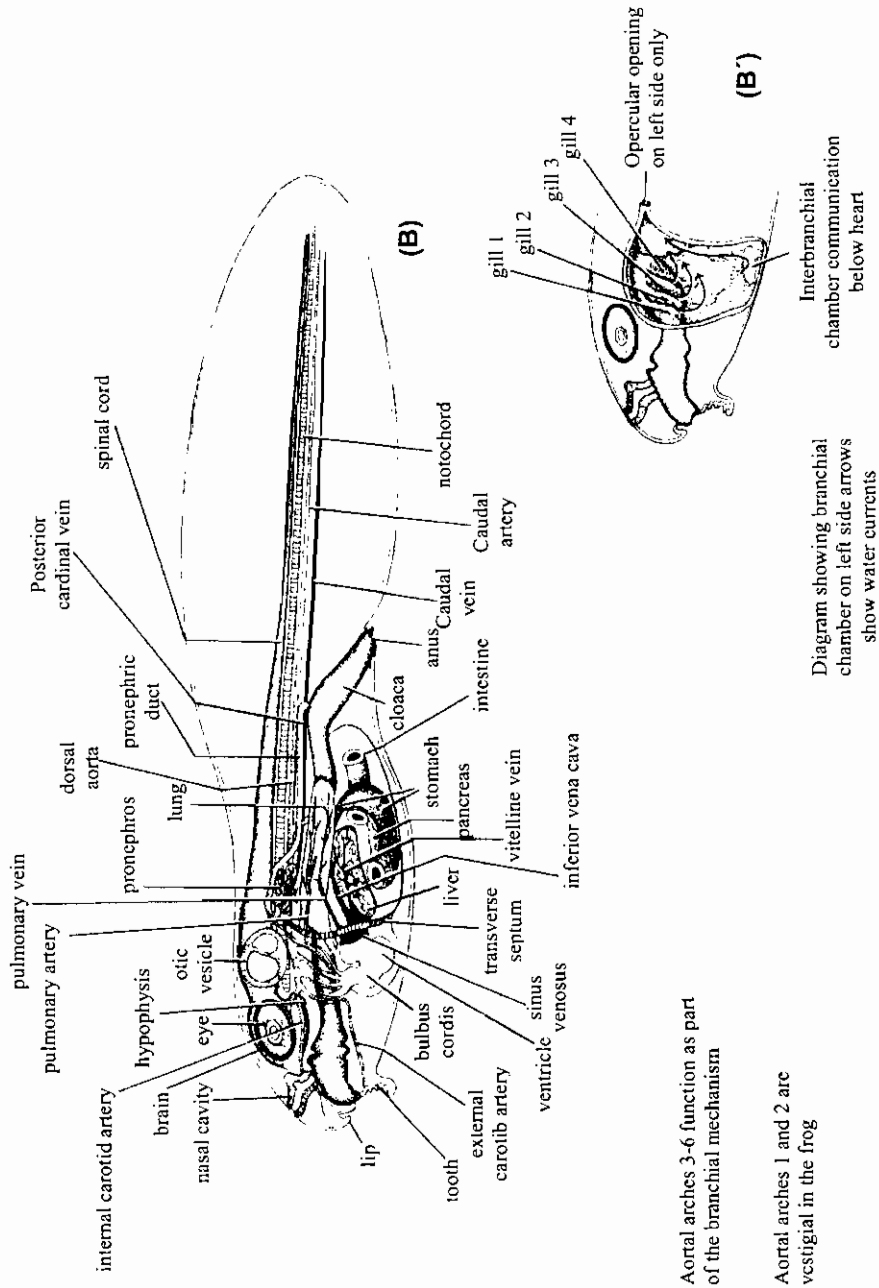
ق. ط. في جنين ضفدعة طوله ٤ مم

4mm frog embryo (Witschi stage 18), sagittal section (mag. 50X)



ق. ط. في يرقة ابي زنبية طولها من ٦-٧ مم

(A) Drawing of 6-7 mm frog tadpole (From Comparative Embryology of the Vertebrates by Olin E. Nelson. Copyright 1953 by the Blakiston Co. Inc. Used with permission of McGraw-Hill Book Company. (B) Drawing of the aortic arches of 6-7 mm frog tadpole.

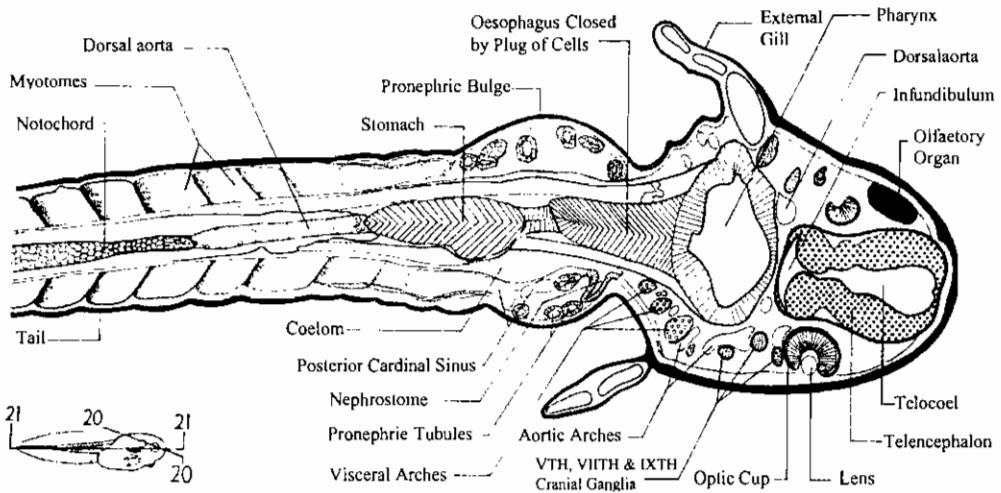
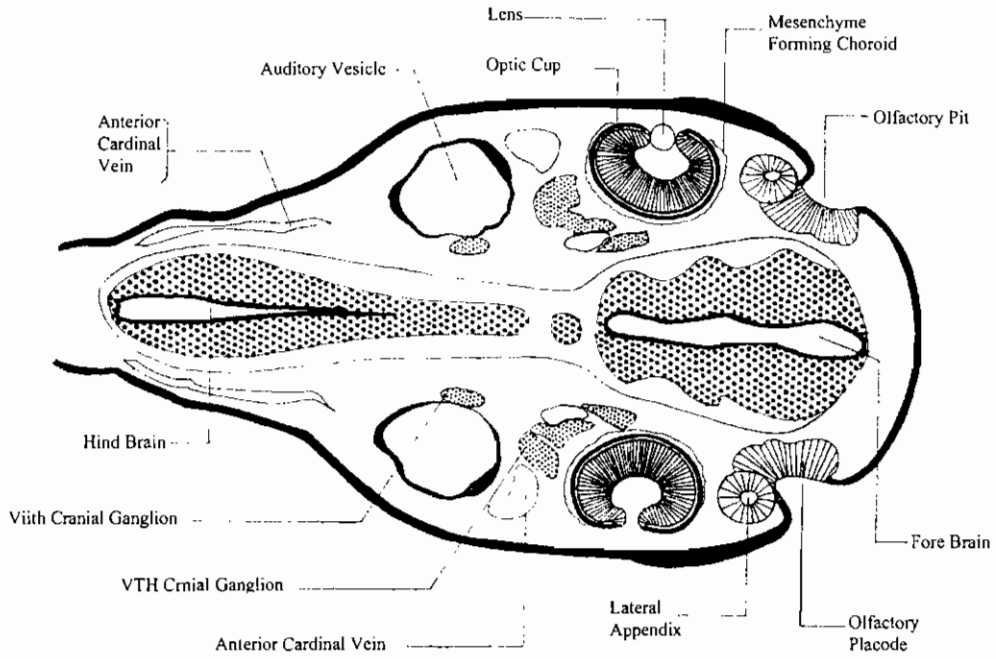


ق. ط. في يرقة أبي زنبقة طولها من ١٠-١٨ مم

Drawing of 10-18 mm frog tadpole. (From Comparative Embryology of the Vertebrates by Olin E. Nelson. Copyright 1953 by the Blakiston Co. Inc. Used with permission of McGraw-Hill Book Company.)

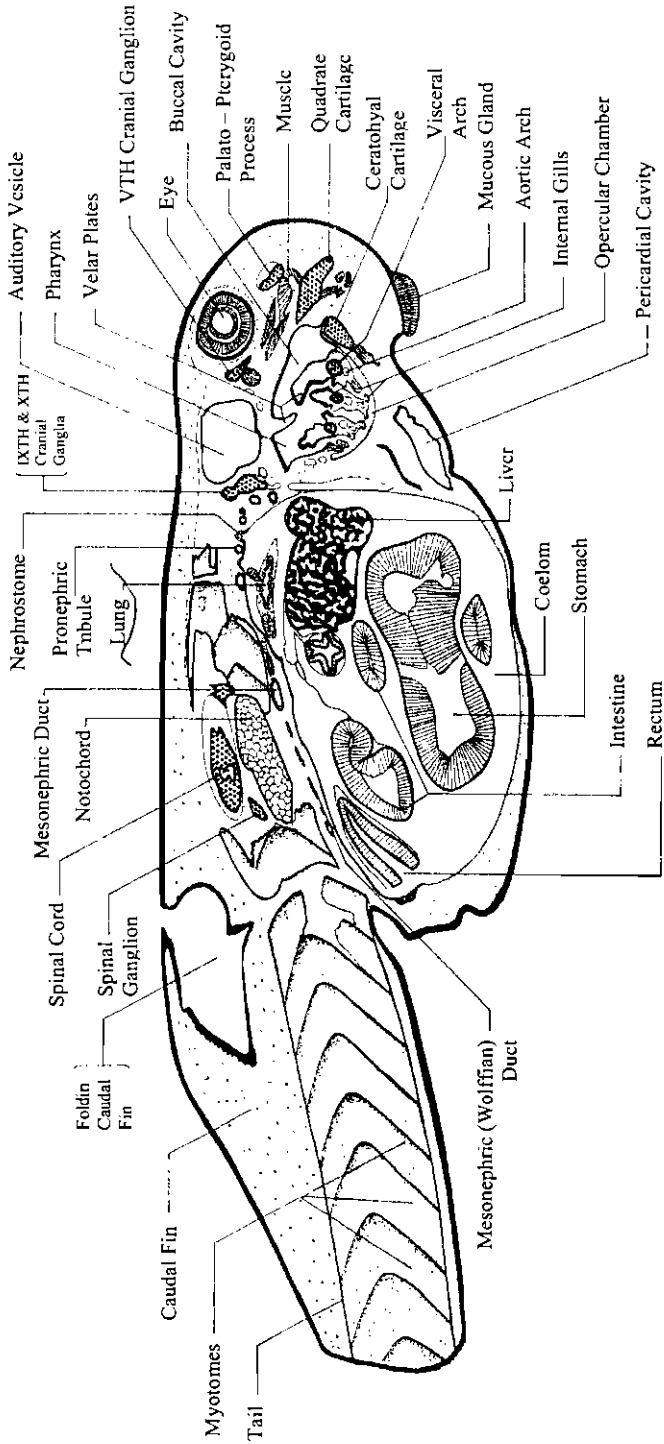
ق. مائل في جزء يرقة ضفدعة ذات خياشيم خارجية

Oblique s. of the trunk region of external gill frog larva

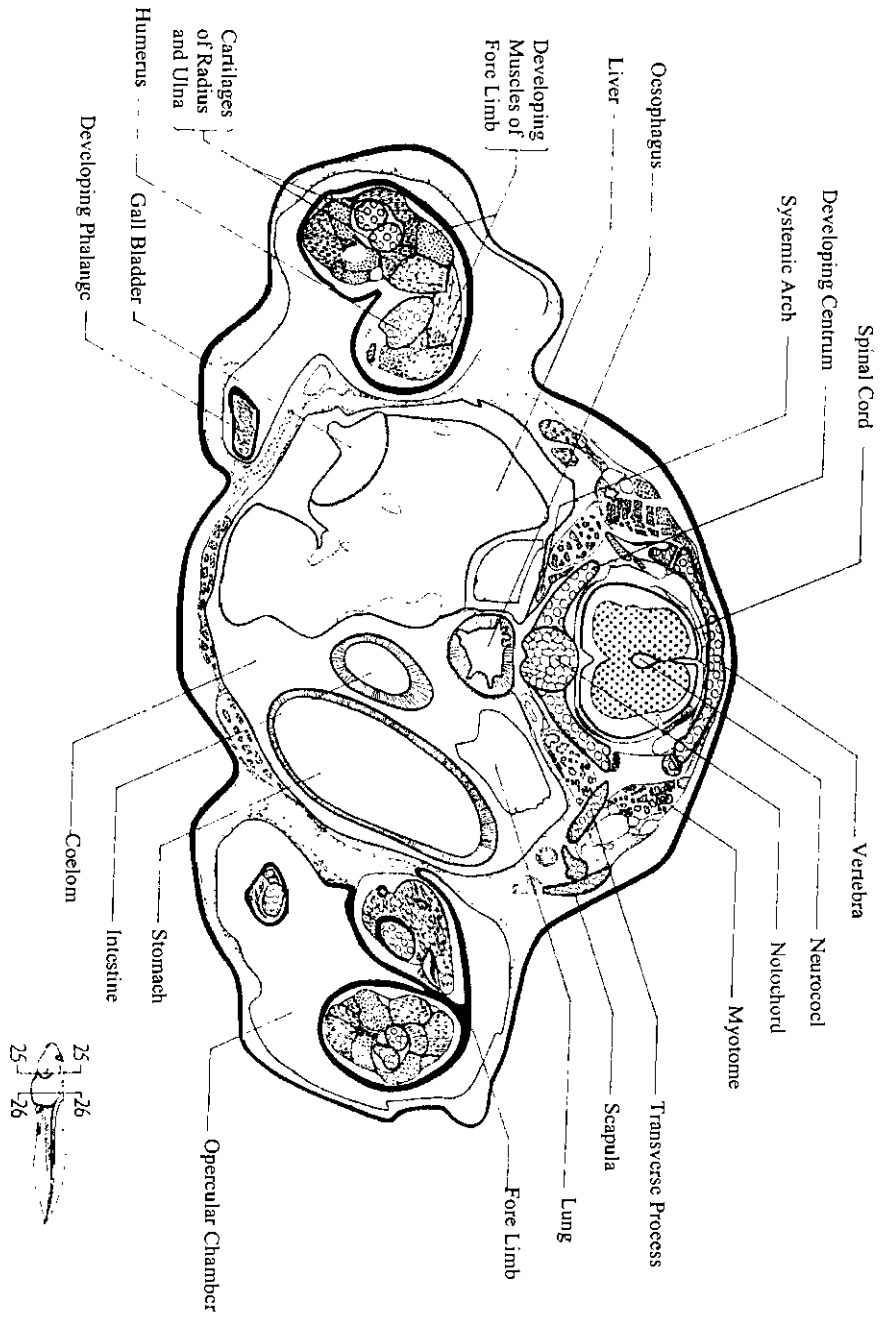


ق. أفقى في جزء يرقة ضفدعة ذات خياشيم خارجية

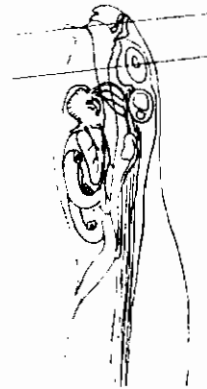
Horizontal s. of the head region of external gill frog larva



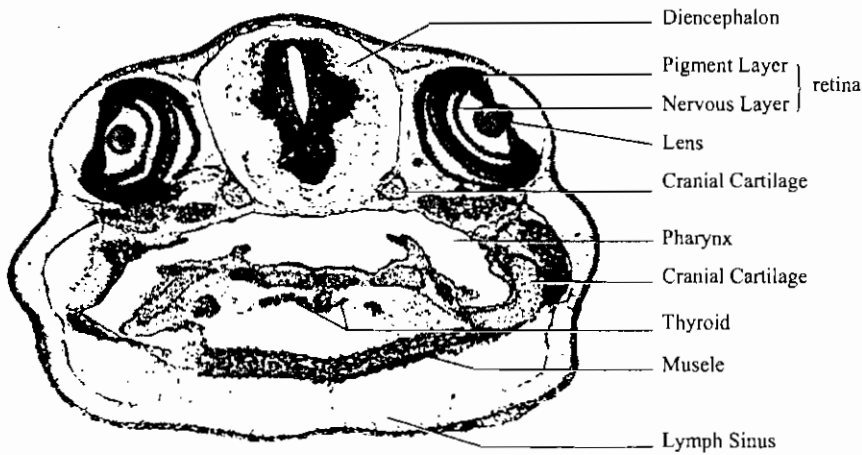
ق.ع. في منطقة الجرع ليرقة ضفدعة ذات خياشيم داخلية
 L.s. of the trunk region of internal gill frog-larva. X 40



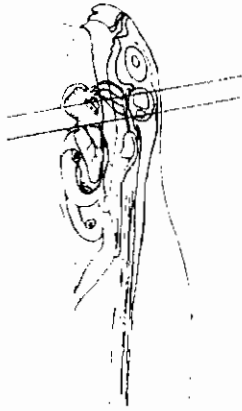
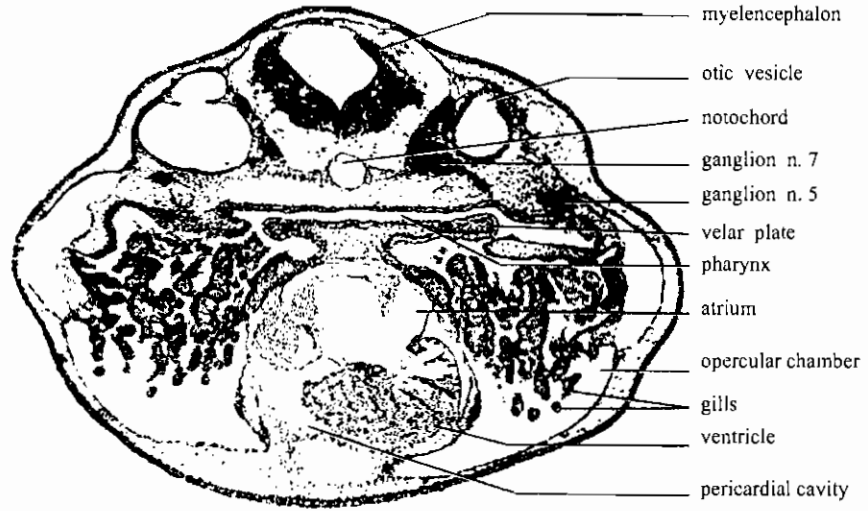
ق.ع. في منطقة الطرف الأمامي لبرقة ضفدعة طولها 19 مم
 T. s. of fore-limb region of 19mm. tadpole



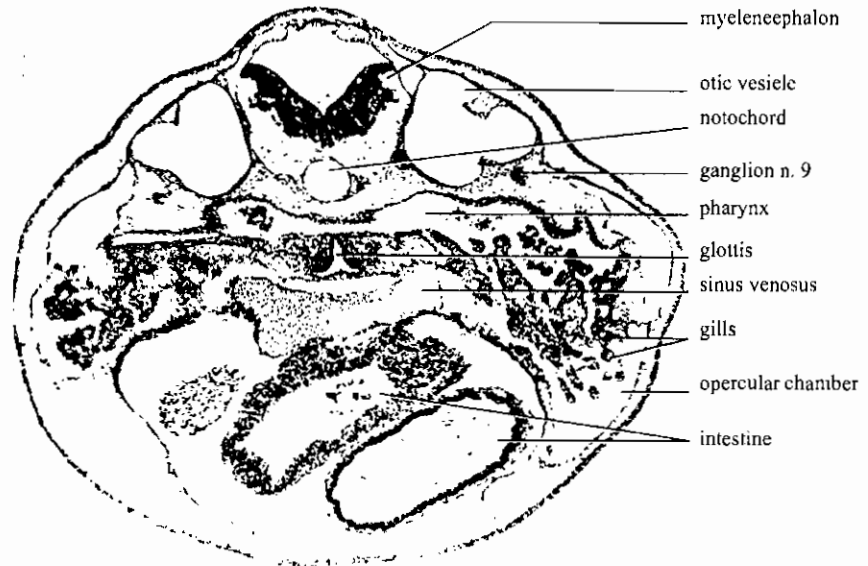
ق.ع. فى يرقة أبو ذنبية طولها ١٠ مم ويمر بعضو الشم
 10-mm frog tadpole (Witschi stage 24), transverse section through
 olfactory organ (mag. 50X)



ق.ع. فى يرقة أبو ذنبية طولها ١٠ مم ويمر بالعينين
 10-mm frog tadpole (Witschi stage 24), transverse section through eyes
 (mag. 50X)

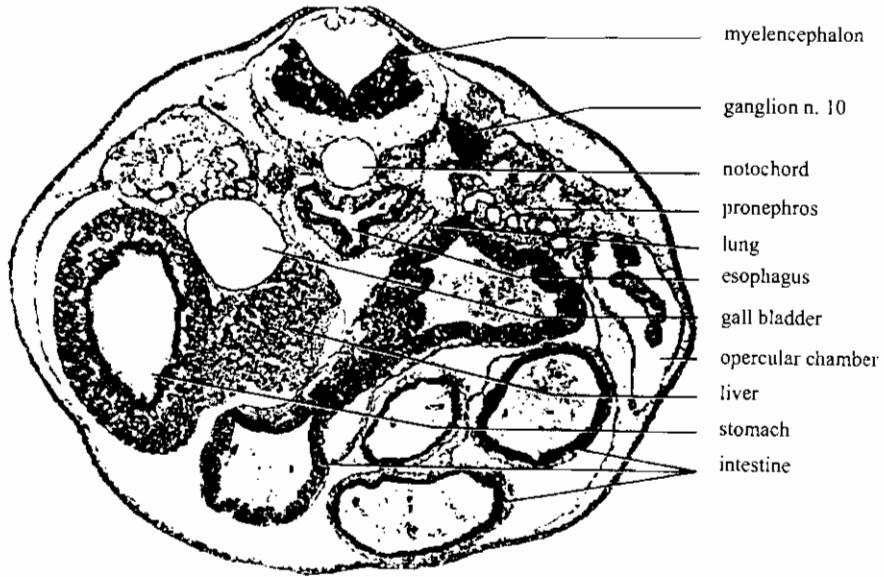


ق. ع. في يرقة أبو ذنيبة طولها ١٠ مم ويمر بالقلب
 10-mm frog tadpole (Witschi stage 24), transverse section through heart
 (mag. 50X)

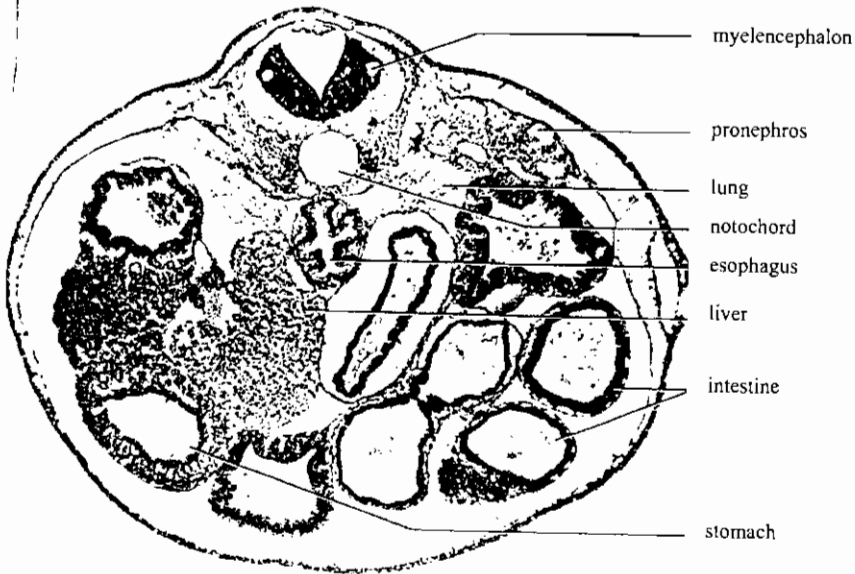


10-mm frog tadpole (Witschi stage 24), transverse section through glottis (mag. 50X)

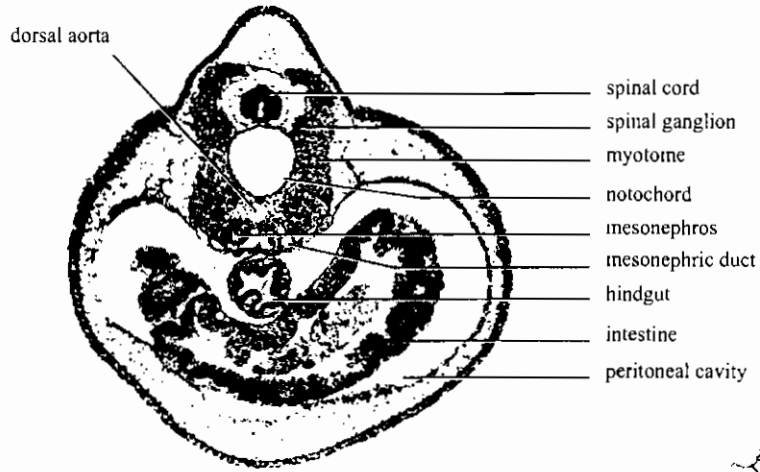
ق. ع. في يرقة أبو ذنيبة طولها ١٠ مم ويمر بفتحة الحنجرة



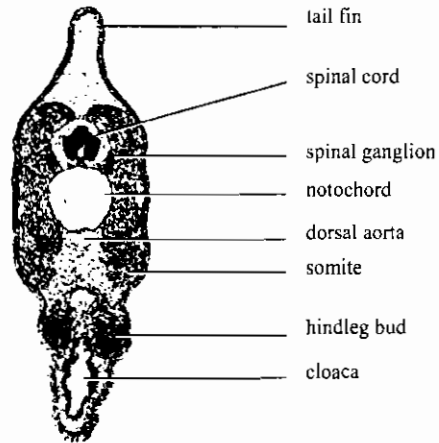
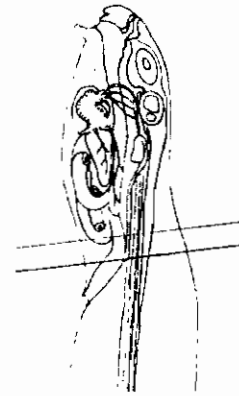
ق.ع. في يرقة أبو ذنيبة طولها ١٠ مم ويمر بمنطقة الكلى الأولى
 10-mm frog tadpole (Witschi stage 24), transverse section through
 pronephros (mag. 50X)



ق.ع. في يرقة أبو ذنيبة طولها ١٠ مم ويمر بالكبد
 10-mm frog tadpole (Witschi stage 24), transverse section through liver (mag. 50X)

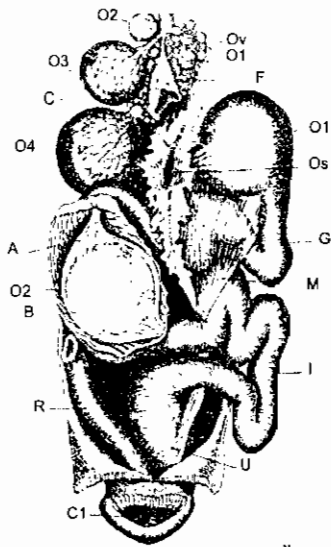


ق.ع. في يرقة أبو ذنبية طولها ١٠ مم ويمر بالكلية الوسطى
 10-mm frog tadpole (Witschi stage 24), transverse section through
 mesonephros (mag. 50X)

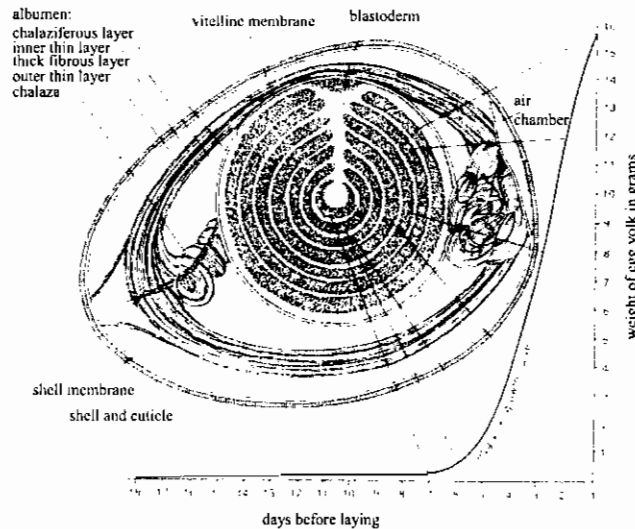


ق.ع. في يرقة أبو ذنبية طولها ١٠ مم ويمر بالمجمع
 10-mm frog tadpole (Witschi stage 24), transverse section through cloaca
 (mag. 50X)

الجهاز التناسلي الانثوي في الدجاجة

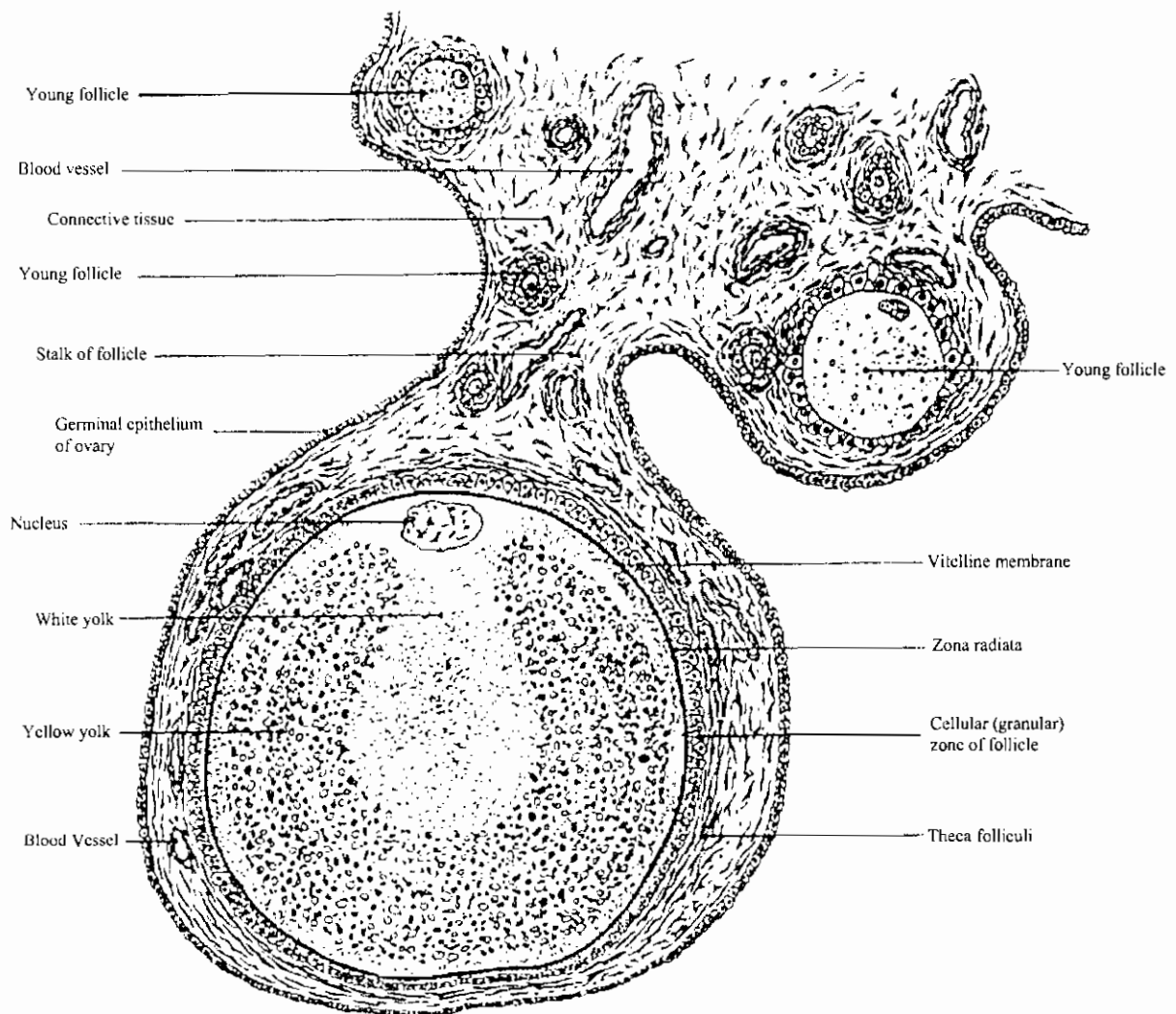


The female reproductive system of the fowl (After Coste-Duval.) The figure shows two eggs in the oviduct, though normally only one is in the oviduct at a time. A, albumen (dense layer); B, blastoderm; C, cicatrix; cl, cloaca; F, follicle from which egg has been discharged; G, Glandular portion of oviduct, I, isthmus; O₁-O₄, ovarian ova in different stages of growth, each enclosed in a follicle richly supplied with blood vessels; O₁, ovum in upper end of oviduct; O₂, ovum in middle portion of oviduct, which has been cut open to show the ovum in position; Os, ostium (infundibulum) of oviduct; Ov, ovary, R, rectum, U, uterus. (From H. L. Wieman, *An Introduction to Vertebrate Embryology*. Copyright 1949 by McGraw-Hill Book Co. Used with permission of McGraw-Hill Book Co.)



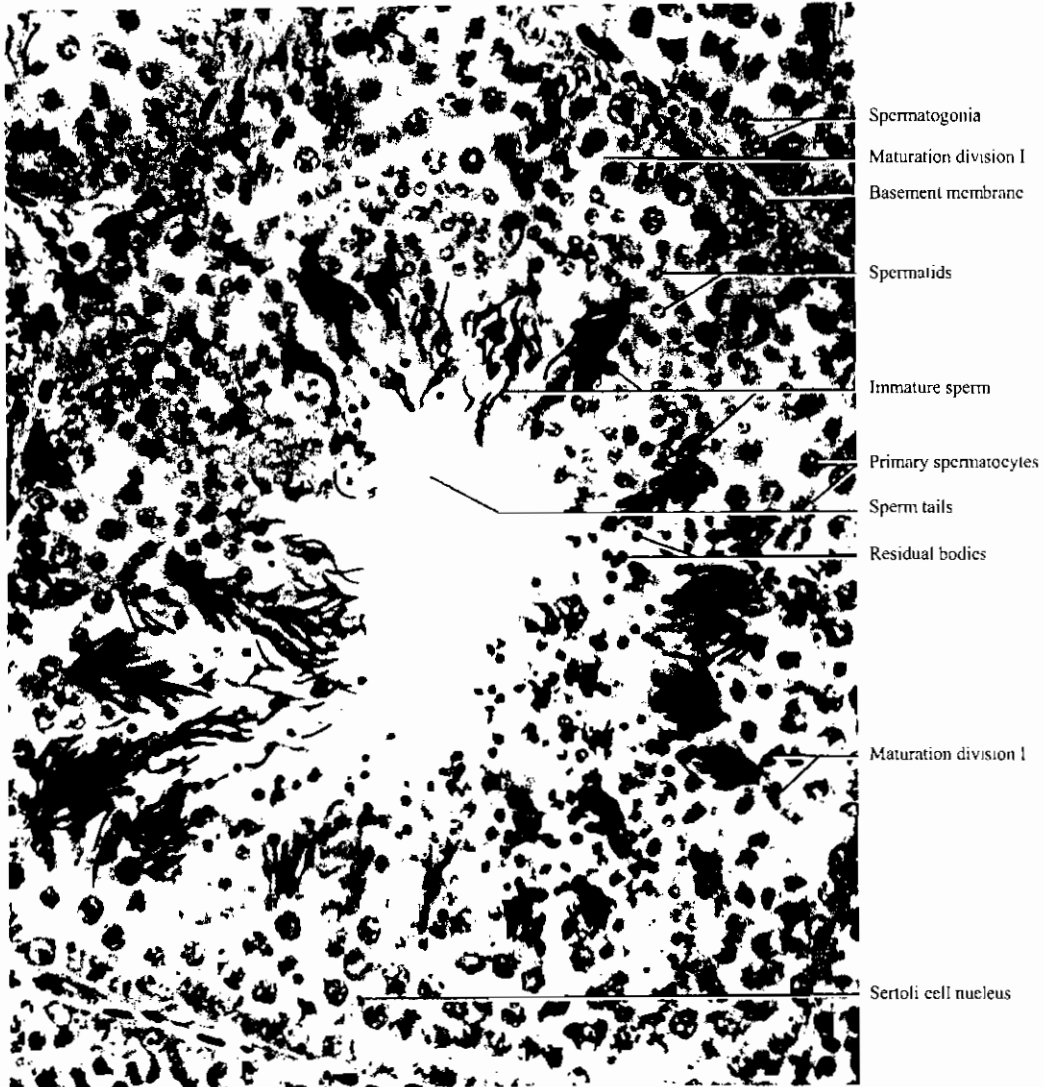
تركيب بيضة الدجاجة عند خروجها من الجسم

Growth and composition of hen's Egg before incubation. (Weight curve of ovocyte during 18 days preceding laying, after Gerhartz 1914.) The cells of the blastoderm are drawn relatively too large in size and too few in number. White yolk is lightly strippled, yellow yolk is heavily stippled (the central white yolk is called latebra of Purkinje, that below the blastoderm nucleus of Pander). Egg yolk, being relatively lighter than egg white, tends to float toward the highest part of the shell. (From *Development of the Vertebrates*, by Emil Witschi. Copyright © 1956 by W. B. Saunders Company. Used with permission of the W. B. Saunders Company, a division of CBS College Publishing.)



رسم تخطيطي يوضح تركيب البويضة الناضجة داخل المبيض

Diagram showing the structure of a bird ovum still in the ovary. (Modified from Lillie, after Patterson.) The section shows a follicle containing a nearly mature ovum, together with a small area of the adjacent ovarian tissue.

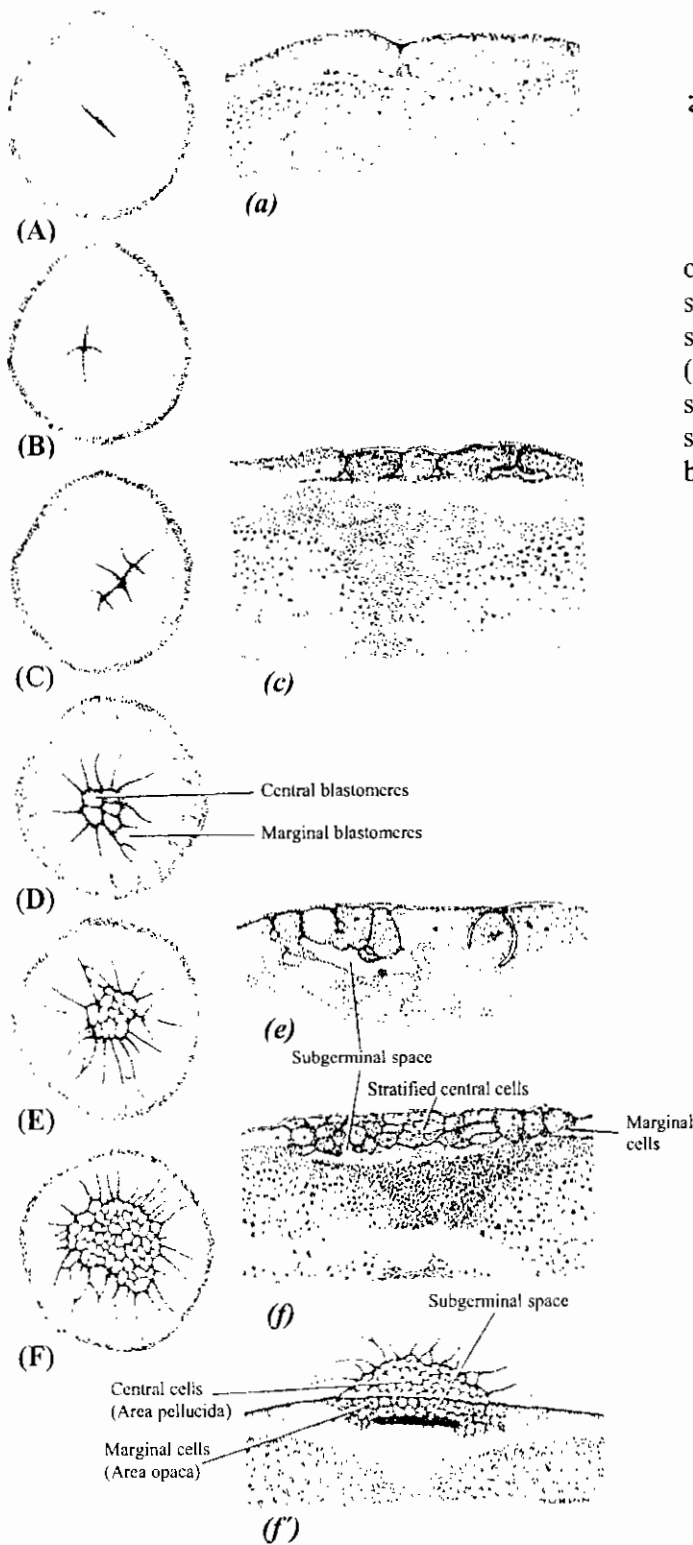


ق.ع. في أنبوبة منوية للكتكوت. تكبير ٦٨٠

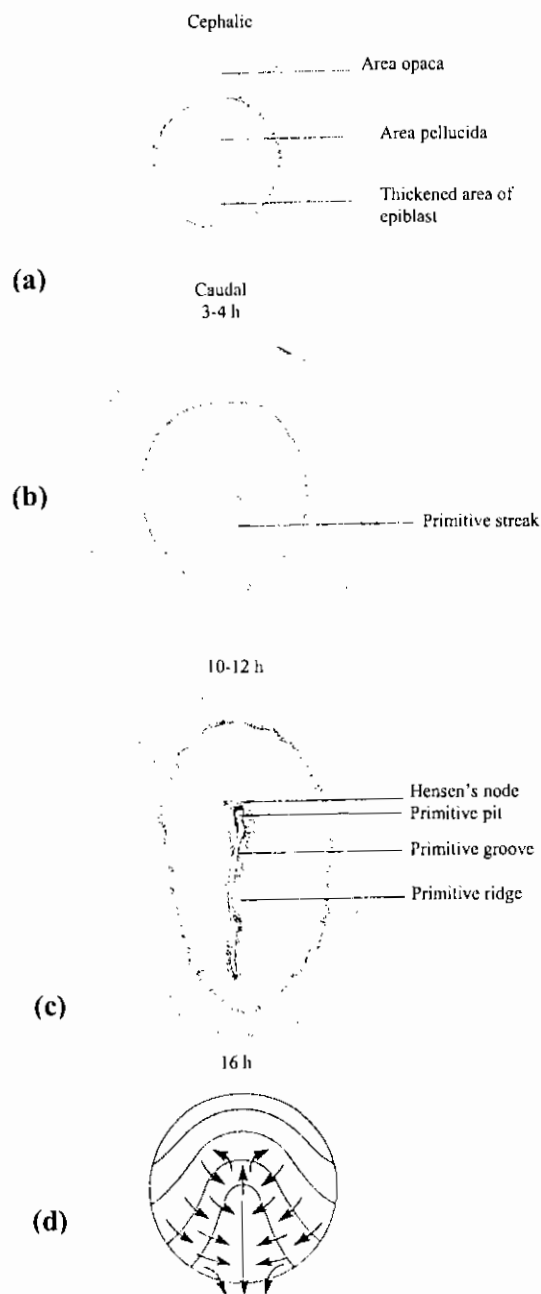
Chicken testis, section (mag. 680X)

التفلج في القرص الجرثومي في جنين الكتكوت
 كما يظهر من السطح العلوي أو في مقاطع عمودية

Cleavage of the germinal disc of the ovum of the domestic chicken. Left hand figures are surface views; right hand figures are transverse sections. (After Patterson.) (A, a) 2-cell stage. (B) 4-cell stage. (C, c) 8-cell stage. (D) 16-cell stage. (E, e) 32± cell stage. (F, f) 154± cell stage. (f') Diagrammatic hemisection of blastoderm of 154± cells.

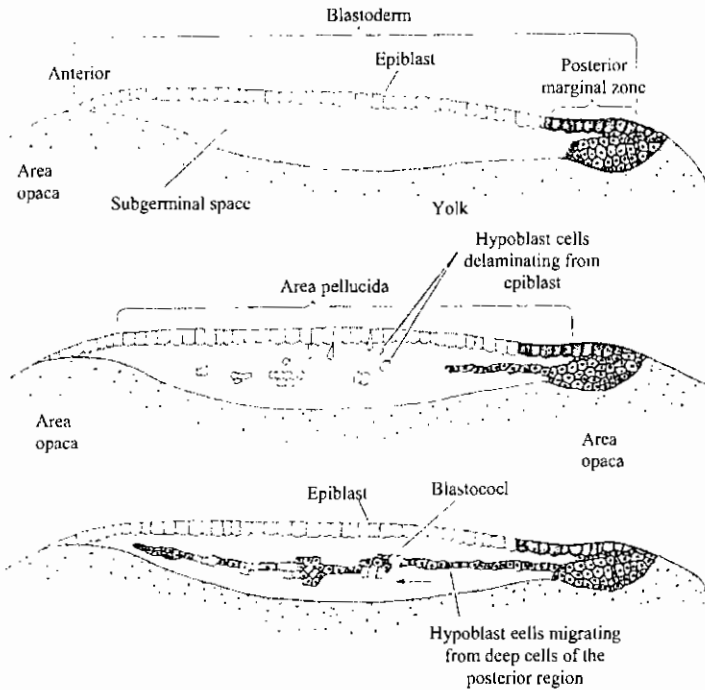


تكوين الشق البدائي في جنين الكتكوت كما يظهر من السطح الظهري

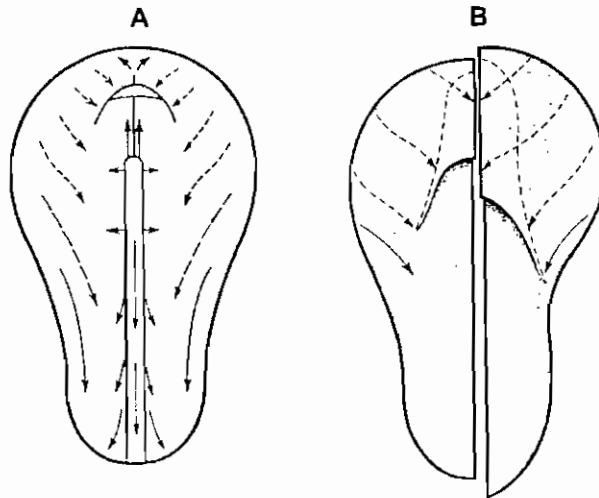


Primitive streak formation in the chicken embryo. All drawings show dorsal views of the epiblast. Most of the large uncleaved yolk has been omitted. (a) 3-4 h incubation. (b) 10-12 h incubation. (c) 16 h incubation. (d) Interpretative diagram of cell movements.

تكوين بلاستوله الكتكوت



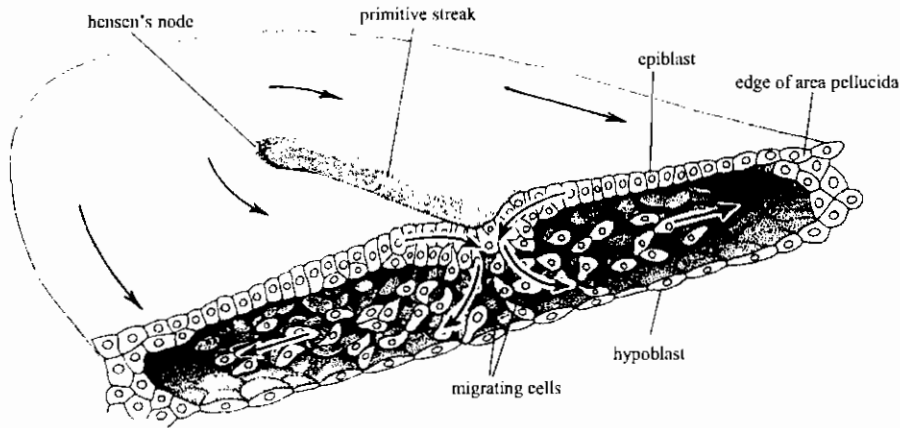
Formation of the two-layered blastoderm of the chick embryo. The first hypoblast cells delaminate individually to form islands of cells beneath the epiblast. Cells from the posterior margin (Koller's sickle and the posterior marginal cells behind it) produce a population of cells that migrates beneath the blastodisc and incorporates the polyinvagination islands. This bottom layer becomes the hypoblast. The upper layer is the epiblast. As the hypoblast moves anteriorly, epiblast cells collect at the region anterior to Koller's sickle to form the primitive streak.



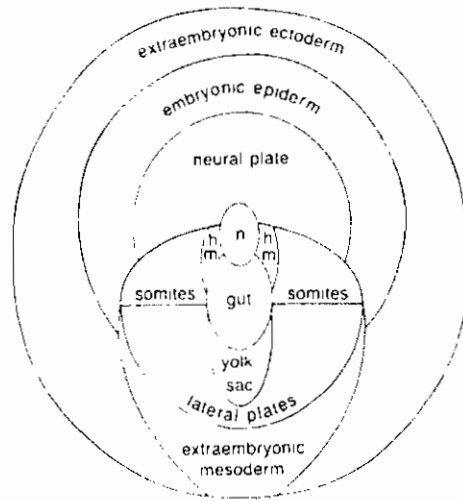
حركة الخلايا الاندودرمية أثناء تكوين المعى الأمامي في جنين الكتكوت

Morphogenetic movements during foregut formation. When labelled cells were followed in the endoderm of the chick embryo, two types of cell movement were found. (a) '2-dimensional', which stayed in the original plane: black arrows; (b) '3-dimensional', which moved ventrally: dotted arrows. A. headfold stage. B. two later stages. Both A and B are viewed from the ventral (endodermal) side. (From Bellairs, 1953.)

النصف الأمامي من المنطقة الشفافة ومقطع عرضي بها يظهر إنعقاد الخلايا الميزودرمية والاندودرمية



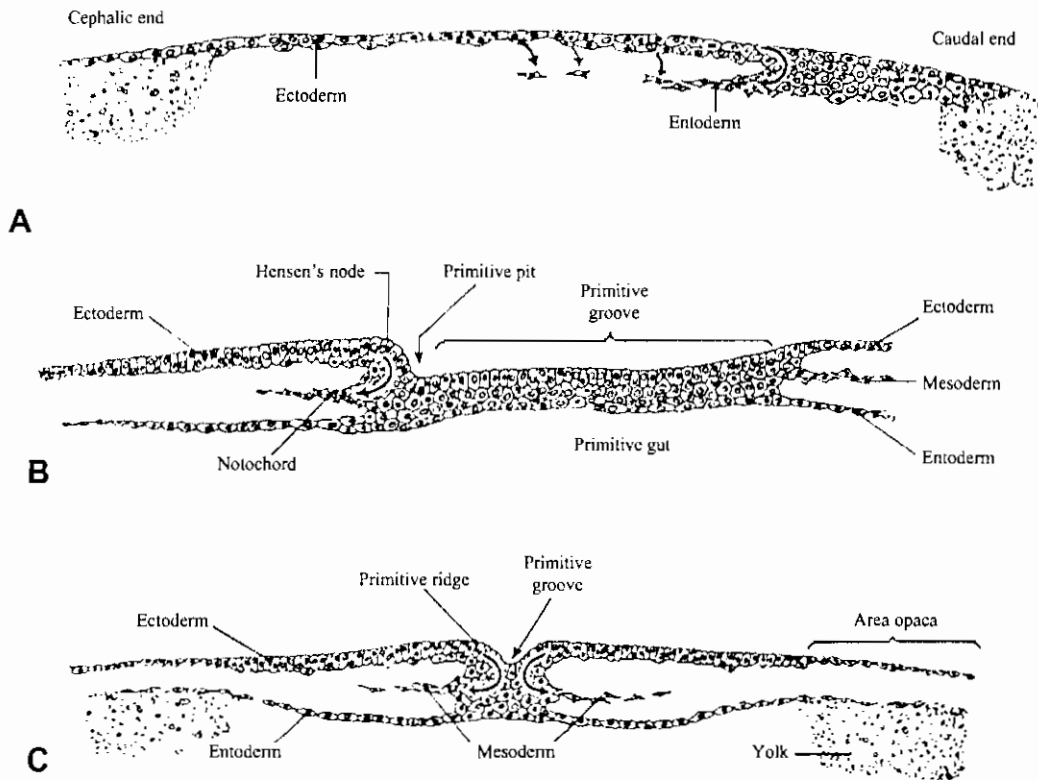
Anterior half of the area pellucida of a chick embryo cut transversely to show the migration of mesodermal and endodermal cells from the primitive streak. (From *An Introduction to Embryology*, 5th edition, by B. I. Balinsky, assisted by B. C. Babian. Copyright © 1981 by CBS College Publishing. Reprinted by permission of W. B. Saunders, a division of CBS College Publishing.)



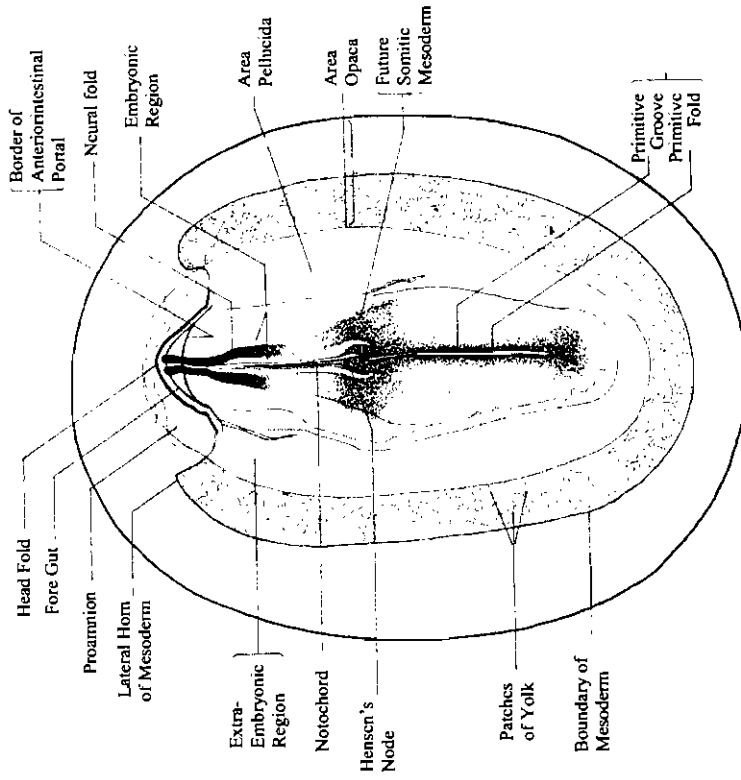
خريطة المصير لجنين الدجاجة في بداية مرحلة التبطين

Fate map of the chick embryo at the beginning of gastrulation. (Based on the experiments of G. C. Rosenquist and G. Nicolet.)n, notochord; hm, head mesenchyme. (From *An Introduction to Embryology*, fifth edition by B. I. Balinsky, assisted by B. C. Babian. Copyright © 1981 by CBS College Publishing. Reprinted by permission of W. B. Saunders, a division of CBS College Publishing.)

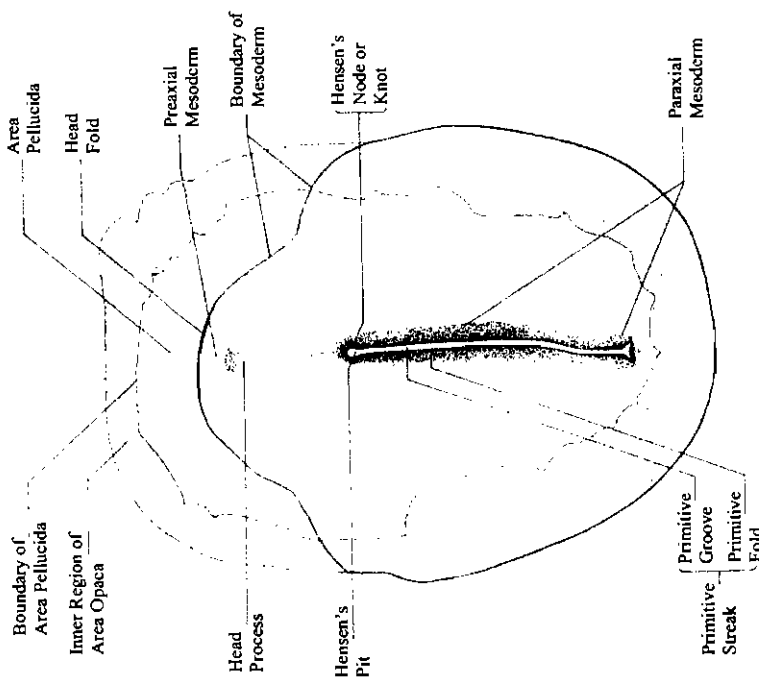
حركة الخلايا أثناء التبطين في جنين الكتكوت



Schematic diagrams indicating the cell movements involved in the gastrulation of chick embryos. (A) Longitudinal section of the blastoderm from a pre-primitive-streak chick during entoderm formation. (B) Longitudinal plan of embryo of approximately 17 hours of incubation to show the relations of the growing notochord, Hensen's node, and the primitive pit. (C) Cross section of embryo in the primitivestreak stage to show the turning in of cells at the primitive groove to enter the mesodermal layers.

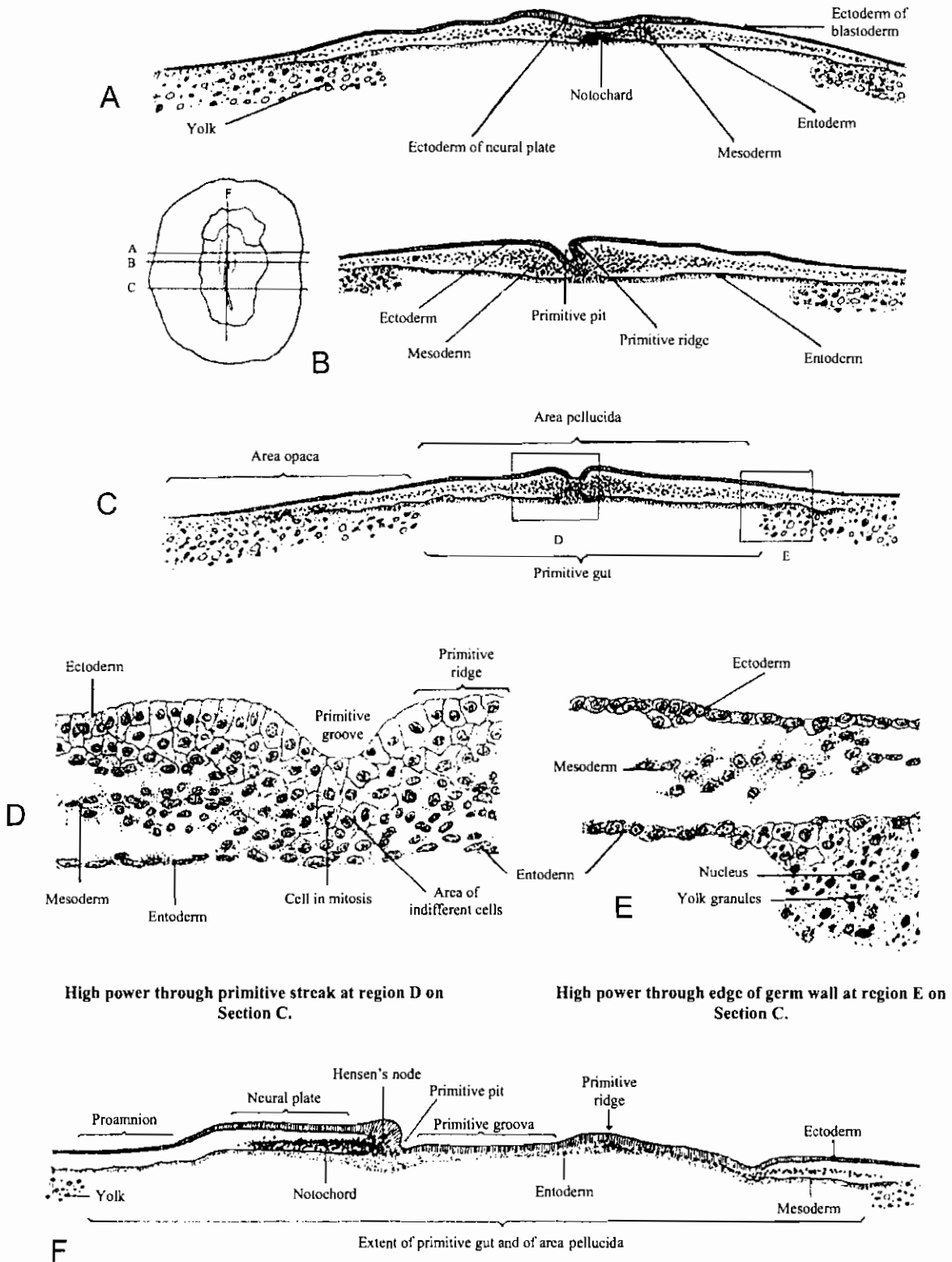


جين كتكوت في طور ثنية الرأس
Head fold stage chick embryo



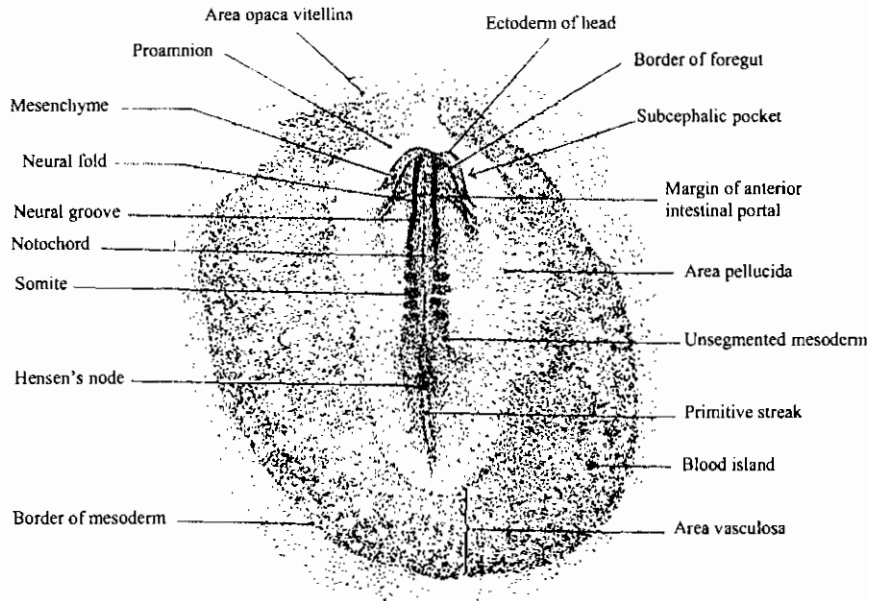
جين كتكوت في طور زائدة الرأس
Head process stage of chick embryo

قطاعات عرضية في جنين كنبوت في مرحلة الشق البدائي



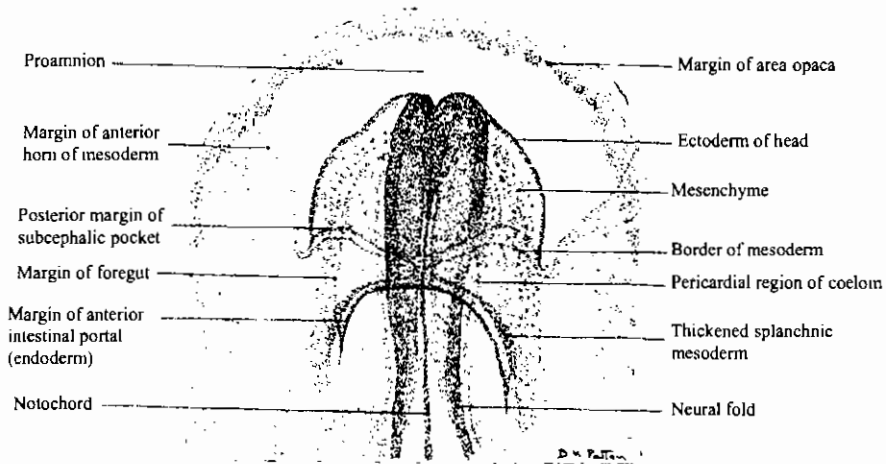
High power through primitive streak at region D on Section C.

High power through edge of germ wall at region E on Section C.



منظر ظهري لجنين ككتوت ذو أربعة قطع ميزودرمية (في عمر ٢٤ ساعة)

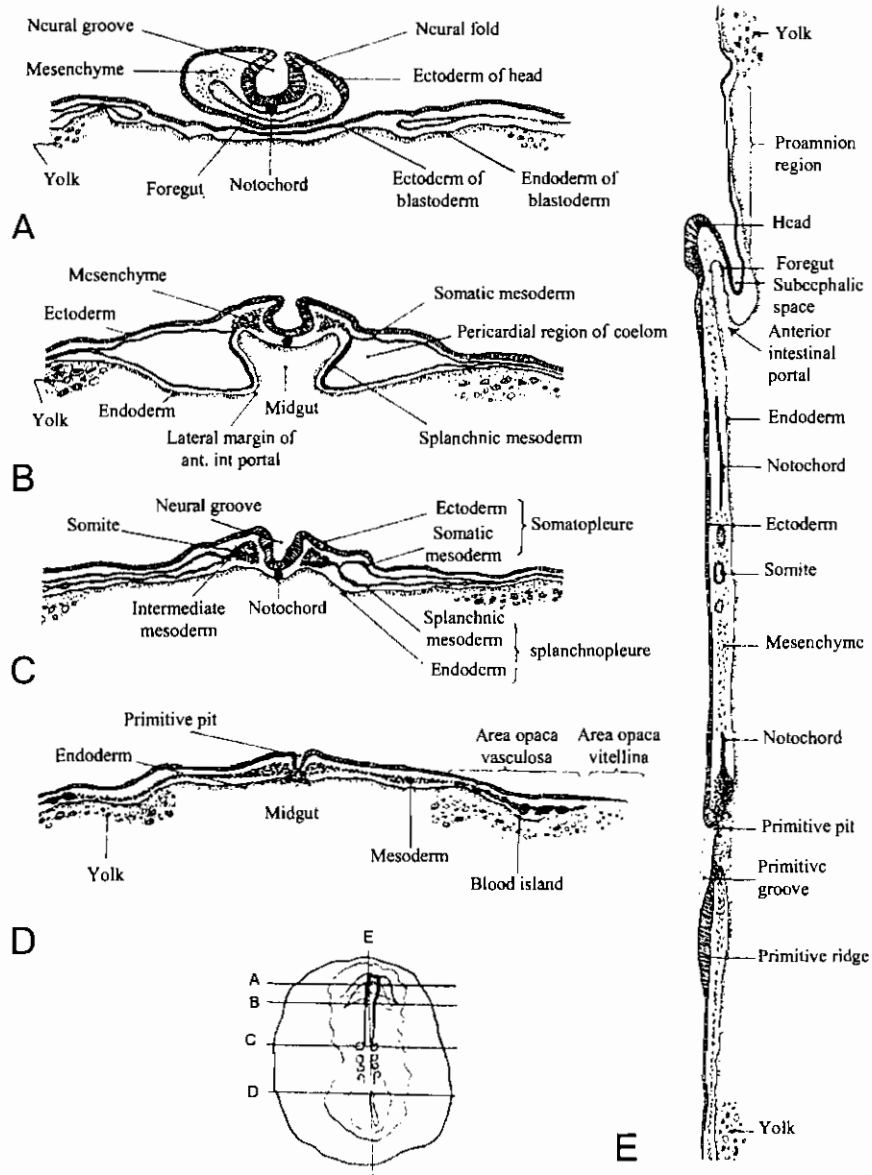
Dorsal view (X16) of entire chick embryo having four pairs of somites (about 24 hours' incubation).



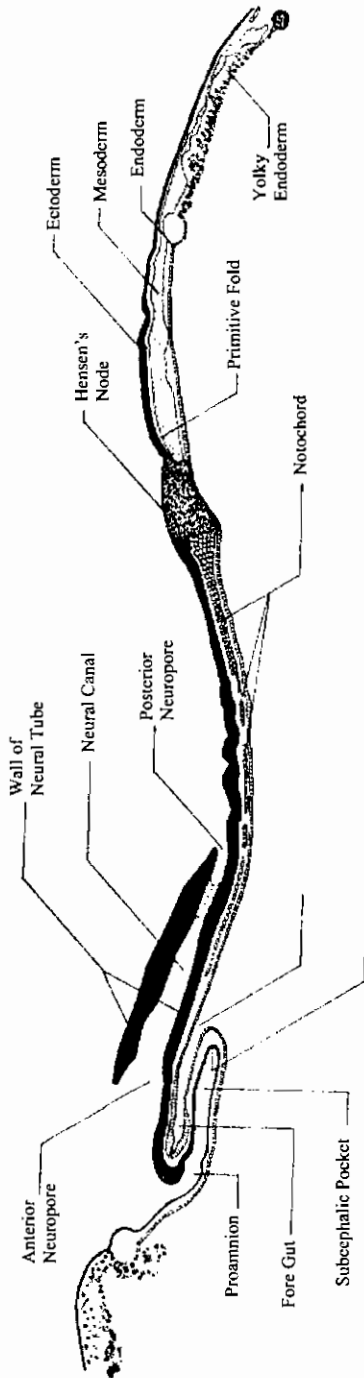
منظر بطني لمنطقة الرأس لجنين ككتوت ذو خمسة قطع ميزودرمية (نحو ٢٥ - ٢٦ ساعة)

Ventral view (X40) of cephalic region of chick embryo having five pairs of somites (about 25 to 26 hours of incubation).

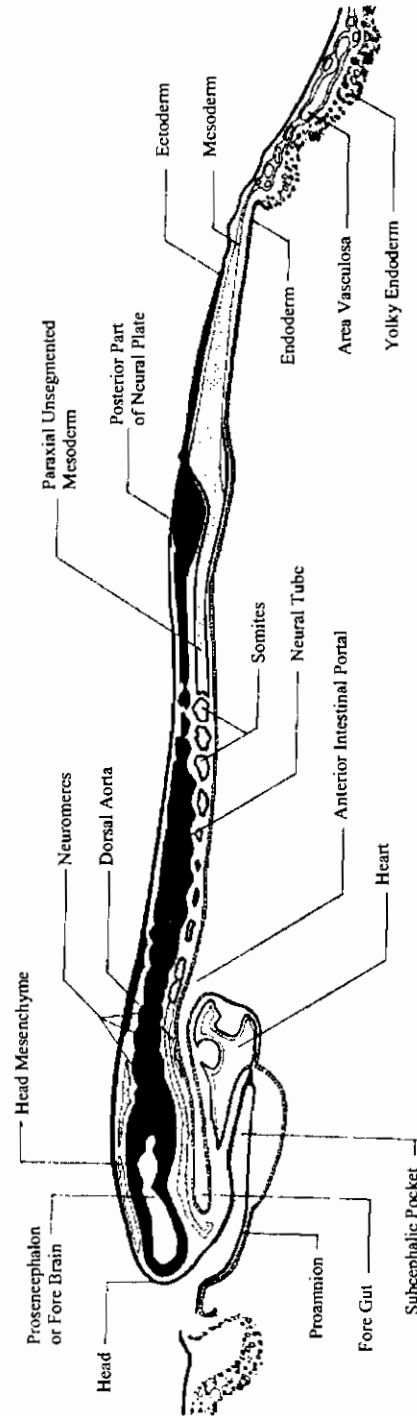
رسوم تخطيطية توضح مقاطعات في جنين كتكوت في عمر ٢٤ ساعة



Diagrams of sections of 24-hour chick. The sections are located on an outline sketch of the entire embryo. The conventional representation of the germ layers is the same as that employed in Fig. A-2 except that here, where its cells have become aggregated to form definite layers, the mesoderm is represented by solid black lines.

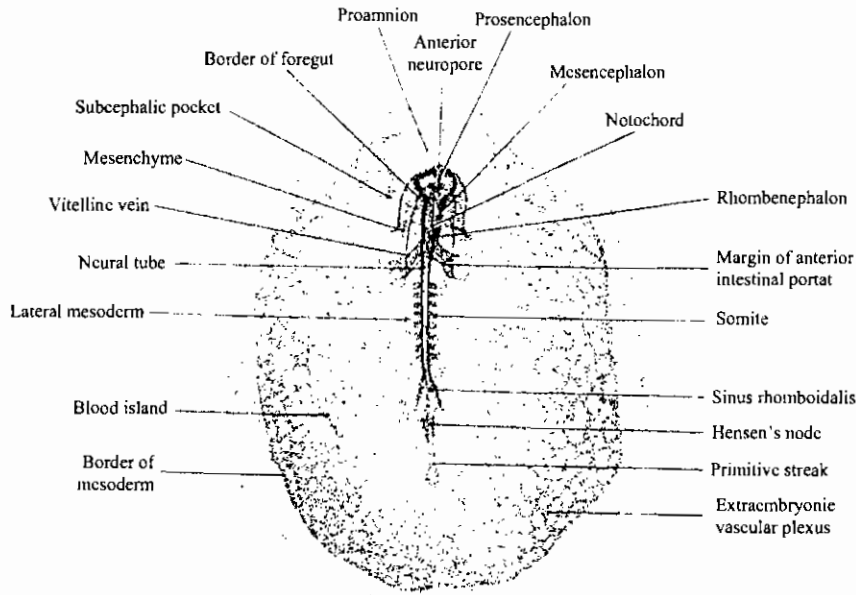


ق. ط. في جنين كيكوت ذو ستة قطع ميزودرمية (تكبير ٣٨)
L.s. of 6-somite stage chick embryo. X 38

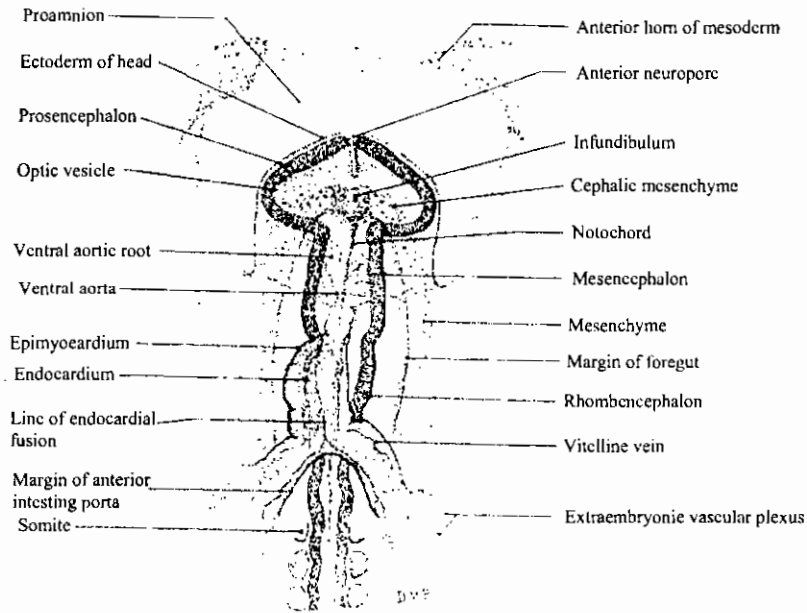


ق. ط. في جنين كيكوت ذو عشرة قطع ميزودرمية (تكبير ٢٨)
L.s. of 10-somite stage chick embryo. X 28

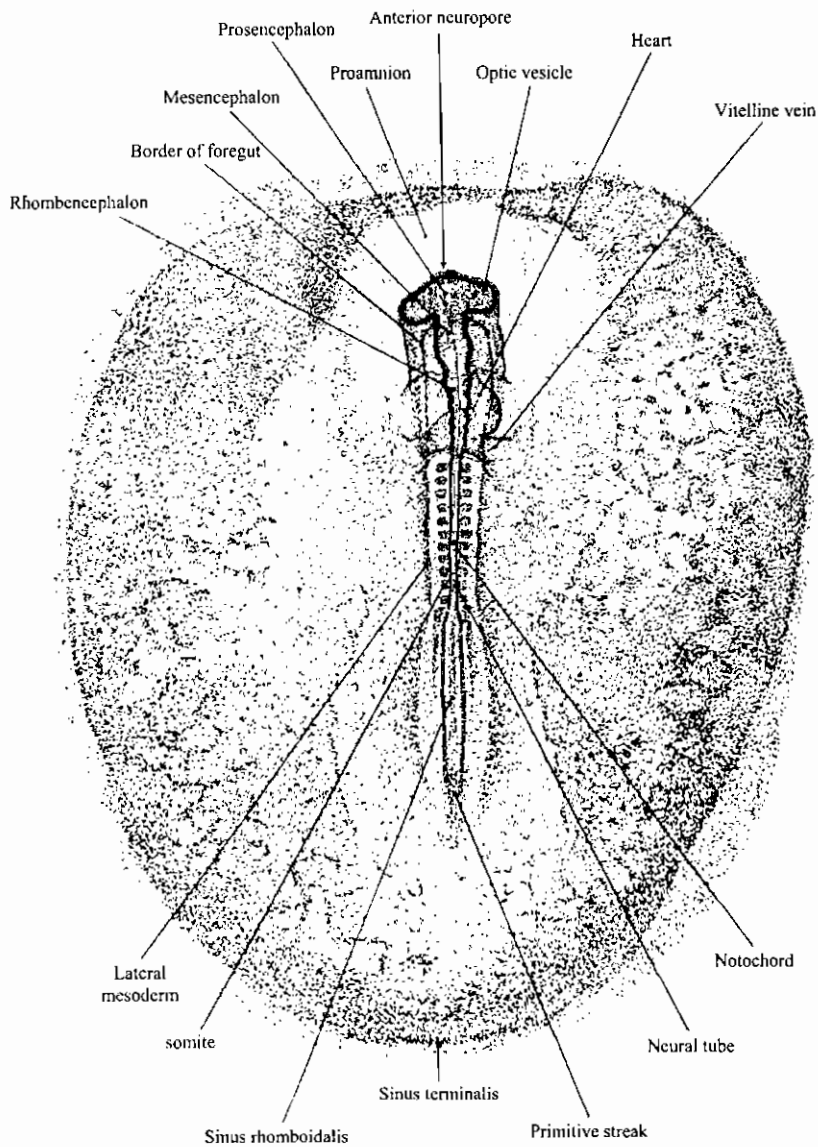
منظر ظهري لجنين ككتوت ذو ثمان قطع ميزودرمية (في عمر ٢٧-٢٨ ساعة)



Dorsal view (X 14) of the entire chick embryo having 8 pairs of somites (about 27 to 28 hours' incubation).

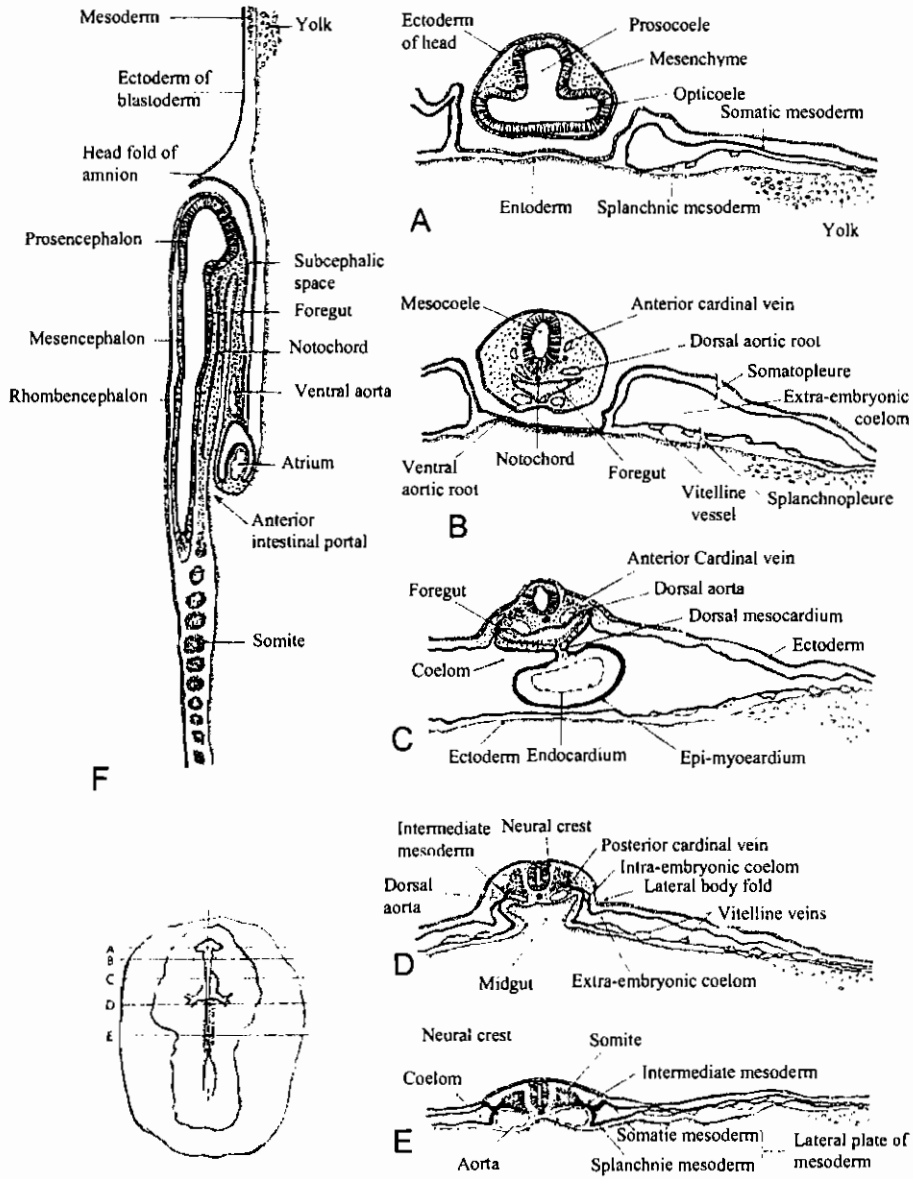


منظر بطني لمنطقة الرأس والقلب لجنين ككتوت ذو تسع قطع ميزودرمية (نحو ٢٩-٣٠ ساعة)
 Ventral view (X47) of cephalic and cardiac region of chick embryo of 9 somite
 (about 29 to 30 hours' incubation).



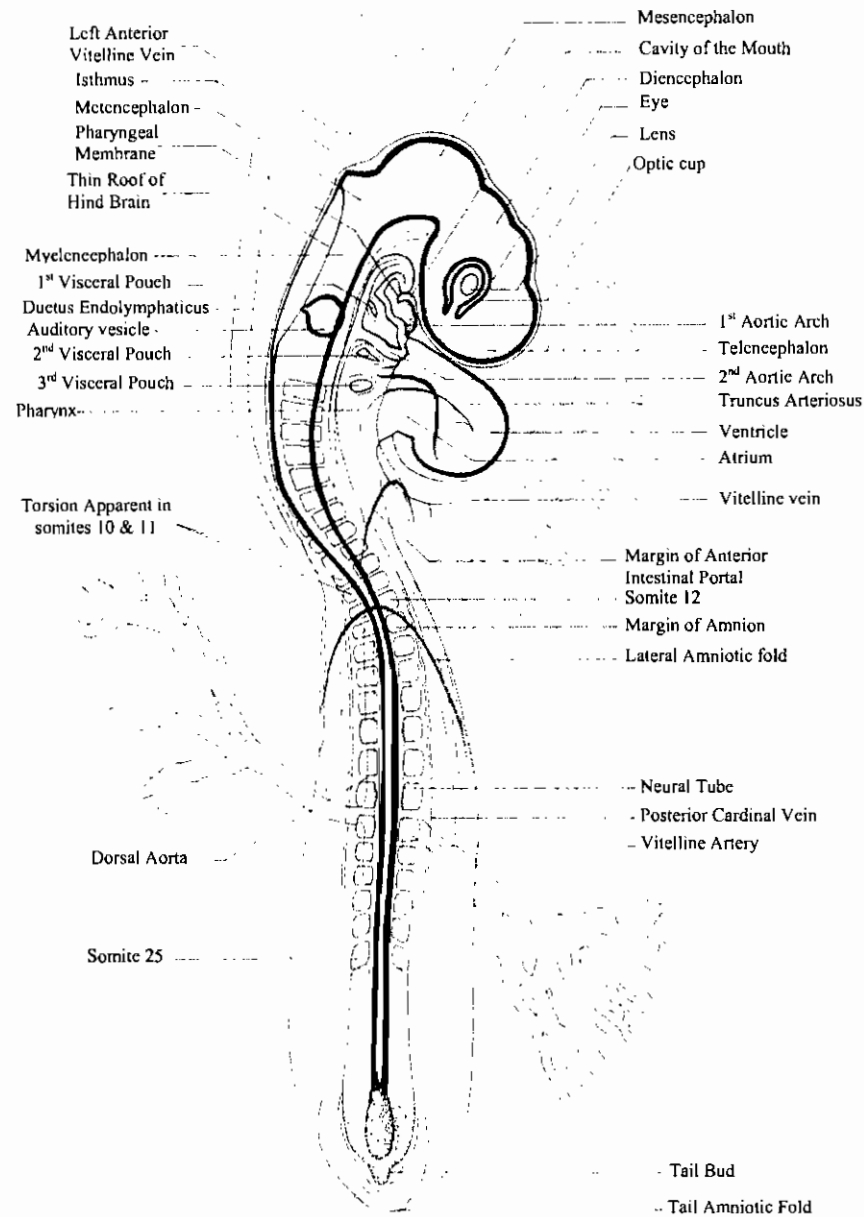
منظر ظهري لجنين كتكوت ذو ١٢ قطعة ميزودرمية (في عمر ٣٣ ساعة من الحضانة)

Dorsal view (X17) of an entire chick embryo of 12 somites (about 33 hours' incubation).



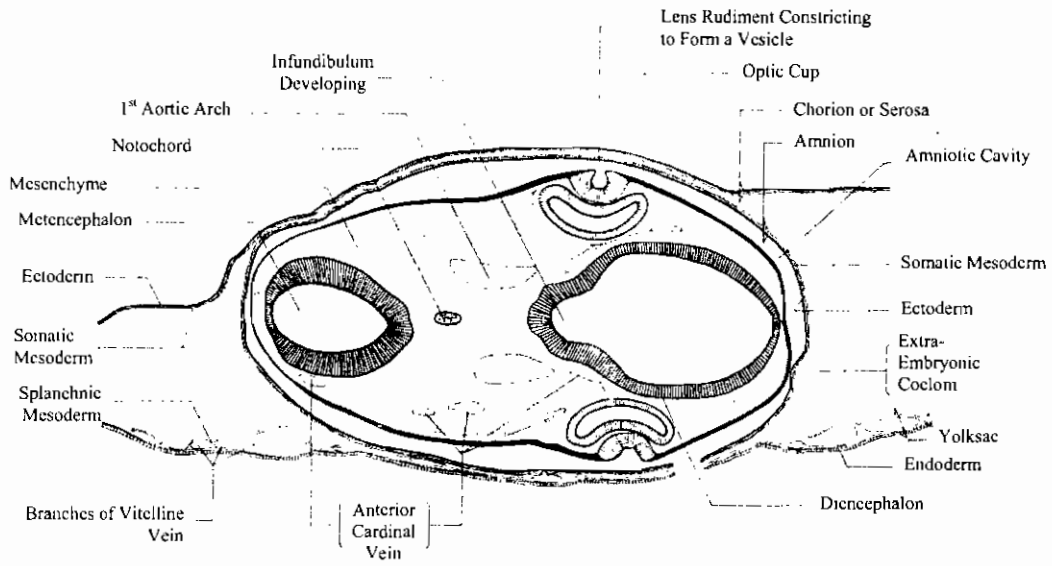
قطاعات ع. في جنين ككتوت في عمر ٢٣ ساعة في مناطق موضحة على الجانب

Diagrams of sections of 33-hour chick. The location of each section is indicated on a small outline sketch of the entire embryo.

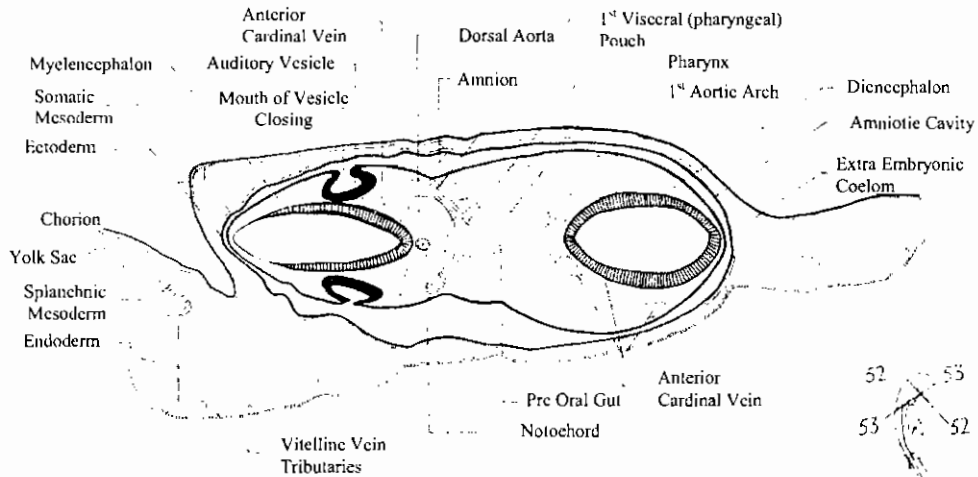


جنين كتكوت كامل في مرحلة ٢٤ قطعة ميزودرمية

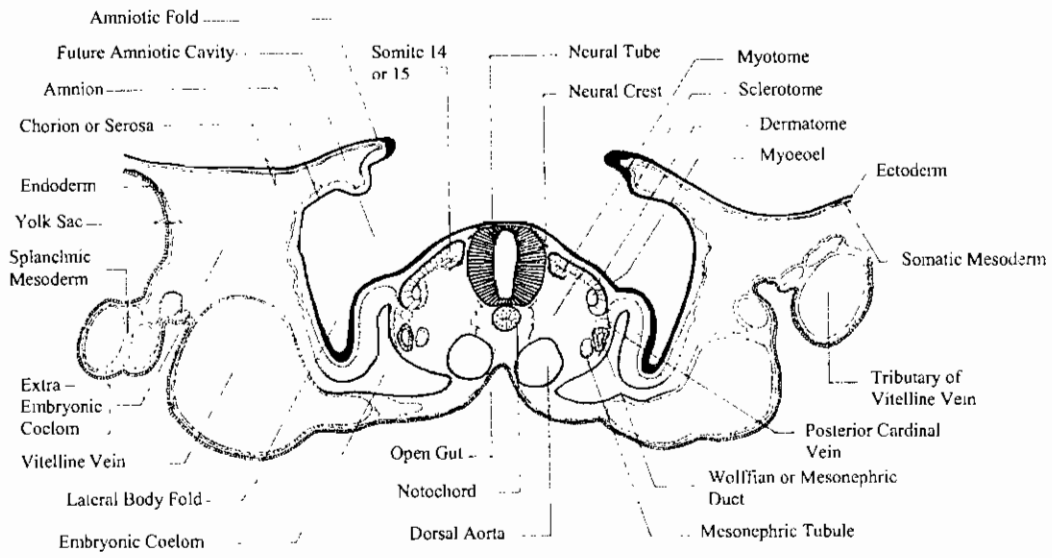
24-Somite stage whole chick embryo



ق. ع. في منطقة المخ الأمامي والخلفي لجنين ككتوت في مرحلة أربعة وعشرين قطعة ميزودرمية
 52-T. s. of the fore- and hind-brain region of 24-somite chick embryo

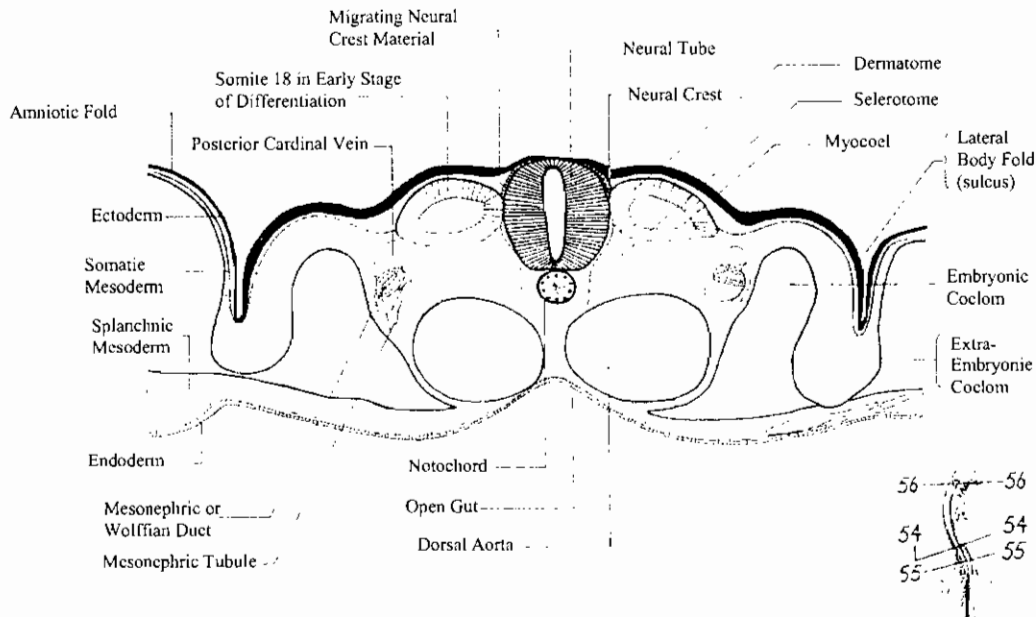


ق. ع. في منطقة المخ الأمامي والخلفي لجنين ككتوت في مرحلة أربعة وعشرين قطعة ميزودرمية
 53- T. s. of the fore – and hind-brain region of 24-somite chick embryo



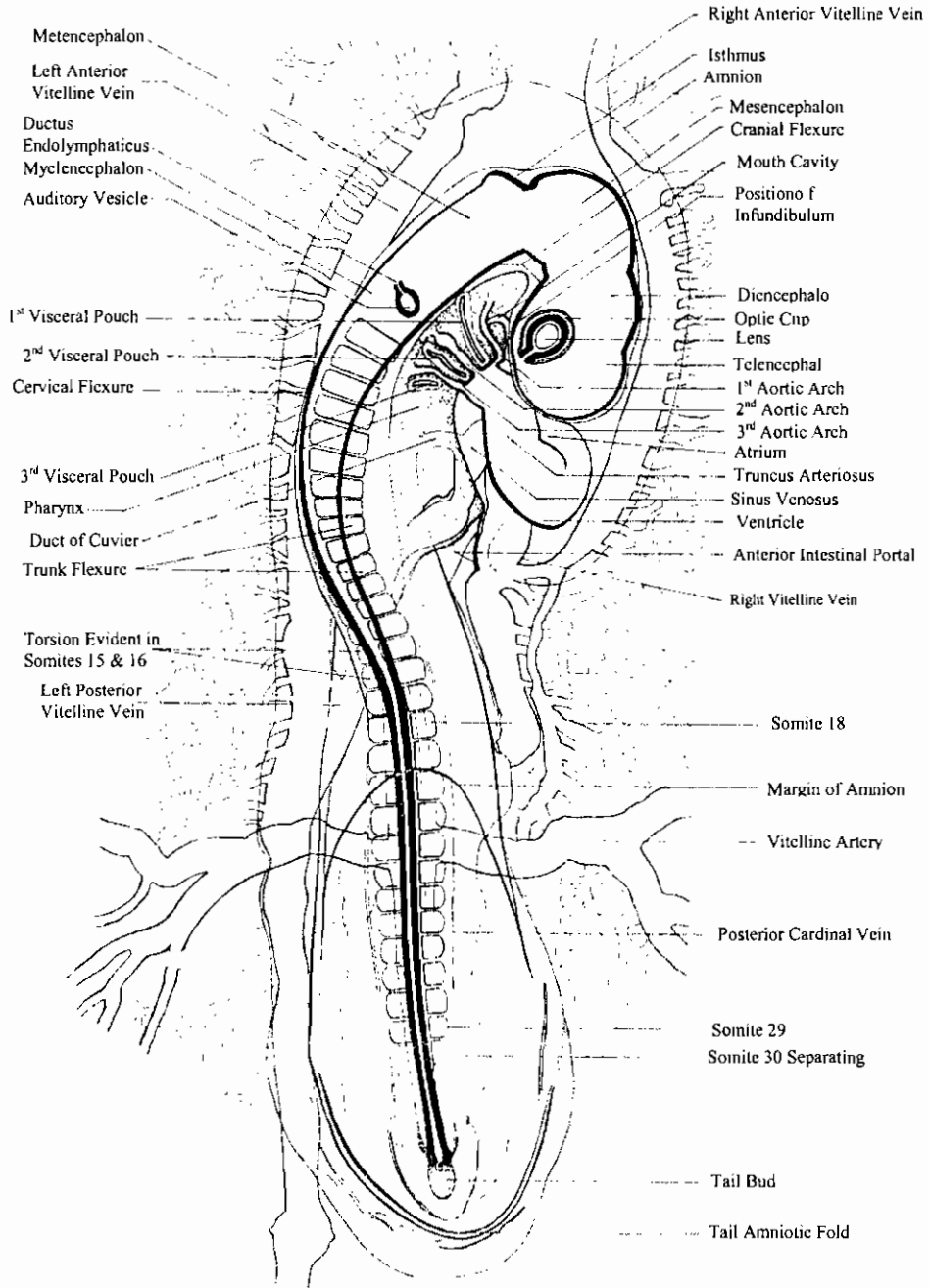
ق. ع. في منطقة الجزع لجنين كتكوت في مرحلة سبعة وعشرين قطعة ميزودرمية

54- T. s. of the trunk region of 27-somite stage chick embryo



ق. ع. في منطقة الجزع الخلفية لجنين كتكوت في مرحلة سبعة وعشرين قطعة ميزودرمية

55- T. s. of the posterior trunk region of 27-somite stage chick embryo



منظر سطحى لجنين كتكوت ذو ثلاثين قطعة ميزودرمية (فى عمر ٤٨ ساعة)

30- somite (48-hours) stage chick embryo